



## Review Article

# Lower urinary tract dysfunction in the central nervous system neurogenic bladder and the real-life treatment outcome of botulinum toxin A

Hann-Chorng Kuo\*

Department of Urology, Hualien  
Tzu Chi Hospital, Buddhist Tzu  
Chi Medical Foundation and Tzu  
Chi University, Hualien, Taiwan

### ABSTRACT

Neurogenic lower urinary tract dysfunction (NLUTD) is common in patients with central nervous system (CNS) lesions. Cases of cerebrovascular accidents (CVA), Parkinson's disease, dementia, and other intracranial lesions develop poor bladder control with or without urinary difficulty due to loss of cortical perception of bladder filling sensation and poor coordination of urethral sphincter relaxation during reflex micturition. Patients with CNS lesions usually have overactive bladder (OAB) symptoms, including urgency, frequency, incontinence, voiding symptoms of dysuria, large postvoid residual volume, and retention. In elderly patients with severe CNS disease the OAB symptoms are usually difficult to adequately relieve by medical treatment, and thus, their quality of life is greatly. Botulinum toxin A (BoNT-A) is currently licensed and has been applied in patients with idiopathic and neurogenic OAB due to spinal cord injury or multiple sclerosis. However, the application of BoNT-A in the treatment of urinary incontinence due to NLUTD in chronic CNS lesions has not been well-documented. Although cohort studies and case series support BoNT-A treatment for neurogenic OAB, chronic urine retention after intravesical BoNT-A injection for OAB and exacerbated urinary incontinence after urethral BoNT-A injection for voiding dysfunction have greatly limited its application among patients with NLUTD due to CNS lesions. This article reviews the pathophysiology and clinical characteristics of NLUTD in patients with CNS lesions and the clinical effects and adverse events of BoNT-A injection for patients with NLUTD. A flowchart was created to outline the patient selection and treatment strategy for neurogenic OAB.

**KEYWORDS:** *Botulinum toxin A, Dysfunctional voiding, Lower urinary tract dysfunction, Neurogenic bladder, Overactive bladder*

**Submission** : 07-Feb-2024  
**Revision** : 04-Mar-2024  
**Acceptance** : 25-Mar-2024  
**Web Publication** : 24-May-2024

## INTRODUCTION

Neurogenic lower urinary tract dysfunction (NLUTD) is commonly encountered in patients with neurological lesions affecting the central nervous system (CNS) to the peripheral nerves. Lower urinary tract symptoms (LUTS) such as urgency, urgency urinary incontinence (UUI), dysuria, or urinary retention are common symptoms of patients with cerebrovascular disease (CVA), Parkinson's disease (PD), dementia, and multiple sclerosis. The patterns of storage or voiding LUTS depend on the level of neurologic lesions [1,2]. In patients with CNS diseases, inadequate cortical perception of lower urinary tract sensation and control are associated with poor activation of urination, lack of bladder fullness sensation, urinary incontinence, and incomplete bladder emptying [1]. Thus, overactive bladder (OAB) symptoms can present as a prodromal symptom of neurological diseases in patients with CNS lesions [2]. The findings of urodynamic studies in patients

with CNS-related NLUTD typically include (1) terminal uninhibited detrusor overactivity (DO), (2) inadequate detrusor contractility, and (3) dyscoordination of the urethral sphincter during voiding. These patients might be mistakenly diagnosed as having bladder outlet obstruction (BOO); however, bladder outlet surgery might exacerbate the OAB symptoms if there is no existence of BOO [3]. Not only patients will suffer from intractable urinary incontinence or persistent difficult urination, the economic burden of health care for patients with CNS disease will also increase.

CNS diseases usually occur in elderly patients since detrusor function declines and contractile strength reduces

**\*Address for correspondence:** Dr. Hann-Chorng Kuo,  
Department of Urology, Hualien Tzu Chi Hospital, Buddhist Tzu Chi  
Medical Foundation, 707, Section 3, Chung-Yang Road, Hualien, Taiwan.  
E-mail: hck@tzuchi.com.tw

This is an open access journal, and articles are distributed under the terms of the Creative Commons Attribution-NonCommercial-ShareAlike 4.0 License, which allows others to remix, tweak, and build upon the work non-commercially, as long as appropriate credit is given and the new creations are licensed under the identical terms.

**For reprints contact:** WKHLRPMedknow\_reprints@wolterskluwer.com

**How to cite this article:** Kuo HC. Lower urinary tract dysfunction in the central nervous system neurogenic bladder and the real-life treatment outcome of botulinum toxin A. Tzu Chi Med J 2024;36(3):260-70.

### Access this article online

#### Quick Response Code:



**Website:** www.tcmjmed.com

**DOI:** 10.4103/tcmj.tcmj\_29\_24

with aging; the bladder emptying efficiency is usually impaired with in elderly patients with CNS disease [4]. In line with this, detrusor hyperactivity and inadequate contractility (DHIC) are commonly observed in the elderly [5]. Among older patients with urgency incontinence and reduced bladder sensation, reduced frontal lobe perfusion is noted on brain images [6]. Cognitive impairment and urinary incontinence have also been associated with mental failure in older adults [7]. Brain damage in older adults may cause cognitive impairment, dysphasia, inappropriate and aggressive behavior, impaired mobility, and low motivation, and treatment with anticholinergics may even worsen these problems [8]. LUTD is commonly occurred in patients with CNS diseases, and the bladder storage and voiding dysfunctions varied widely in patients with different diseases, different levels, and different severity of neurological lesions [2]. For instance, urinary incontinence with impaired awareness of bladder fullness and urgency indicates cortical functional impairment after stroke [9].

### NEUROGENIC LOWER URINARY TRACT DYSFUNCTION IN PATIENTS WITH CEREBRAL VASCULAR ACCIDENT

CVA is the most common neurological disease in the CNS, and it is usually accompanied by LUTS in the first 3 months after the episode, presenting with storage symptoms (i.e., frequency and urgency) with or without urge incontinence. In fact, urinary incontinence was present in 43.5% and 37.7% of patients at 3 and 12 months after the episode, respectively, with urge incontinence being the most common symptom [10]. The severity of urinary incontinence depends on the severity of the stroke and the patient age. The most common urodynamic finding in CVA is DO and a coordinated urethral sphincter [Figure 1a]. DO was seen in lesions of the frontal lobe and basal ganglia. Patients with frontal lobe lesions usually have DO and uninhibited relaxation of the urethral sphincter, resulting in the lower urinary tract dysfunction similar to detrusor sphincter dyssynergia (DSD), which is also commonly occurred in patients with basal ganglia lesions [11]. Voiding dysfunction is usually attributed to damage to the anteromedial frontal lobe, descending pathway, and basal ganglia.

The incidence of LUTD in patients with stroke and brain tumors ranges from 14% to 53%, mostly manifesting as OAB, with a higher incidence among those with frontal cortex involvement [12]. Patients with CVA usually have an intact sensation of bladder fullness and urgency but with urgency frequency on urodynamic DO. New-onset poststroke urinary incontinence with impaired awareness of bladder urge sensation is also a strong and independent risk factor for poor outcome at 3 months after stroke [13]. In elderly patients with multiple CVAs or lacunar infarctions, DHIC can be another bladder problem, resulting in urgency, incontinence, and a large postvoid residual (PVR) volume.

Voiding dysfunction has been reported in 20%–50% of patients with frontal brain lesions from tumors and CVAs [12]. Lesions in the basal ganglia or thalamus usually have normal sphincter function [14]. Incomplete bladder emptying in stroke

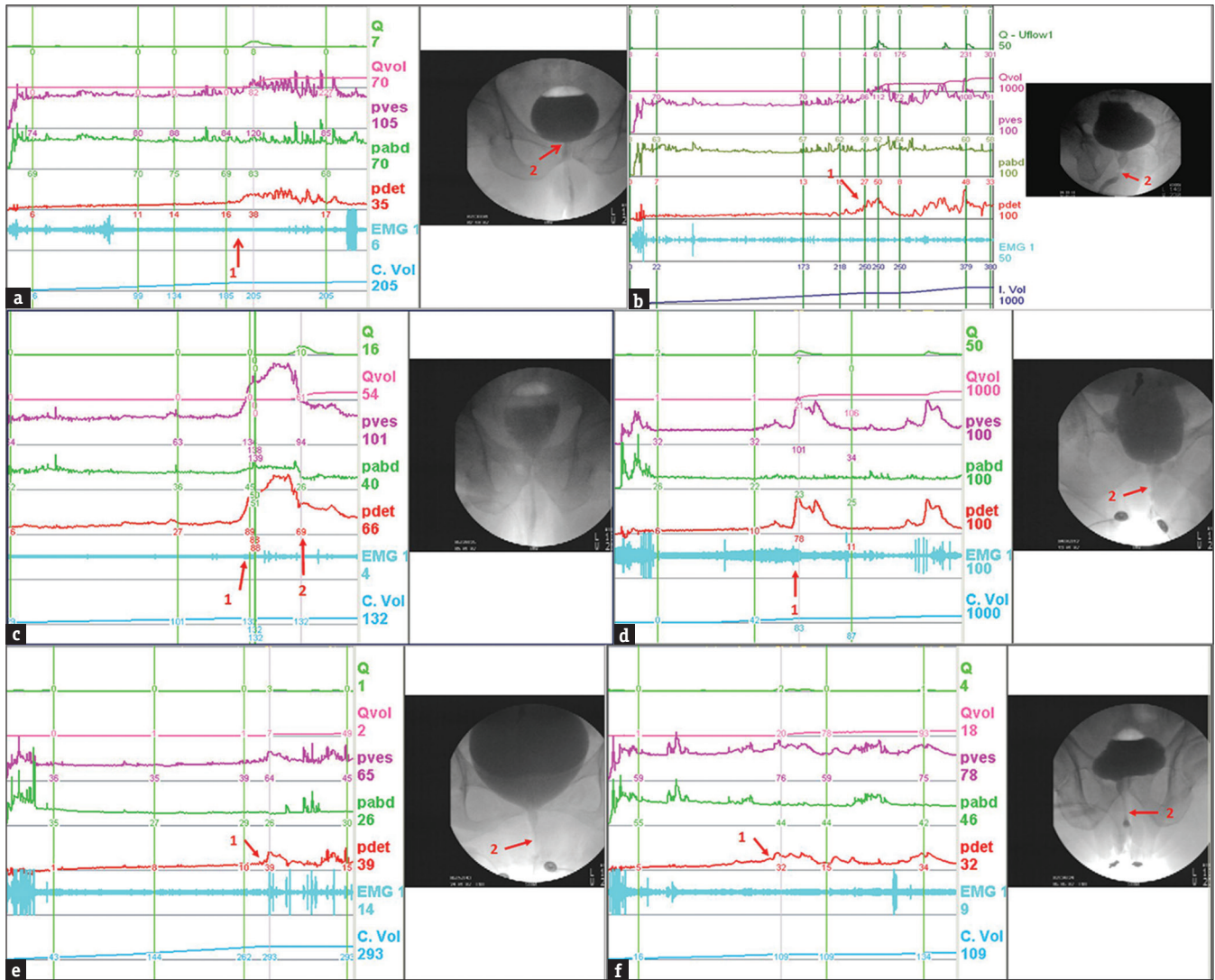
patients is sometimes associated with detrusor underactivity (DU) and urethral sphincter pseudodyssynergia [15]. The urethral sphincter pseudodyssynergia is characterized by voluntary contractions of the urethral sphincter during involuntary detrusor contractions [Figure 1b], and this develops in approximately 10% of patients recovering from a CVA episode. Urethral sphincter injection of Botulinum toxin A (BoNT-A) is safe and effective for treating patients with CVA and urethral sphincter pseudodyssynergia [16].

In patients with CVA caused by intracranial hemorrhage, the increased external sphincter activity is prolonged and detrusor contractions are inhibited. After the urethral sphincter is relaxed, urination is initiated with adequate detrusor contractility. Patients may have LUTS of hesitancy, difficult urination, a slow stream, and a large PVR volume [Figure 1c].

### NEUROGENIC LOWER URINARY TRACT DYSFUNCTION IN PATIENTS WITH PARKINSON'S DISEASE AND MULTIPLE SYSTEM STROPHY

PD is the second most common neurodegenerative disease after Alzheimer's disease. Many patients with PD present with LUTD, manifesting as urgency, increased frequency, and incontinence [17]. LUTS are common in PD, seen in 27%–85%. Irritative bladder symptoms predominate, and an urodynamic study confirms the high prevalence of DO in PD [18]. During voiding, the intermittent contractions of the urethral sphincter will result in the inhibition of detrusor contractions and cause a considerable PVR volume increase in patients with PD [Figure 1d]. This discoordinated LUTD, or so-called urethral sphincter pseudodyssynergia, is a condition that may occur at the start or in the middle of urination in patients with CNS lesion without spinal cord injury. A previous urodynamic study and neurophysiological evaluation in patients with PD and multiple system atrophy (MSA) revealed a normal urodynamic tracing in 36.6% of patients, delayed or incomplete pelvic floor relaxation in 26.7%, DO with dysfunction voiding (DV) in 26.7%, and DO with incomplete pelvic floor relaxation in 10% [19]. PD patients with a normal urodynamic pattern had significantly less severe disease. Sphincter electromyography (EMG) analysis showed that the PD patients had a normal sphincter EMG, whereas 24 out of 32 patients with MSA had neurogenic signs.

Bladder dysfunction (e.g., urinary urgency and frequency) and bowel dysfunction (e.g., constipation) are common nonmotor disorders in PD [20]. Particularly, bladder symptoms occur at an advanced stage of PD, usually after many years of treatment [21]. Some common findings include a urodynamic DO and sporadic involuntary external sphincter EMG activity, seen in 90% and 61% of patients, respectively. Meanwhile, coordinated striated sphincter relaxation and definite prostatic obstruction were seen in 45% and 18% of patients, respectively [22]. Impaired relaxation of the urethral sphincter (bradykinesia) may also cause outflow obstruction in PD [23]. Voiding dysfunction also occurs in 35%–70% of patients with PD, manifesting as urgency, frequency, nocturia, and urge incontinence with or without obstruction.



**Figure 1:** Video urodynamic study of patients with central nervous system lesion. (a) Urgency urinary incontinence in a patient with cerebrovascular accident (CVA). Involuntary detrusor contraction occurs at bladder capacity with coordinated urethral sphincter relaxation (arrow 1). A tight bladder neck and low detrusor contractility cause incomplete bladder emptying (arrow 2). (b) Pseudodyssynergia in a patient with CVA, urinary incontinence and difficult urination. Uninhibited detrusor contraction occurs with increased urethral sphincter activity during urination (arrow). (c) Uninhibited detrusor contraction occurs at the bladder capacity (arrow 1) in a CVA patient. The urethral sphincter does not relax adequately (arrow 2), resulting in incomplete bladder emptying. (d) A patient with Parkinson's disease. Uninhibited detrusor contraction occurs at the bladder capacity (arrow 1), and the urethral sphincter contracts concomitantly, resulting in pseudodyssynergia (arrow 2) and incomplete voiding. (e) A patient with Parkinson's disease. Uninhibited detrusor contraction occurs when the bladder capacity is reached (arrow 1), and pelvic floor guarding is noted (arrow 2). (f) Urinary incontinence in a patient with dementia. The patient does not sense bladder filling or urgency until urination starts when the bladder capacity is reached (arrow 1). No bladder outlet obstruction was noted (arrow 2)

MSA is an intractable neurodegenerative disorder with a progressive and poor prognosis [24], characterized by simultaneous extrapyramidal, cerebellar, pyramidal, and autonomic involvement. The neurologic lesions consist of cell loss and gliosis in widespread areas, and its bladder symptoms occur earlier than in PD [25]. Approximately 60% of patients with MSA have urinary symptoms (i.e., urgency frequency and urge incontinence) preceding symptoms of parkinsonism. Most also have a significantly large PVR volume or urinary retention due to impaired detrusor contractility [26]. Thus, MSA should be a differential diagnosis among patients with severe urinary symptoms but with mild parkinsonism.

DO in patients with CNS lesions such as MSA is due to cell loss in the brainstem region, and incomplete emptying is due

to the loss of parasympathetic drive following cell atrophy of the intermediolateral cell columns [25]. Anterior horn cell loss in Onuf's nucleus results in urethral sphincter denervation. In particular, urinary and erectile dysfunction are prominent early features in male MSA patients. More than 50% of MSA patients suffer from recurrent urinary tract infection (UTI), and 25% succumb to its complications [27]. In short, signs of voiding dysfunction may be early neurological manifestations of MSA.

### NEUROGENIC LOWER URINARY TRACT DYSFUNCTION IN DEMENTIA AND OTHER INTRACRANIAL LESIONS

Dementia is a complex CNS disease involving atrophy and loss of gray and white matter. Dementia includes a wide



variety of widespread vascular diseases, such as Alzheimer's disease, Pick's disease, Jacob–Creutzfeldt disease, syphilis, head trauma, and encephalitis. Urinary incontinence is common in patients with dementia because patients lose awareness regarding the desirability of voluntary urinary control [Figure 1e]. Urodynamic studies usually reveal terminal DO when the bladder capacity is reached. Patients may have urgent urinary incontinence and incomplete bladder emptying due to a lack of bladder sensation of urinary fullness [Figure 1f].

In elderly male patients with dementia and benign prostatic hyperplasia (BPH), the large PVR volume and failure of treatment may be mistakenly treated as anatomical BOO. However, treatment for BPH is usually ineffective in patients with dementia, especially in the absence of a urodynamic study of BOO [3]. Therefore, surgical intervention for BPH is contraindicated in patients without definite evidence of BOO.

Other intracranial lesions, such as traumatic brain trauma, brain tumors, and intracranial hemorrhage, initially present with detrusor areflexia, followed by involuntary detrusor contractions in those with lesions above the pontine micturition center. A portion of patients with CNS lesions at the frontal lobe might have voiding dysfunction and impaired early bladder sensation of filling but become aware when the detrusor contracts at the bladder capacity [28]. These patients may have DO, diminished bladder sensation of filling, failure to suppress micturition reflex, which result in mixed LUTS, such as UI, difficult urination, large PVR, or urinary retention. The presence of different LUTS depends on the location of CNS lesions and the severity of brain damage [29]. These mixed LUTDs further make pharmacological management fail to adequately improve their LUTS.

Cerebellar ataxia is caused by pathologic degeneration of the nervous system involving the cerebellum, with possible extension to the brain stem, spinal cord, and dorsal nerve root [30]. In these cases, urinary incontinence is associated with DO and urethral sphincter synergy, and detrusor areflexia causes urinary retention. One study reported that 15.8% of patients had stress urinary incontinence, possibly due to spinal cord lesions affecting Onuf's nucleus and pudendal nerve dysfunction [31]. The prevalence of self-reported LUTS in patients with cerebellar ataxia is reported to be 60.8%, with the most common symptoms being urinary frequency and urgency [32].

Cerebral palsy (CP) is a nonprogressive brain injury caused by infection or hypoxia. Most patients with CP have normal urinary control in lesions above the brainstem (i.e. DO with sphincter synergy). Patients with CP and voiding dysfunction usually report urinary incontinence (74%), frequency (56%), and urgency (37%), while urodynamic studies revealed DO in 87% [33]. Difficult urination in CP is caused by poor relaxation of the PFM, rather than a true striated urethral sphincter DSD [34]. However, spinal cord damage may occur, and this is responsible for true DSD and upper urinary tract deterioration. Storage symptoms are more common because of the high prevalence of DO. In addition, CP patients with

voiding symptoms and pelvic floor overactivity are more prone to develop upper urinary tract dysfunction in adulthood [35]. Severe hydronephrosis occasionally occurs because of prolonged bladder overdistention and obstructive uropathy.

## VIDEOURODYNAMIC FINDINGS IN PATIENTS WITH DIFFERENT SUBTYPES OF CHRONIC BRAIN LESIONS

Patients with different subtypes of chronic brain lesions have a high incidence of storage LUTD such as OAB and urinary incontinence. The reported incidence of neurogenic detrusor overactivity (NDO) and urinary incontinence varied widely depending on the study cohorts of different stages of brain lesion, and sites of brain lesion. The reported incidence of urinary incontinence due to NDO was 33%–79% in patients with CVA, 33.1% in patients with PD, and 40% in dementia patients with white matter disease [36–38]. In fact, clinical symptoms in patients with chronic brain lesions might not accurately reflect the real lower urinary tract conditions. Patients with overflow incontinence could be due to NDO or functional urinary incontinence in patients with cognitive dysfunction and immobilization. In addition, most patients with CNS lesions also have voiding dysfunctions due to bladder or bladder outlet dysfunctions. Video urodynamic study (VUDS) could identify DU with or without NDO in patients with CNS lesions, and BOO at the bladder neck, prostatic urethra, dyssynergic–external sphincter, or a non-relaxing urethral sphincter [39–41]. Before a urological pharmacological treatment or surgical intervention for patients with complex clinical symptoms, large PVR, and recurrent UTI, VUDS combined image and pressure flow studies are indicated for precision diagnosis and treatment [42].

We have analyzed our VUDS results in a cohort of patients with CNS lesions, including CVA, PD, and dementia. The common VUDS findings in patients with CNS lesions include bladder dysfunction (DO, DU, and mixed DO and DU) and functional BOO (BN dysfunction and urethral sphincter dyscoordination) [42]. Among the patients, 83.4% of them had DO or DU, whereas 60.9% of them had bladder outlet dysfunction during the voiding phase. In our previous study, the VUDS findings of the patients with chronic CNS lesions show a high prevalence of NDO causing urinary incontinence and a high rate of DU or functional BOO resulting in difficult urination and large PVR [Table 1]. Therefore, for patients with CNS lesions and LUTS, a precise VUDS will facilitate assessing NLUTD and selecting appropriate medications. The VUDS characteristics vary and will influence the appropriate pharmacological, minimally invasive, or surgical management of NLUTD in patients with CNS lesions.

## PHARMACOLOGICAL THERAPY FOR NEUROGENIC OVERACTIVE BLADDER

Medical treatment is not always satisfactory for neurogenic OAB associated with CNS diseases. Patients with CNS lesions (e.g. CVA) who cannot perceive bladder sensation of filling and urgency usually have multiple or a severe cortical dysfunction [9]. Pharmacological

**Table 1: The videourodynamic study in patients with cerebrovascular accident, Parkinson's disease, and dementia [42]**

NLUTD	Diagnosis on VUDS	All patients (n=169), n (%)	CVA (n=84), n (%)	PD (n=55), n (%)	Dementia (n=30), n (%)
Bladder condition	Stable bladder	28 (16.6)	13 (15.5)	12 (21.8)	4 (13.3)
	DO	124 (73.4)	64 (76.2)	39 (70.9)	21 (70.0)
	Phasic	51 (30.2)	22 (26.2)	23 (41.8)	6 (20.0)
	Terminal	109 (64.5)	60 (71.4)	31 (56.4)	18 (60.0)
	Provoke	4 (2.4)	3 (3.6)	1 (1.8)	0
Bladder outlet condition <sup>#</sup>	DO-DU (DHIC)	28 (16.6)	16 (19.0)	7 (12.7)	5 (16.7)
	DU	17 (10.1)	7 (8.3)	4 (7.3)	6 (20.0)
	No definite BOO	66 (39.1)	35 (41.7)	18 (32.7)	13 (43.3)
	BPO (% of male)	10 (10.1)	7 (12.7)	2 (6.1)	1 (10)
	Bladder neck	36 (21.3)	21 (25)	7 (12.7)	8 (26.7)
	Urethral sphincter	71 (42)	27 (32.1)	33 (60)	11 (36.7)
	Dyssynergia	48 (28.4)	18 (21.4)	24 (43.6)	7 (23.3)
	Nonrelaxing ES	22 (13.0)	9 (10.7)	9 (16.4)	4 (13.3)

<sup>#</sup>Some cases have multiple sites of BOO. CVA: Cerebrovascular accident, PD: Parkinson's disease, DO: Detrusor overactivity, DU: Detrusor underactivity, DHIC: Detrusor hyperactivity and inadequate contractility, BPO: Benign prostatic obstruction, ES: External sphincter, BOO: Bladder outlet obstruction, NLUTD: Neurogenic lower urinary tract dysfunction, VUDS: Video urodynamic study, DU: Detrusor underactivity

therapy targeting at inhibit DO might not be adequate to improve urinary incontinence. Therefore, a combination of pharmacologic and nonpharmacologic approaches, such as a combination of antimuscarinic agents with clean intermittent catheterization (CIC), might provide a better treatment outcome through different therapeutic targets [43]. Regarding the adverse events of antimuscarinics in patients with neurogenic OAB due to CNS lesions, the use of mirabegron might provide less cognitive impairment than antimuscarinics; however, the therapeutic efficacy of mirabegron in inhibiting DO at the bladder capacity and urinary incontinence should also be considered [44].

In the treatment of CNS-related LUTD, patients with OAB are usually given antimuscarinic agents (e.g., tolterodine, oxybutynin, and propiverine), mirabegron (beta-3 adrenoceptor agonist), or a combination of the two classes of drugs [45]. For nocturia and nocturnal polyuria, desmopressin is feasible, but adverse events such as hyponatremia should be considered [46]. In treatment of voiding dysfunction due to bladder neck dysfunction or urethral sphincter dyscoordination, combined alpha-blockers and baclofen can be prescribed to achieve a better outcome [47,48]. Notably, the adverse events should be carefully monitored, especially in elderly patients with CNS lesions; the adverse events include dizziness and hypotension after administering alpha-blockers and systemic weakness after baclofen usage.

Antimuscarinic treatment for OAB generally has a high success rate. However, there are concerns regarding impaired bladder emptying and cognitive dysfunction during treatment with nonselective antimuscarinic agents for OAB [49]. Although short-term anticholinergic treatment in elderly patients with OAB did not show substantial cognitive impairment, large observational studies have shown a 20% increased relative risk of dementia, but residual confounding and reverse causality cannot be ruled out [50]. Higher cumulative anticholinergic medication use is also associated with an increased risk of dementia [51]. When prescribing antimuscarinic agents for urgent urinary incontinence, physicians should consider the total antimuscarinic load,

especially in elderly patients on multiple drugs and those who have/are at risk for mild cognitive dysfunction [52]. Alternative OAB treatments may be more appropriate for patients above 65 years of age and those with underlying mild cognitive impairment. Thus, mirabegron may be considered the initial medication to avoid difficulty in urination and cognitive impairment [44,53].

## BOTULINUM TOXIN INTRAVESICAL INJECTION FOR NEUROGENIC OVERACTIVE BLADDER

In recent decades, BoNT-A has been widely applied in the treatment of skeletal or smooth muscle hypertonicity and modulation of chronic inflammation, and sensory and glandular dysfunction [54,55]. BoNT-A has been recommended as the treatment for idiopathic OAB and neurogenic DO due to spinal cord injury or multiple sclerosis after the medical treatment with an adequate dose of antimuscarinics and mirabegron has been failed [56-60]. Detrusor injections of BoNT-A for OAB refractory to the oral medication have been proven highly effective than the other lines of therapy and are the most effective option among all pharmacologic therapies [57]. BoNT-A detrusor injections can not only significantly improve OAB symptoms and quality of life, but also the urodynamic parameters [58]. Therefore, onabotulinumtoxinA has already gained the approval for treatment of neurogenic DO at the dose of 200 U, and treatment of idiopathic OAB at the dose of 100 U [59,60].

Although BoNT-A injections are highly effective, adverse events are also common. The advantages and disadvantages of BoNT-A compared with oral OAB medications have been well-reported [61]. The advantages include a decrease in frequency, urgency, and nocturia, as well as a reduction in urgency incontinence. There is also an increase in cystometric bladder capacity and voided volume [62-68]. Moreover, since the absorption of BoNT-A from the urinary bladder is limited, systemic adverse events are unlikely (in contrast to antimuscarinic agents), and cognitive impairment after antimuscarinics in elderly patients with CNS lesions can also be prevented [65,66]. The therapeutic efficacy of

BoNT-A usually lasts for more than 6 months, and thus, only 1-2 intravesical injections per year are necessary to achieve the desired therapeutic efficacy [69,70]. However, the disadvantages of BoNT-A injections include impairment of bladder fullness sensation due to inhibiting the release of sensory neuropeptides, difficulty in initiating urination due to hypocontractility via inhibiting the release of acetylcholine, increased PVR volume, and decrease of voiding efficiency due to impaired bladder sensation, and the risk of acute urinary retention and UTI due to large PVR [71,72]. Under these concerns, patients receiving BoNT-A injections for OAB or NDO should be informed of the need for CIC [73].

Previous studies of BoNT-A in elderly patients with OAB and older patients with CNS-related OAB have demonstrated that intravesical injection of 100 U of onabotulinumtoxinA effectively decreased urgency symptoms. The adverse events were acceptable, and the long-term effects were comparable to those in OAB patients in general. Patients with CNS lesions did not experience an increased risk of acute urinary retention and UTI but had a higher rate of straining to voiding [61,74].

There have been few clinical trials investigating the safety, efficacy, and adverse events of BoNT-A injections for patients with neurogenic OAB due to CNS lesions. Most published studies reported the treatment outcome of BoNT-A injections in a small number of patients with CNS lesions. The treatment outcome of BoNT-A on neurogenic OAB has been reported satisfactory in patients with CVA, PD, and dementia [74,75], and in male patients with persistent OAB symptoms after transurethral resection of the prostate [76]. However, the durability of detrusor BoNT-A injections for frail elderly patients with OAB might be shorter and the rates of adverse events are higher than those in younger adults and older adults without frailty [77]. Adding on mirabegron after BoNT-A injections could improve OAB symptoms and quality of life in patients with refractory OAB [78]. Considering the adverse effects of BoNT-A on voiding efficiency in elderly patients with neurogenic OAB, BoNT-A injection into the bladder base might decrease the occurrence of adverse events such as difficulty in urination, dysuria, large PVR, and urinary retention [79].

The most frequent adverse events of BoNT-A injections for patients with neurogenic OAB due to CVA are UTI, difficult urination, and chronic urinary retention [80]. Previous study reported that suburothelial injection of 200 U BoNT-A increased bladder capacity and improved incontinence in 91.6% of patients with spinal cord lesions, but in only 50% of patients with CVA [81]. Most clinical practice and researchers treated neurogenic OAB in patients with PD and CVA with intradetrusor injections of 100 U BoNT-A but not 200 U to achieve a long-term clinical effect and reduce adverse effects [68]. After BoNT-A detrusor injection, a total of 79.2% of patients with PD reported improvement of OAB symptoms, while only 29.1% of the patients reported resolution of urinary incontinence. The PVR increased from 17.6 to 125.3 mL after BoNT-A injection, and 12.5% of the patients needed CIC after BoNT-A injections [82]. A higher PVR before BoNT-A

injection has been reported to be the predictor of postoperative urinary retention, failed treatment outcome, and requiring CIC. In a small cohort study of 16 patients with PD and neurogenic OAB treated with BoNT-A detrusor injection revealed that only 20% of the patients had an excellent result, significant improvement in 40%, and % failure in 40% of patients, CIC was needed in 28% of the patients [83]. A systematic analysis of randomized control trials also reported that among several treatments for neurogenic OAB in PD patients, treatment with BoNT-A detrusor injections did not provide strong evidence to improve outcomes in this population [84].

In patients with dementia and neurogenic OAB, pharmacologic therapy with anticholinergic medications is another option for treating urgency incontinence if behavioral therapy is unsuccessful [85]. However, chronic use (3 months) of OAB anticholinergic medications has been reported to be associated with an exacerbated cognitive impairment or increased risk of new-onset dementia [86]. Therefore, intravesical BoNT-A injection is an alternative treatment choice to effectively treat patients with early dementia with normal bladder perception and UUI. However, the efficacy of BoNT-A has been reported to be limited in patients with dementia who do not perceive bladder fullness or urgency or are wheelchair ridden [87].

## REAL-LIFE EXPERIENCE WITH BOTOX TREATMENT FOR NEUROGENIC OVERACTIVE BLADDER

Previous clinical trials reported that BoNT-A injection provided satisfactory treatment outcomes for patients with NDO due to CNS diseases [63,66,69,70,74,81,82]. However, in a report of the real-life analysis of the treatment efficacy of detrusor injections of BoNT-A on neurogenic OAB due to CNS lesions, the overall continence rate after BoNT-A injections was only 28.4% (21 in 74 patients), urinary incontinence improved in 54.1% (40 in 74), and treatment failed in 17.6% (13 in 74). Alternatively, dysuria was reported in 59.5% of patients, acute urinary retention developed in 9.5%, and UTI occurred in 14.9%. Postoperative PVR increased to 44% of the bladder capacity, and the therapeutic duration of BoNT-A lasted for a mean of 6.4 months [88]. There was no significant difference in the rates of clinical improvement, adverse events, and therapeutic duration among patients with CVA, PD, and dementia. The urodynamic parameters such as DO, DU, and the presence of urethral sphincter pseudodysynergia also did not affect the treatment outcome.

Because light anesthesia is necessary during BoNT-A injections, patients who have symptom improvement after treatment might hesitate to repeat treatment after the therapeutic efficacy has faded. For patients with neurogenic OAB due to CNS lesions, the addition of oral antimuscarinic agents has been reported to increase the intervals for repeated BoNT-A injections [89]. In patients with OAB who received intravesical BoNT-A injection, adding mirabegron 50 mg on BoNT-A treatment could significantly decrease the percentage of OAB wet compared to the patients who were adding solifenacin 5 mg and those without adding OAB medication [79]. With this clinical evidence, it is



rational to add mirabegron when the therapeutic effect of detrusor BoNT-A injection for neurogenic OAB begins to fade. The combination of BoNT-A injection and mirabegron may increase the therapeutic duration and prolong the injection interval. Combination treatment using different pharmacological and non-pharmacological therapies can achieve the best clinical efficacy because of the favorable combination of the different mechanisms of action [43].

There have been reports from a pilot study or small case series that support the therapeutic efficacy of BoNT-A for neurogenic OAB in patients with PD and CVA [90]. The results of BoNT-A 100 U injection for patients with PD and urinary incontinence revealed to have moderate to marked symptomatic relief at 3 months after BoNT-A injection, and 59% of the patients reported a 50% decrease in episodes of urinary incontinence over 6 months relative to pretreatment [91]. However, in a study of a large cohort (140 patients) with neurogenic OAB who received BoNT-A injection, the 10-year discontinuation-free rate was 49.1%, and the failure-free success rate was 73% [92]. The causes of BoNT-A discontinuation included treatment failure (43.7%), withdrawal of consent (28.1%), improvement of OAB after prior BoNT-A injection (14.1%), neurological progression (12.5%), and adverse events (1.6%). In real-life practice, patients with neurogenic OAB due to CNS lesions might have a disability in motor function and hand dexterity. Therefore, although BoNT-A injection could improve urgency or decrease episodes of UI, urinary incontinence might persist and bother them. Patients with CNS lesions and UI who have partial benefit from BoNT-A injections might prefer to wear a diaper in long-term bladder management.

Knowing the advantages and disadvantages of BoNT-A injections for neurogenic OAB, we should also consider the therapeutic efficacy and adverse events of OAB medications to select the appropriate oral therapy for patients with BOO, aging, frailty, low detrusor contractility, and CNS lesions. Adding an alpha-blocker and using the low-dose beta-3 adrenoceptor agonist mirabegron might be safer in the initial treatment of neurogenic OAB. Second-line therapy can include low-dose antimuscarinic agents such as trospium, solifenacin, or tolterodine, but not oxybutynin, to avoid cognitive impairment. If monotherapy is not effective in alleviating OAB symptoms, combination therapy with antimuscarinics and mirabegron can be given. During the initial treatment course, it is essential to monitor cognitive function, PVR, and voiding difficulty. If cognitive impairment or large PVR develops, treatment should be discontinued. Video urodynamic studies of patients with neurogenic OAB will be helpful to identify the presence of DU and functional BOO such as bladder neck dysfunction or pseudodyssynergia. If the bladder sensation is intact and no BOO is found, a detrusor BoNT-A injection may be used to treat urinary incontinence. However, patients with CNS lesions and neurogenic OAB should be informed of the potential adverse events before BoNT-A injection and be closely monitored for urinary retention and UTI [9]. A proposed treatment algorithm for patients with CNS

lesions and neurogenic OAB, including changing treatment modalities, can be seen in Figure 2.

## PHARMACOLOGICAL THERAPY AND BOTULINUM TOXIN A URETHRAL SPHINCTER INJECTION FOR NEUROGENIC VOIDING DYSFUNCTION

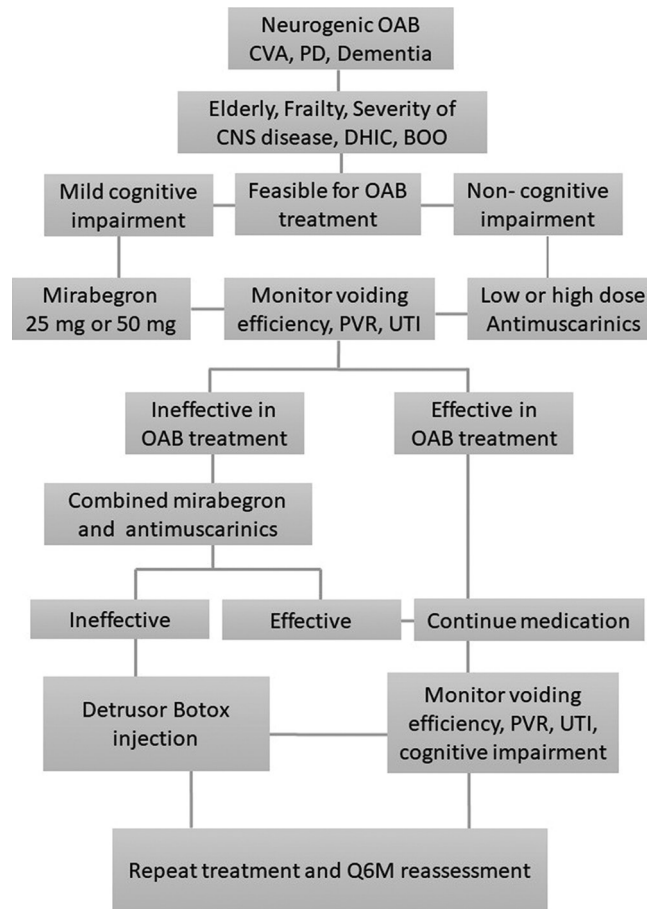
Voiding dysfunction is common in patients with LUTD due to CNS lesions. Patients with neurogenic lesions and voiding dysfunction often have a mix of storage and voiding symptoms. Moreover, ambulatory patients who wish to urinate voluntarily without catheterization may prefer resumption of voiding ability [39,93-95].

The causes of voiding dysfunction could be DU, BOO, or pseudodyssynergia. A previous study showed that bladder outlet surgery is effective in alleviating voiding symptoms in patients with CVA and PD but not in those with dementia. Nevertheless, bladder outlet surgery did not have an effect on storage symptoms in patients with chronic CNS lesions [3]. Although bladder outlet surgeries could relieve BOO, patients may have persistent voiding symptoms or exacerbated storage symptoms.

Patients with voiding dysfunction due to CNS lesions are usually initially treated with alpha-blockers, skeletal muscle relaxants, and 5-alpha-reductase inhibitors if BPH is suspected. However, patients with DU or pseudodyssynergia may not be satisfactorily treated with these oral medications. Urethral sphincter injections with BoNT-A (100–200 U in 4 mL) divided in equal doses into 4 quadrants of the urethral sphincter are effective in patients with multiple sclerosis, CVA, or spinal cord injury [96,97]. Patients with CVA and chronic urinary retention can also forego CIC after urethral BoNT-A injection (100 U) [16]. Patients with dementia tended to have dysuria, a higher UTI rate, and a shorter therapeutic duration of urethral BoNT-A. The results of BoNT-A urethral sphincter injection were similar between patients with pseudodyssynergia and those with DU. A significant reduction of voiding detrusor pressure was observed only in patients with urethral sphincter dyscoordination or pseudodyssynergia [98]. In a report of the study from 45 patients with CVA, PD, or dementia, 75.6% of patients had improved voiding efficiency after urethral sphincter BoNT-A injection, but 24.4% were bothered by the exacerbated urinary incontinence, 33.3% complained of dysuria, and 15.6% developed UTI. Patients with DU showed the least benefit from urethral BoNT-A injection in terms of voiding dysfunction. Although urethral sphincter BoNT-A injection is effective in reducing voiding detrusor pressure, increasing voiding efficiency, incomplete bladder emptying due to unsustainable detrusor contractility remains a problem to be solved, while *de novo* urgency, UI, or stress urinary incontinence might be another issue after urethral sphincter BoNT-A treatment in women with neurogenic LUTD [96,97,99,100]. Therefore, patients with neurogenic voiding dysfunction might not be satisfied with the therapeutic outcome of urethral sphincter BoNT-A injection [99,101].

## CONCLUSION

OAB symptoms due to CNS lesions such as CVA, PD, and dementia are common. LUTD in patients with neurogenic



**Figure 2:** A treatment algorithm for patients with central nervous system lesions and neurogenic overactive bladder. CVA: Cerebrovascular accident, PD: Parkinson's disease, DHIC: Detrusor hyperreflexia and inadequate contractility, BOO: Bladder outlet obstruction, OAB: Overactive bladder, PVR: Postvoid residual, UTI: Urinary tract infection

lesions involves both storage and emptying symptoms. Treatment with oral medications might not be effective in improving clinical symptoms without creating new adverse events. Intravesical BoNT-A injection provides an opportunity to restore urinary continence, and urethral sphincter BoNT-A injection can improve voiding efficiency. However, undesired adverse events might be bothersome issues such as difficulty in urination, large PVR, need for CIC, and risk of UTI after intravesical BoNT-A injections. Moreover, exacerbated urinary incontinence, persistent dysuria, and incomplete bladder emptying may also reduce the satisfactory rate of urethral sphincter BoNT-A injection for voiding dysfunction, which may limit the application of BoNT-A in the treatment of neurogenic LUTD in patients with CNS lesions. Thus, patients with NLUTD due to CNS lesions who are refractory to medical treatment and desire BoNT-A injection should be informed of the limited therapeutic efficacy and the potential adverse events before injection.

#### Data availability statement

Data sharing not applicable to this article as no datasets were generated or analyzed during the current study.

#### Financial support and sponsorship

This study was supported by grants from the Tzu Chi Medical Foundation, TCMF-SP-112-01 and TCMF-MP-110-03-01.

#### Conflicts of interest

Dr. Hann-Chorng Kuo, an editorial board member at *Tzu Chi Medical Journal*, had no role in the peer review process or the decision to publish this article.

#### REFERENCES

- Griffiths D, Derbyshire S, Stenger A, Resnick N. Brain control of normal and overactive bladder. *J Urol* 2005;174:1862-7.
- Tudor KI, Sakakibara R, Panicker JN. Neurogenic lower urinary tract dysfunction: Evaluation and management. *J Neurol* 2016;263:2555-64.
- Chang TL, Chen SF, Kuo HC. Surgical outcome of male patients with chronic central nervous system disorders and voiding dysfunction due to bladder outlet obstruction. *Int Urol Nephrol* 2022;54:2511-9.
- Malone-Lee J, Wahedna I. Characterisation of detrusor contractile function in relation to old age. *Br J Urol* 1993;72:873-80.
- Resnick NM, Yalla SV. Detrusor hyperactivity with impaired contractile function. An unrecognized but common cause of incontinence in elderly patients. *JAMA* 1987;257:3076-81.
- Griffiths DJ, McCracken PN, Harrison GM, Gormley EA, Moore K, Hooper R, et al. Cerebral aetiology of urinary urge incontinence in elderly people. *Age Ageing* 1994;23:246-50.
- Del-Ser T, Munoz DG, Hachinski V. Temporal pattern of cognitive decline and incontinence is different in Alzheimer's disease and diffuse Lewy body disease. *Neurology* 1996;46:682-6.
- Andrews JS, Jansen JH, Linders S, Princen A. Effects of disrupting the cholinergic system on short-term spatial memory in rats.



- Psychopharmacology (Berl) 1994;115:485-94.
9. Pettersen R, Stien R, Wyller TB. Post-stroke urinary incontinence with impaired awareness of the need to void: Clinical and urodynamic features. *BJU Int* 2007;99:1073-7.
10. Williams MP, Srikanth V, Bird M, Thrift AG. Urinary symptoms and natural history of urinary continence after first-ever stroke – A longitudinal population-based study. *Age Ageing* 2012;41:371-6.
11. Sakakibara R, Hattori T, Yasuda K, Yamanishi T. Micturitional disturbance after acute hemispheric stroke: Analysis of the lesion site by CT and MRI. *J Neurol Sci* 1996;137:47-56.
12. Sakakibara R. Lower urinary tract dysfunction in patients with brain lesions. *Handb Clin Neurol* 2015;130:269-87.
13. Pettersen R, Wyller TB. Prognostic significance of micturition disturbances after acute stroke. *J Am Geriatr Soc* 2006;54:1878-84.
14. Tsuchida S, Noto H, Yamaguchi O, Itoh M. Urodynamic studies on hemiplegic patients after cerebrovascular accident. *Urology* 1983;21:315-8.
15. Meng NH, Lo SF, Chou LW, Yang PY, Chang CH, Chou EC. Incomplete bladder emptying in patients with stroke: Is detrusor external sphincter dyssynergia a potential cause? *Arch Phys Med Rehabil* 2010;91:1105-9.
16. Chen YH, Kuo HC. Botulinum A toxin treatment of urethral sphincter pseudodyssynergia in patients with cerebrovascular accidents or intracranial lesions. *Urol Int* 2004;73:156-61.
17. Lang AE, Lozano AM. Parkinson's disease. Second of two parts. *N Engl J Med* 1998;339:1130-43.
18. McDonald C, Winge K, Burn DJ. Lower urinary tract symptoms in Parkinson's disease: Prevalence, aetiology and management. *Parkinsonism Relat Disord* 2017;35:8-16.
19. Stocchi F, Carbone A, Inghilleri M, Monge A, Ruggieri S, Berardelli A, et al. Urodynamic and neurophysiological evaluation in Parkinson's disease and multiple system atrophy. *J Neurol Neurosurg Psychiatry* 1997;62:507-11.
20. Sakakibara R, Uchiyama T, Yamanishi T, Shirai K, Hattori T. Bladder and bowel dysfunction in Parkinson's disease. *J Neural Transm (Vienna)* 2008;115:443-60.
21. Chandiramani VA, Palace J, Fowler CJ. How to recognize patients with Parkinsonism who should not have urological surgery. *Br J Urol* 1997;80:100-4.
22. Berger Y, Blaivas JG, DeLaRocha ER, Salinas JM. Urodynamic findings in Parkinson's disease. *J Urol* 1987;138:836-8.
23. Galloway NT. Urethral sphincter abnormalities in Parkinsonism. *Br J Urol* 1983;55:691-3.
24. Du J, Cui S, Huang P, Gao C, Zhang P, Liu J, et al. Predicting the prognosis of multiple system atrophy using cluster and principal component analysis. *J Parkinsons Dis* 2023;13:937-46.
25. Kirby R, Fowler C, Gosling J, Bannister R. Urethro-vesical dysfunction in progressive autonomic failure with multiple system atrophy. *J Neurol Neurosurg Psychiatry* 1986;49:554-62.
26. Lee YH, Lee JE, Ryu DW, Oh YS, Lee KS, Hong SH, et al. Urinary dysfunctions and post-void residual urine in typical and atypical Parkinson diseases. *J Parkinsons Dis* 2018;8:145-52.
27. Papatsonis AG, Papapetropoulos S, Singer C, Deliveliotis C. Urinary and erectile dysfunction in multiple system atrophy (MSA). *Neurourol Urodyn* 2008;27:22-7.
28. Blaivas JG. Pathophysiology of lower urinary tract dysfunction. *Urol Clin North Am* 1985;12:215-24.
29. Akhavan-Sigari R, Mortzavi-Zadeh P, Trakolis L, Keyhan H, Amend B, Herlan S. The connection between frontal lobe brain tumors and lower urinary tract symptoms – Series of 347 patients. *Eur Rev Med Pharmacol Sci* 2021;25:654-60.
30. Leach GE, Farsaii A, Kark P, Raz S. Urodynamic manifestations of cerebellar ataxia. *J Urol* 1982;128:348-50.
31. Yamamoto T, Sakakibara R, Uchiyama T, Liu Z, Ito T, Awa Y, et al. When is Onuf's nucleus involved in multiple system atrophy? A sphincter electromyography study. *J Neurol Neurosurg Psychiatry* 2005;76:1645-8.
32. Afonso Ribeiro J, Simeoni S, De Min L, Uchiyama T, Tung Lo Y, Solanky N, et al. Lower urinary tract and bowel dysfunction in spinocerebellar ataxias. *Ann Clin Transl Neurol* 2021;8:321-31.
33. Reid CJ, Borzyskowski M. Lower urinary tract dysfunction in cerebral palsy. *Arch Dis Child* 1993;68:739-42.
34. Mayo ME. Lower urinary tract dysfunction in cerebral palsy. *J Urol* 1992;147:419-20.
35. Samijn B, Van Laecke E, Renson C, Hoebeke P, Plasschaert F, Vande Walle J, et al. Lower urinary tract symptoms and urodynamic findings in children and adults with cerebral palsy: A systematic review. *Neurourol Urodyn* 2017;36:541-9.
36. McKenzie P, Badlani GH. The incidence and etiology of overactive bladder in patients after cerebrovascular accident. *Curr Urol Rep* 2012;13:402-6.
37. Sakakibara R, Panicker J, Fowler CJ, Tateno F, Kishi M, Tsuyusaki Y, et al. Is overactive bladder a brain disease? The pathophysiological role of cerebral white matter in the elderly. *Int J Urol* 2014;21:33-8.
38. Ruffion A, Castro-Diaz D, Patel H, Khalaf K, Onyenwenyi A, Globe D, et al. Systematic review of the epidemiology of urinary incontinence and detrusor overactivity among patients with neurogenic overactive bladder. *Neuroepidemiology* 2013;41:146-55.
39. Linsenmeyer TA. Post-CVA voiding dysfunctions: Clinical insights and literature review. *NeuroRehabilitation* 2012;30:1-7.
40. Chou YC, Jiang YH, Harnod T, Kuo HC. Characteristics of neurogenic voiding dysfunction in cerebellar stroke: A cross-sectional, retrospective video urodynamic study. *Cerebellum* 2013;12:601-6.
41. Godmer M, Guinet-Lacoste A, Charvier K, Luauté J, Rode G, Soler JM, et al. Is there any obstruction other than prostatic obstruction in idiopathic Parkinson's disease? *Prog Urol* 2019;29:579-85.
42. Chiang CH, Chen SF, Kuo HC. Video-urodynamic characteristics of lower urinary tract dysfunctions in patients with chronic brain disorders. *Neurourol Urodyn* 2022;41:255-63.
43. Bapir R, Bhatti KH, Eliwa A, García-Perdomo HA, Gherabi N, Hennessey D, et al. Efficacy of overactive neurogenic bladder treatment: A systematic review of randomized controlled trials. *Arch Ital Urol Androl* 2022;94:492-506.
44. Chen SF, Kuo HC. Therapeutic efficacy of low-dose (25 mg) mirabegron therapy for patients with mild to moderate overactive bladder symptoms due to central nervous system diseases. *Low Urin Tract Symptoms* 2019;11:O53-8.
45. Kuo YC, Kuo HC. Comparative study of different combinations of mirabegron and antimuscarinics in treatment for overactive bladder syndrome in elderly patients. *Tzu Chi Med J* 2023;35:62-8.
46. Hajebrahimi S, Darvishi A, HajEbrahimi R, Asadi N, Jafari Shendi Z, Asiaban N, et al. Efficacy and safety of desmopressin in nocturia and nocturnal polyuria control of neurological patients: A systematic review and meta-analysis. *Neurourol Urodyn* 2024;43:167-82.
47. Peyronnet B, Lapitan MC, Tzelvels L, O'Connor E, Nic An Riogh A, Manso M, et al. Benefits and harms of conservative, pharmacological, and surgical management options for women with bladder outlet obstruction: A systematic review from the European Association of Urology non-neurogenic female LUTS guidelines panel. *Eur Urol Focus* 2022;8:1340-61.
48. Cohn JA, Brown ET, Reynolds WS, Kaufman MR, Dmochowski RR. Pharmacologic management of non-neurogenic functional obstruction in women. *Expert Opin Drug Metab Toxicol* 2016;12:657-67.
49. Kay GG, Abou-Donia MB, Messer WS Jr., Murphy DG, Tsao JW, Ouslander JG. Antimuscarinic drugs for overactive bladder and their potential effects on cognitive function in older patients. *J Am Geriatr Soc* 2005;53:2195-201.

50. Welk B, Richardson K, Panicker JN. The cognitive effect of anticholinergics for patients with overactive bladder. *Nat Rev Urol* 2021;18:686-700.
51. Gray SL, Anderson ML, Dublin S, Hanlon JT, Hubbard R, Walker R, et al. Cumulative use of strong anticholinergics and incident dementia: A prospective cohort study. *JAMA Intern Med* 2015;175:401-7.
52. Burkhard FC, Bosch JLHR, Cruz F, Lemack GE, Nambiar AK, Thiruchelvam N, et al. EAU Guidelines on urinary incontinence. European Association of Urology 2017.
53. Chen SF, Chuang YC, Wang CC, Liao CH, Kuo HC. Therapeutic efficacy and cognitive adverse events of overactive bladder medication in patients with central nervous system disorders – A cohort study. *J Formos Med Assoc* 2022;121:2101-8.
54. Cruz F. Targets for botulinum toxin in the lower urinary tract. *Neurourol Urodyn* 2014;33:31-8.
55. Apostolidis A, Dasgupta P, Fowler CJ. Proposed mechanism for the efficacy of injected botulinum toxin in the treatment of human detrusor overactivity. *Eur Urol* 2006;49:644-50.
56. Lightner DJ, Gomelsky A, Souter L, Vasavada SP. Diagnosis and treatment of overactive bladder (non-neurogenic) in adults: AUA/SUFU guideline amendment 2019. *J Urol* 2019;202:558-63.
57. Liu P, Li Y, Shi B, Zhang Q, Guo H. Comparison of different types of therapy for overactive bladder: A systematic review and network meta-analysis. *Front Med (Lausanne)* 2022;9:1014291.
58. Chapple C, Sievert KD, MacDiarmid S, Khullar V, Radziszewski P, Nardo C, et al. OnabotulinumtoxinA 100 U significantly improves all idiopathic overactive bladder symptoms and quality of life in patients with overactive bladder and urinary incontinence: A randomised, double-blind, placebo-controlled trial. *Eur Urol* 2013;64:249-56.
59. Mangera A, Apostolidis A, Andersson KE, Dasgupta P, Giannantoni A, Roehrborn C, et al. An updated systematic review and statistical comparison of standardised mean outcomes for the use of botulinum toxin in the management of lower urinary tract disorders. *Eur Urol* 2014;65:981-90.
60. Jiang YH, Liao CH, Kuo HC. Current and potential urological applications of botulinum toxin A. *Nat Rev Urol* 2015;12:519-33.
61. Kuo HC. OnabotulinumtoxinA treatment for overactive bladder in the elderly: Practical points and future prospects. *Drugs Aging* 2016;33:1-9.
62. Kuo HC. Urodynamic evidence of effectiveness of botulinum A toxin injection in treatment of detrusor overactivity refractory to anticholinergic agents. *Urology* 2004;63:868-72.
63. Kessler TM, Danuser H, Schumacher M, Studer UE, Burkhard FC. Botulinum A toxin injections into the detrusor: An effective treatment in idiopathic and neurogenic detrusor overactivity? *Neurourol Urodyn* 2005;24:231-6.
64. Kuo HC. Will suburothelial injection of small dose of botulinum A toxin have similar therapeutic effects and less adverse events for refractory detrusor overactivity? *Urology* 2006;68:993-7.
65. Dmochowski R, Chapple C, Nitti VW, Chancellor M, Everaert K, Thompson C, et al. Efficacy and safety of onabotulinumtoxinA for idiopathic overactive bladder: A double-blind, placebo controlled, randomized, dose ranging trial. *J Urol* 2010;184:2416-22.
66. Popat R, Apostolidis A, Kalsi V, Gonzales G, Fowler CJ, Dasgupta P. A comparison between the response of patients with idiopathic detrusor overactivity and neurogenic detrusor overactivity to the first intradetrusor injection of botulinum-A toxin. *J Urol* 2005;174:984-9.
67. Sahai A, Khan MS, Dasgupta P. Efficacy of botulinum toxin-A for treating idiopathic detrusor overactivity: Results from a single center, randomized, double-blind, placebo controlled trial. *J Urol* 2007;177:2231-6.
68. Brubaker L, Richter HE, Visco A, Mahajan S, Nygaard I, Braun TM, et al. Refractory idiopathic urge urinary incontinence and botulinum A injection. *J Urol* 2008;180:217-22.
69. Kulaksizoglu H, Parman Y. Use of botulinum toxin-A for the treatment of overactive bladder symptoms in patients with Parkinson's disease. *Parkinsonism Relat Disord* 2010;16:531-4.
70. Giannantoni A, Conte A, Proietti S, Giovannozzi S, Rossi A, Fabbrini G, et al. Botulinum toxin type A in patients with Parkinson's disease and refractory overactive bladder. *J Urol* 2011;186:960-4.
71. Kuo HC. Clinical effects of suburothelial injection of botulinum A toxin on patients with nonneurogenic detrusor overactivity refractory to anticholinergics. *Urology* 2005;66:94-8.
72. Kuo HC, Liao CH, Chung SD. Adverse events of intravesical botulinum toxin A injections for idiopathic detrusor overactivity: Risk factors and influence on treatment outcome. *Eur Urol* 2010;58:919-26.
73. Apostolidis A, Dasgupta P, Denys P, Elneil S, Fowler CJ, Giannantoni A, et al. Recommendations on the use of botulinum toxin in the treatment of lower urinary tract disorders and pelvic floor dysfunctions: A European consensus report. *Eur Urol* 2009;55:100-19.
74. Jiang YH, Liao CH, Tang DL, Kuo HC. Efficacy and safety of intravesical onabotulinumtoxinA injection on elderly patients with chronic central nervous system lesions and overactive bladder. *PLoS One* 2014;9:e105989.
75. Hu JC, Hsu LN, Lee WC, Chuang YC, Wang HJ. Role of urological botulinum toxin-A injection for overactive bladder and voiding dysfunction in patients with Parkinson's disease or post-stroke. *Toxins (Basel)* 2023;15:166.
76. Lee HY, Kuo HC. Intravesical injection of botulinum toxin type A in men without bladder outlet obstruction and post-deobstructive prostate surgery. *Toxins (Basel)* 2023;15:221.
77. Liao CH, Kuo HC. Increased risk of large post-void residual urine and decreased long-term success rate after intravesical onabotulinumtoxinA injection for refractory idiopathic detrusor overactivity. *J Urol* 2013;189:1804-10.
78. Wang CC, Lee CL, Hwang YT, Kuo HC. Adding mirabegron after intravesical onabotulinumtoxinA injection improves therapeutic effects in patients with refractory overactive bladder. *Low Urin Tract Symptoms* 2021;13:440-7.
79. Jiang YH, Jhang JF, Kuo HC. The clinical application of intravesical botulinum toxin A injection in patients with overactive bladder and interstitial cystitis. *Tzu Chi Med J* 2023;35:31-7.
80. Nitti V, Haag-Molkenteller C, Kennelly M, Chancellor M, Jenkins B, Schurch B. Treatment of neurogenic detrusor overactivity and overactive bladder with Botox (onabotulinumtoxinA): Development, insights, and impact. *Medicine (Baltimore)* 2023;102:e32377.
81. Kuo HC. Therapeutic effects of suburothelial injection of botulinum A toxin for neurogenic detrusor overactivity due to chronic cerebrovascular accident and spinal cord lesions. *Urology* 2006;67:232-6.
82. Vurture G, Peyronnet B, Feigin A, Biagioni MC, Gilbert R, Rosenblum N, et al. Outcomes of intradetrusor onabotulinum toxin A injection in patients with Parkinson's disease. *Neurourol Urodyn* 2018;37:2669-77.
83. Atamian A, Sichez PC, Michel F, Bandelier Q, Fall M, Gaillet S, et al. Intradetrusor injections of botulinum toxin A to treat urinary incontinence due to bladder overactivity during idiopathic Parkinson's disease. *Prog Urol* 2021;31:430-8.
84. Hajebrahimi S, Chapple CR, Pashazadeh F, Salehi-Pourmehr H. Management of neurogenic bladder in patients with Parkinson's disease: A systematic review. *Neurourol Urodyn* 2019;38:31-62.
85. Goode PS, Burgio KL, Richter HE, Markland AD. Incontinence in older women. *JAMA* 2010;303:2172-81.
86. Zilliox J, Welk B, Suskind AM, Gormley EA, Goldman HB. SUFU white paper on overactive bladder anticholinergic medications and dementia risk. *Neurourol Urodyn* 2022;41:1928-33.
87. Jiang YH, Chen SF, Kuo HC. Frontiers in the clinical applications of botulinum toxin A as treatment for neurogenic lower urinary tract dysfunction. *Int Neurourol J* 2020;24:301-12.
88. Jiang YH, Jhang JF, Chen SF, Kuo HC. Real-life treatment outcome of

- botulinum toxin A injection on overactive bladder and voiding dysfunction in patients with central nervous system lesion. *Toxins* 2024;16:123.
89. Ciofu I, Ceausu I, Chirca NM, Persu C. Solifenacin treatment after intradetrusor injections with botulinum toxin in patients with neurogenic detrusor overactivity. *Am J Ther* 2022;29:e507-11.
  90. Kaviani A, Khavari R. Disease-specific outcomes of botulinum toxin injections for neurogenic detrusor overactivity. *Urol Clin North Am* 2017;44:463-74.
  91. Anderson RU, Orenberg EK, Glowe P. OnabotulinumtoxinA office treatment for neurogenic bladder incontinence in Parkinson's disease. *Urology* 2014;83:22-7.
  92. Baron M, Peyronnet B, Aublé A, Hascoet J, Castel-Lacanal E, Miget G, et al. Long-term discontinuation of botulinum toxin A intradetrusor injections for neurogenic detrusor overactivity: A multicenter study. *J Urol* 2019;201:769-76.
  93. Jiang YH, Kuo HC. Current optimal pharmacologic therapies for overactive bladder. *Expert Opin Pharmacother* 2023;24:2005-19.
  94. Araki I, Kitahara M, Oida T, Kuno S. Voiding dysfunction and Parkinson's disease: Urodynamic abnormalities and urinary symptoms. *J Urol* 2000;164:1640-3.
  95. Choi JB. Dementia and voiding dysfunction. *J Korean Continence Soc* 2008;12:10-8.
  96. Kuo HC. Botulinum A toxin urethral injection for the treatment of lower urinary tract dysfunction. *J Urol* 2003;170:1908-12.
  97. Smith CP, Nishiguchi J, O'Leary M, Yoshimura N, Chancellor MB. Single-institution experience in 110 patients with botulinum toxin A injection into bladder or urethra. *Urology* 2005;65:37-41.
  98. Jiang YH, Wang CC, Kuo HC. OnabotulinumtoxinA urethral sphincter injection as treatment for non-neurogenic voiding dysfunction – A randomized, double-blind, placebo-controlled study. *Sci Rep* 2016;6:38905.
  99. Kuo HC. Satisfaction with urethral injection of botulinum toxin A for detrusor sphincter dyssynergia in patients with spinal cord lesion. *Neurourol Urodyn* 2008;27:793-6.
  100. Gallien P, Reymann JM, Amarenco G, Nicolas B, de Sèze M, Bellissant E. Placebo controlled, randomised, double blind study of the effects of botulinum A toxin on detrusor sphincter dyssynergia in multiple sclerosis patients. *J Neurol Neurosurg Psychiatry* 2005;76:1670-6.
  101. Maria G, Brisinda G, Civello IM, Bentivoglio AR, Sganga G, Albanese A. Relief by botulinum toxin of voiding dysfunction due to benign prostatic hyperplasia: Results of a randomized, placebo-controlled study. *Urology* 2003;62:259-64.