



Review Article

Cystoscopic characteristic findings of interstitial cystitis and clinical implications

Wan-Ru Yu^{a,b}, Yuan-Hong Jiang^c, Jia-Fong Jhang^c, Hann-Chorng Kuo^{c*}

^aDepartment of Nursing, Hualien Tzu Chi Hospital, Buddhist Tzu Chi Medical Foundation, Hualien, Taiwan, ^bInstitute of Medical Sciences, Tzu Chi University, Hualien, Taiwan, ^cDepartment of Urology, Hualien Tzu Chi Hospital, Buddhist Tzu Chi Medical Foundation and Tzu Chi University, Hualien, Taiwan

Submission : 06-Jul-2023
Revision : 25-Jul-2023
Acceptance : 27-Jul-2023
Web Publication : 22-Aug-2023

ABSTRACT

Interstitial cystitis/bladder pain syndrome (IC/BPS) is a chronic inflammatory bladder disease of unknown etiology, characterized by bladder pain and frequency urgency symptoms. Based on the cystoscopic findings after hydrodistention under anesthesia, the phenotype of IC/BPS includes no glomerulation, characteristic glomerulation, and with Hunner's lesion. IC is specifically defined if there are characteristic Hunner's lesion appeared in cystoscopy or after hydrodistention. If there are glomerulations without Hunner's lesion, BPS should be considered. The definition of Hunner's lesion and glomerulations differs based on different definition and observations. Currently, there has been no clear description and grading of the glomerulations and Hunner's lesion. Because the classification of IC/BPS has an impact on the treatment strategy and associated with therapeutic outcome, it is unmet to have a clear definition and consensus on the characteristic cystoscopic findings of IC/BPS. This article reviews the literature and presents the figures of Hunner's lesions and description of different mucosal lesions after cystoscopic hydrodistention.

KEYWORDS: *Bladder pain, Cystoscopy, Glomerulation, Interstitial cystitis*

INTRODUCTION

Interstitial cystitis (IC) has been reported for more than 100 years. This bladder disease was first found to have a reduced bladder capacity and a specific bladder ulceration [1]. The ulcer was later found not a typical ulcer but a dense inflammatory lesion with radiating vessels with central coagulum or bleeding at a distended bladder. Later on, part of the patients with symptoms of frequency and bladder pain were found to have submucosal hemorrhage, or so called glomerulations, without presence of a ulcer [2]. The former is currently termed IC with Hunner's lesion, or Hunner's IC (HIC), and the latter was termed non-HIC (NHIC). However, not all patients with bladder pain and frequency can be found to have glomerulations after bladder hydrodistention under anesthesia. Some patients were found to have a reduced bladder capacity after hydrodistention without glomerulation [3,4].

There have been variations in the diagnosis of IC. The common symptoms of IC include pelvic pain, urinary frequency, and urgency, nocturia, pelvic discomfort, urinary dysfunction, and multi-organ symptoms. Because bladder pain is the cardinal symptom, and some patients do not have bladder glomerulation findings after hydrodistention, the term bladder pain syndrome (BPS) was suggested to define this specific

bladder disorder [5]. IC/BPS is a collective term for this bladder disorder. In 2008, the European Society for the Study of IC (ESSIC) defined IC/BPS as the presence of chronic pelvic pain for more than 6 months, with a pressure or discomfort sensation which is related to the urinary bladder and having at least 1 urinary symptom of urgency or frequency. Before establishing a diagnosis of IC/BPS, confusable conditions or diseases should be excluded [6]. In 2011, the American Urological Association guideline defined the hallmark symptom of IC/BPS as pain for more than 6 weeks, including pressure discomfort sensation at the bladder that is refractory to conventional therapy [7]. The Asian guidelines called patients with HIC as IC, whereas those with glomerulation as BPS. All of them have a hypersensitive bladder which includes HIC and NHIC or BPS [5]. There is still no consensus regarding whether we should define IC as the presence of Hunner's lesion and BPS as those with glomerulations.

Regarding the diagnosis of IC/BPS, a patient with frequency urgency and bladder pain, with or without at a full


***Address for correspondence:** Dr. Hann-Chorng Kuo,

Department of Urology, Hualien Tzu Chi Hospital, Buddhist Tzu Chi Medical Foundation, 707, Section 3, Chung-Yang Road, Hualien, Taiwan.
 E-mail: hck@tzuchi.com.tw

This is an open access journal, and articles are distributed under the terms of the Creative Commons Attribution-NonCommercial-ShareAlike 4.0 License, which allows others to remix, tweak, and build upon the work non-commercially, as long as appropriate credit is given and the new creations are licensed under the identical terms.

For reprints contact: WKHLRPMedknow_reprints@wolterskluwer.com

How to cite this article: Yu WR, Jiang YH, Jhang JF, Kuo HC. Cystoscopic characteristic findings of interstitial cystitis and clinical implications. Tzu Chi Med J 2024;36(1):30-7.

Access this article online	
Quick Response Code: 	Website: www.tcmjmed.com
	DOI: 10.4103/tcmj.tcmj_172_23

bladder, which is not relieved by conventional medication such as analgesics, anti-inflammatory agent, or antimuscrinics, should raise a suspicion of IC/BPS [3-7]. Urodynamic study or potassium chloride test, although can increase the diagnostic accuracy of IC/BPS, are not currently listed in the guidelines of IC/BPS [8]. According to the diagnostic criteria of National Institute of Diabetes and Digestive and Kidney Diseases (NIDDK), a cystoscopic hydrodistention under anesthesia and an intravesical pressure of 80 cmH₂O is the must procedure to diagnose IC/BPS. When the cystoscopic hydrodistention shows reduced maximal bladder capacity (MBC) and diffused glomerulations (presence of glomerulations at least in three quadrant of the bladder wall) after decompression, a diagnosis of IC/BPS is made [9]. Bladder biopsy is optional to reveal the chronic inflammation and lymphoplasmacytic infiltration or mastocytosis [10].

CYSTOSCOPY OF HUNNER'S INTERSTITIAL CYSTITIS

For diagnosis of HIC, an office cystoscopy without anesthesia usually is adequate to visualize the presence of Hunner's lesions. The Hunner's lesion usually located at the posterior wall near bladder dome. The bladder wall in HIC usually presents with focal of diffuse thickness, indicating the dense inflammatory tissue beneath the urothelial lesions [5,11]. In bladder computed tomography (CT), the bladder wall underneath Hunner's lesions shows focal or diffused thickening [12]. The mucosa of Hunner's lesion is fragile and may have a central coagulum and easy spotting during cystoscopic examination [Figure 1]. Sometimes, there is scarring underneath the erythematous Hunner's lesion and radiating vessels centered at the fragile lesion, which indicates the chronic inflammatory change of the submucosal tissue of the bladder wall [Figure 2].

Patients with HIC are usually older than NHIC and the bladder pain symptoms are usually more intense than that in NHIC. Patients with HIC have distinct bladder pain symptoms and less medical co-morbidities and psychosomatic syndromes than that in NHIC patients [13]. The bladder pain is usually soon relieved after electrocauterization, but the symptoms will usually return months later.

The Hunner's lesion is not uniformly presented in cystoscopy without anesthesia. After cystoscopic hydrodistention and redistention, a Hunner's lesion is presented with a typical inflammatory reaction: A reddened mucosal area

with small vessels radiating toward a central scar, splitting at distension, usually associated with a waterfall bleeding pattern, which has been described in a recent report [14] [Figure 3].

Patients might have very small Hunner's lesion under cystoscopic examination without anesthesia, but the mucosal fissure and cracks and waterfall bleeding become remarkable after bladder distended under anesthesia [Figure 4]. The bladder pain can usually be relieved soon after electrocauterization of the lesions.

The prevalence rate of HIC is around 10%–20% of total patients with IC/BPS and is dependent on the diagnostic criteria under cystoscopy [14-18]. However, the rate of HIC has been reported higher in Japan [13]. In patients with HIC, the frequency urgency and reduced bladder capacity are associated with severity of Hunner's lesion and the small MBC under anesthesia [19]. Several different appearances of Hunner's lesion are frequently encountered, basically, the Hunner's lesion is composed of erythematous mucosa with central de-epithelialization, radiating vessels toward the center of Hunner's lesion, and chronic scarring of the surrounding bladder wall [13,14] [Figure 5]. The extent of Hunner's lesion might be solitary, multiple, or diffusely locating at the posterior bladder wall. The lesions are closely associated with the thickened portion of the bladder wall in CT of the bladder [12]. Electrocauterization or laser ablation of the Hunner's lesion had been found effective and currently is recommended as the first-line therapy for HIC [20-22]. Fulguration of the Hunner's lesion should be extensively performed to ablate most of the involved bladder wall and prevent recurrence of Hunner's lesion.

CYSTOSCOPIC HYDRODISTENTION OF NON-HUNNER'S INTERSTITIAL CYSTITIS/BLADDER PAIN SYNDROME

Although AUA guidelines of IC/BPS did not include cystoscopic hydrodistention, the European Association of Urology (EAU) and Asian guidelines all recommend to use cystoscopic hydrodistention to add the diagnostic accuracy, and biopsy might be performed for histological confirmation [5-7]. The procedure should be undertaken under intravenous general anesthesia or spinal anesthesia. Normal saline is usually used as the infusate and the blood transfusion set is recommended [19,23]. The infusion rate

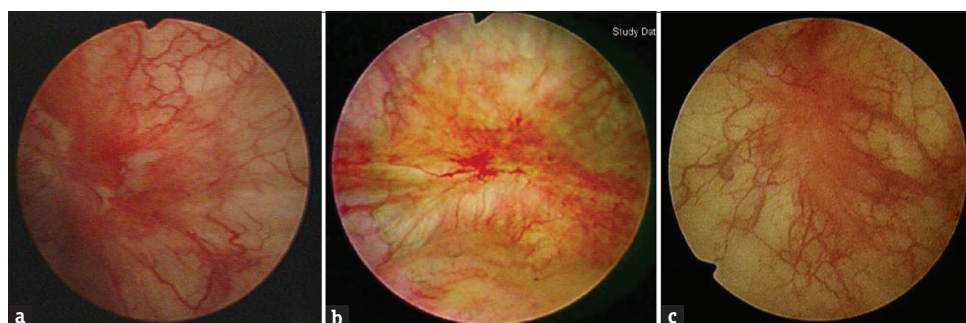


Figure 1: The characteristic Hunner's lesion under cystoscopic examination without anesthesia. The mucosa of Hunner's lesion is fragile and may have, (a) a central coagulum, (b) easy spotting during cystoscopic examination, and (c) erythematous patch with radiating vessels

should not be too rapid to avoid rapid bladder distention and causing bladder rupture. The ideal intravesical pressure is set at 80 cmH₂O, but recently a study using 40 cmH₂O is also reported feasible to detect glomerulations and measure the MBC [24]. It usually takes 10–15 min to reach the MBC. After the bladder infusion is nearly stopped, the bladder is slowly evacuated and cystoscopic observation of the bladder wall is performed [Figure 6]. In the NHIC/BPS bladder with glomerulations, small petechial hemorrhage appears, after half bladder capacity is decompressed, the glomerulations will become more prominent, some of the petechial will fuse to form a splotch hemorrhage, and in some bladders the rainfall

hemorrhage or mucosal crack is also noted [25] [Figure 7]. At this time, mucosal cracks or fissures may be observed. In HIC, the Hunner's lesions may be obscured by profuse bleeding, but some bladders will also have focal or diffuse glomerulations after hydrodistention. Currently, there has been no clear description and grading of the glomerulations and Hunner's lesion. Because the classification of IC/BPS has impact on the treatment strategy and associated with therapeutic outcome, it is unmet to have a clear definition and consensus on the characteristic cystoscopic findings of IC/BPS.

The role of cystoscopic hydrodistention has been a debatable issue in the diagnosis of IC/BPS. The clinical relevance of glomerulation in the IC/BPS phenotyping has also been discussed. The mechanism of glomerulation is likely to result from overexpression of angiogenetic growth factor and is associated with chronic inflammation [26]. Although the glomerulation grade did not correlate well with the histological finding, cystoscopic hydrodistention is still recommended to aid in the diagnosis of IC/BPS [27-29].

In asymptomatic normal bladder, there should be no submucosal hemorrhage after cystoscopic hydrodistention. However, some patients with lower urinary tract dysfunctions, such as urolithiasis, overactive bladder, bladder outlet obstruction, some will develop glomerulations after hydrodistention [23]. Some studies reported that the grade of glomerulation is not associated with symptom severity of IC/BPS. Therefore, glomerulations have been considered nonspecific for phenotype diagnosis of IC/BPS [30]. Nevertheless, development of glomerulations in patients with symptoms of bladder pain and frequency is still accepted as a final diagnosis of IC/BPS by the ESSIC and Asian guidelines [5,6].

During cystoscopic hydrodistention, a hyperemic change or hypervascularity have been observed in patients with IC/BPS, these patients are noted to have less favorable treatment outcome of intravesical therapy, and might not include in the diagnosis of IC/BPS [31]. Patients may have different grade of glomerulations after hydrodistention [19], namely grade 0–3, defined by the distribution of glomerulations at none (grade 0), <1/2 [Grade 1, Figure 8], more than 1/2 with mild petechial [Grade 2, Figure 9], and diffuse with profuse hemorrhage [Grade 3, Figure 10]. Some patients may also develop focal or diffuse mucosal fissures and rainfall bleeding or waterfall bleeding, of the bladder wall [Figure 7].

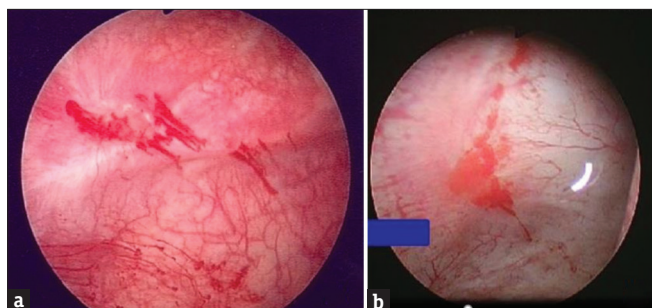


Figure 2: The characteristic Hunner's lesion under cystoscopic examination without anesthesia. There is, (a) scarring underneath the erythematous Hunner's lesion and, (b) radiating vessels centered at the fragile Hunner's lesion

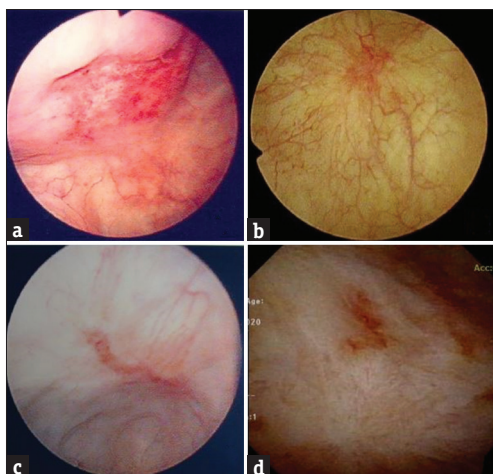


Figure 3: The cystoscopic presentation of Hunner's lesion is not uniform. Hunner's lesion could present with, (a) a dense inflammatory lesion with erosive mucosa, (b) an erythematous patch with radiating vessels, (c) a small scar with erythema and radiating vessels, and (d) a small denuded mucosal patch and focal thickening

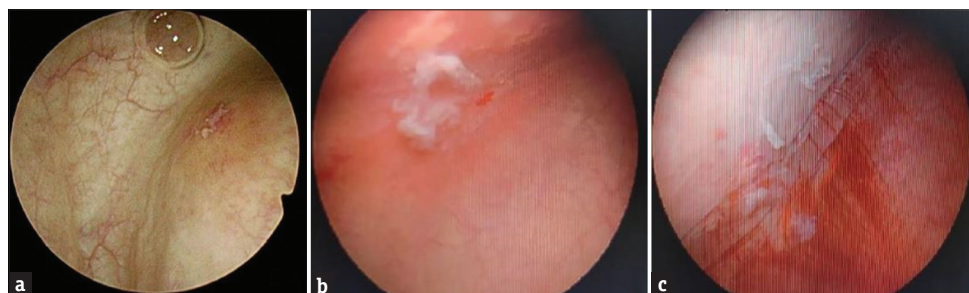


Figure 4: A woman with severe bladder pain and frequent urination. Cystoscopy without anesthesia revealed, (a) a small denuded mucosa and focal erythema, after cystoscopic hydrodistention under anesthesia, (b) the denuded mucosa widens with a central coagulum, and (c) several fissures and rainfall hemorrhage developed

In addition to glomerulations after hydrodistention, the MBC should also be measured. Bladder capacity had been found to have relationship with glomerulation grade and MBC after cystoscopic hydrodistention. MBC has been found

to closely associated with IC symptom severity and grade of glomerulations and might have more positive correlation with the severity of inflammation in the IC/BPS bladders [32]. Patients with NHIC who had a higher glomerulation grade had significantly high urinary MCP-1, IL-6, RANTES, 8-OHdG, and 8-isoprostane levels. A significant association was observed between urinary biomarkers and glomerulation grade, MBC, visual analogue scale score, and bladder sensation [33]. When we divided the bladder conditions into grade of glomerulations (≤ 1 , ≥ 2 , Hunner's lesion) and different MBC (<760 mL, ≥ 760 mL, Hunner's ulcer), we found significantly higher levels of several urine cytokines and chemokines, including monocyte chemoattractant protein-1, eotaxin, tumor necrosis factor-alpha, and prostaglandin E2 in the IC/BPS patients compared with the control 3 [17]. The increased glomerulation grade and decreased MBC are associated with chronic inflammation of IC/BPS bladders. Most urinary biomarkers were significantly associated with the decrease of MBC, increase of glomerulation grade, and the treatment outcome of IC/BPS.

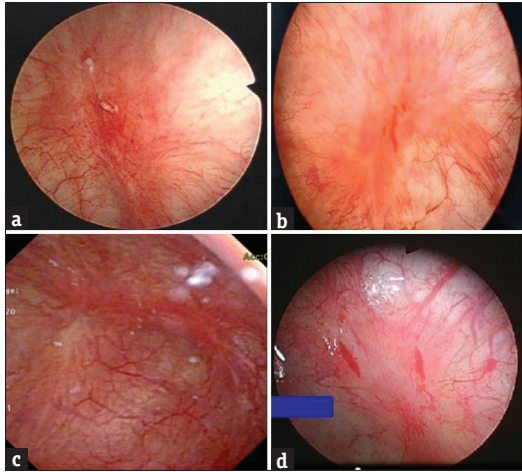


Figure 5: Characteristic cystoscopic findings of Hunner's lesion. The lesion is usually present with erythematous mucosa with, (a) central de-epithelialization, radiating vessels toward the center of lesion with coagulum, (b) central hemorrhage during cystoscopic distention, (c) focal chronic scarring of the surrounding bladder wall, or (d) denuded mucosa and diffuse bleeding

CYSTOSCOPIC FINDINGS AND HISTOPATHOLOGY OF INTERSTITIAL CYSTITIS/BLADDER PAIN SYNDROME

The association of glomerulation grade and histopathology

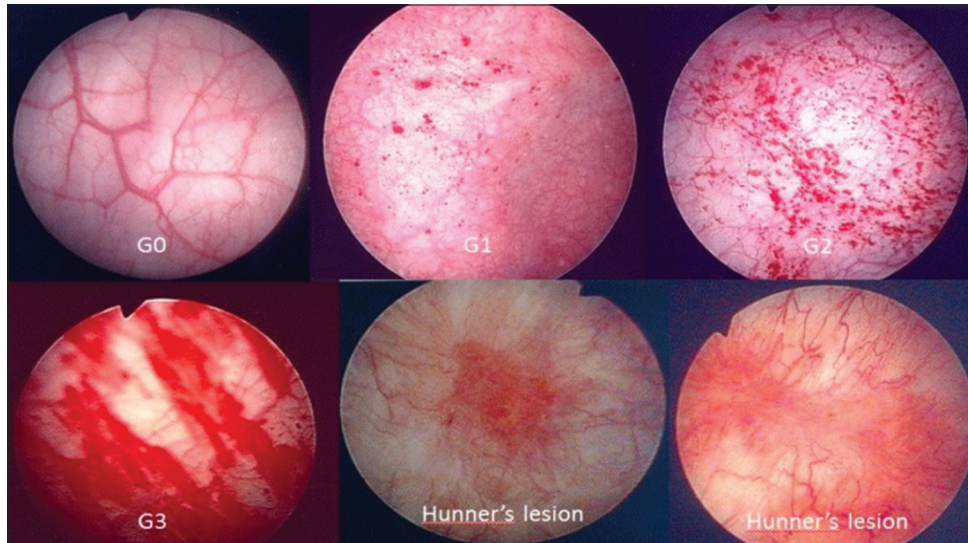


Figure 6: Cystoscopic hydrodistention in the bladder of interstitial cystitis, the bladder shows different appearance of mucosal lesion after decompression: G0: no any glomerulation, G1: grade 1 focal glomerulation, G2: grade 2 diffuse glomerulations, G3: splotch hemorrhage, and Hunner's lesions

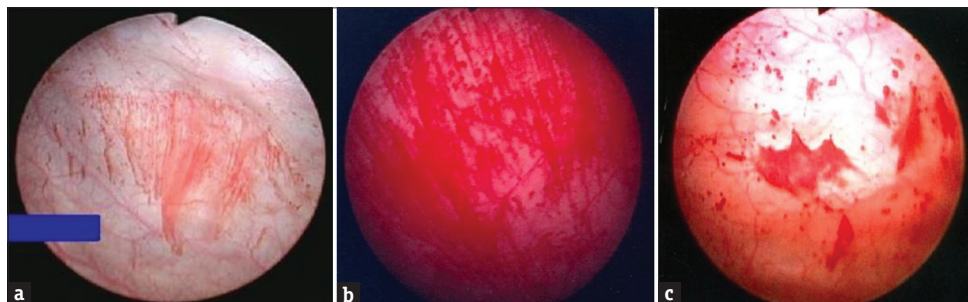


Figure 7: The characteristic bladder mucosal lesions develop after cystoscopic hydrodistention: (a) mucosal fissure and rainfall hemorrhage, (b) waterfall hemorrhage, (c) mucosal crack

Downloaded from http://journals.tcu.edu/centri by BNDM5ePHKav1ZEoum1IQIN4a+kLHEZgbsH04XMI0hCwCXA1AW nYOp/llQH33D00dRy/7TSF14C3VC1Y0abggQZxkgGj2MwZLEi= on 01/12/2024

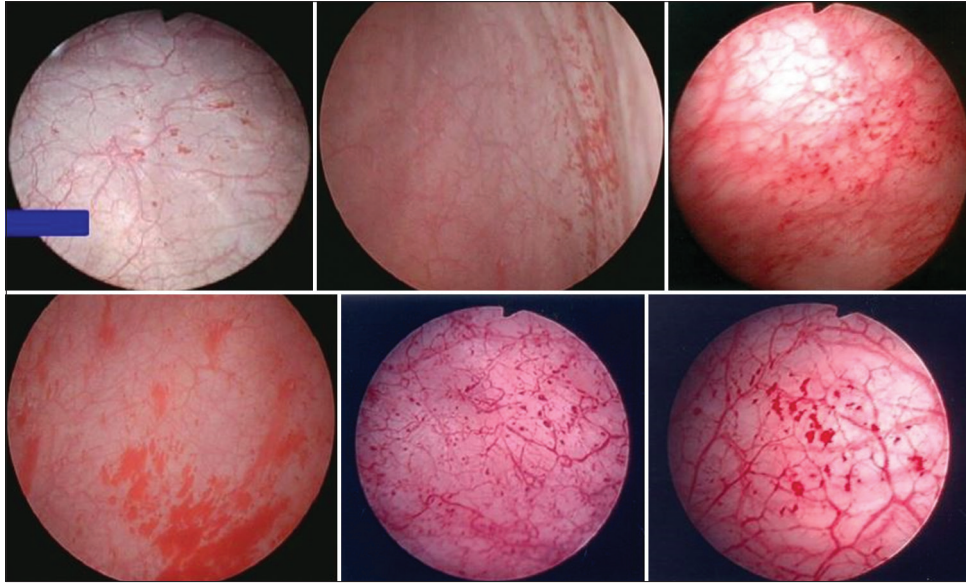


Figure 8: Grade 1 glomerulations develop after cystoscopic hydrodistention. The glomerulations appear focally and distributed at one or two quadrants of the bladder wall, no rainfall hemorrhage is noted

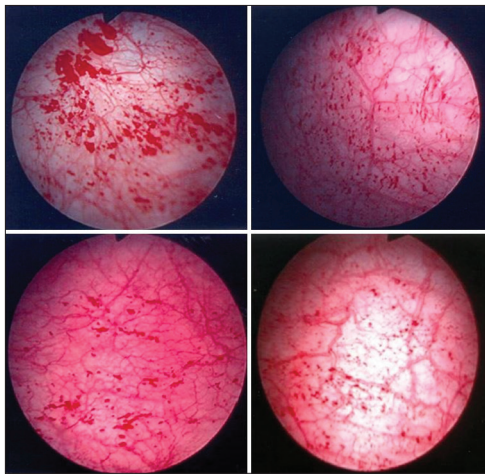


Figure 9: Grade 2 glomerulations develop after cystoscopic hydrodistention. The glomerulations appear diffusely and distributed at three or four quadrants of the bladder wall, no rainfall hemorrhage is noted

of IC/BPS has wide variation. HIC bladders have been found to have distinct suburothelial lymphoplasmacytic cell infiltration and microvessel density [13]. The inflammation in HIC is associated with HIF- α expression and related with ischemic change of the bladder [34]. However, the histopathological findings show no difference between NHIC bladders with and without glomerulations [35]. In analysis of the cytoskeleton and proliferation proteins of patients with HIC and different grade of glomerulations, we found that bladders of HIC and grade 3 glomerulation have lower expressions of CK20, tumor protein 63, and fibroblast growth factor, suggesting these two IC/BPS subtypes might have similar pathway that interfere the urothelial cell proliferation and maturation, resulting in a defective urothelial barrier and bladder pain [36].

CT of IC/BPS bladders revealed that patients may have a smooth bladder wall, focal thickening, or diffuse bladder wall

thickening [12]. Most HIC bladders exhibit focal or diffuse bladder wall thickening, and patients with focal or diffuse bladder wall thickening had a higher proportion of inflammatory cell infiltration, urothelial cell denudation, and granulation tissue [12] [Figure 11]. The bladder wall thickening indicates higher inflammatory histopathological changes and patients may have more severe clinical symptoms [12]. More IC/BPS patients who had a diffuse bladder wall thickening had mild to moderate or severe inflammatory cell infiltration, uroepithelial cell denudation, and granulation tissue in histopathological findings. Electron microscopic examination of IC/BPS bladders revealed moderate to severe defects of the urothelial cell layers and integrity of umbrella cells. The ultrastructural changes of the urothelium are associated with severity of bladder pain and small MBC [37,38].

DIFFERENTIAL DIAGNOSIS OF NONINTERSTITIAL CYSTITIS/BLADDER PAIN SYNDROME CYSTITIS

The cystoscopic findings of glomerulation or hemorrhage is not specific for IC/BPS, some patients with lower urinary tract dysfunction might also have similar glomerulation after hydrodistention, however the grade of glomerulations is usually lower in the patients without IC/BPS [23]. In clinical practice, patients might have lower urinary tract symptoms and bladder pain due to other bladder diseases and the cystoscopy revealed bladder mucosal lesions mimicking IC/BPS. These bladder diseases should be carefully differentiated from that of IC/BPS to avoid treatment in a different way. The commonly confused bladder diseases are ketamine cystitis, irradiation cystitis, acute bacterial cystitis, cystitis cystica, and catheter induced focal cystitis [Figure 12].

CLINICAL IMPLICATIONS OF GLOMERULATION AND MAXIMAL BLADDER CAPACITY IN INTERSTITIAL CYSTITIS/BLADDER PAIN SYNDROME

Cystoscopic hydrodistention can be a useful diagnostic

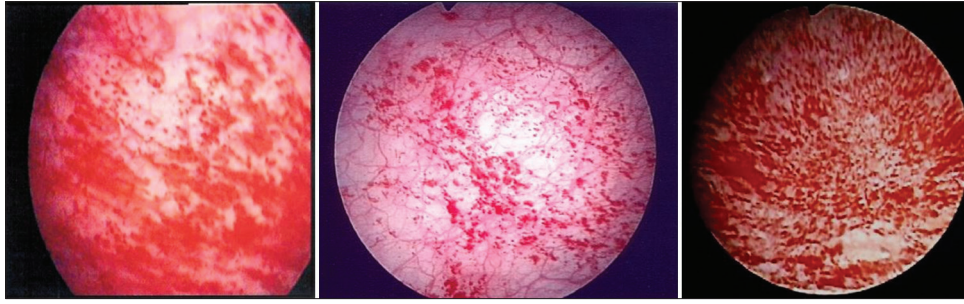


Figure 10: Grade 3 glomerulations develop after cystoscopic hydrodistention. The glomerulations appear diffusely and distributed at the whole bladder wall, sometimes splotch hemorrhage or rainfall hemorrhage is noted

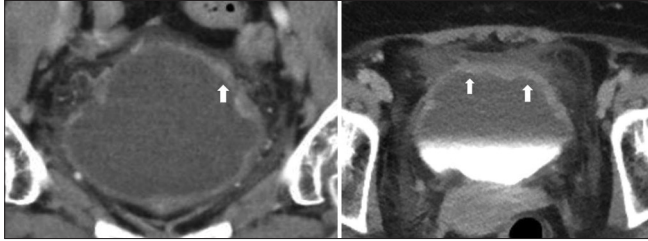


Figure 11: The computed tomography of the urinary bladder in a woman with Hunner's lesion showing diffuse thickening of the bladder wall (arrows). The thickened portions of the bladder wall are compatible with the Hunner's lesions appears in cystoscopy

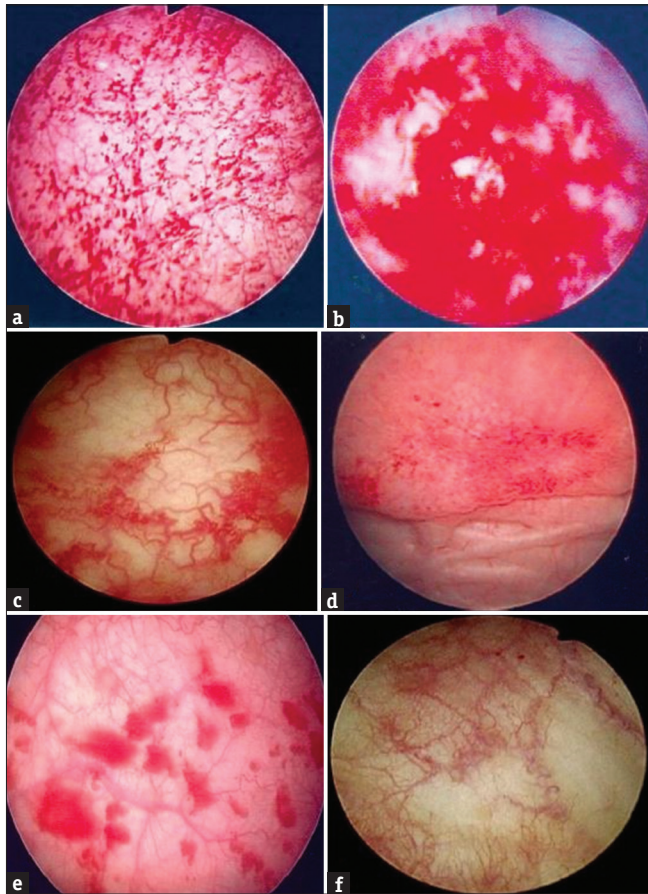


Figure 12: Cystoscopic findings in confusable bladder diseases mimicking interstitial cystitis: (a) ketamine cystitis, (b) chemical cystitis due to cyclophosphamide, (c) irradiation cystitis, (d) catheter effect mucosal erosion, (e) acute bacterial cystitis, (f) hyperemic bladder lesion

examination and also a treatment for IC/BPS [39]. The cystoscopic characteristics of IC/BPS after hydrodistention are associated with bladder symptoms, bladder wall CT finding, and histopathological findings in the bladder wall [Table 1]. Hydrodistention of the bladder has been reported to decrease pain postoperatively, regardless of the trigonal block or time of distention [39]. Previous study had shown that IC symptoms could be improved after a therapeutic cystoscopic hydrodistention; however, the symptoms would relapse with time pass by [40]. However, the bladder symptoms may relapse, therefore, multiple procedures are usually necessary in patients with IC/BPS and significant decreases in symptom scores after the procedure were observed on multiple questionnaires [41].

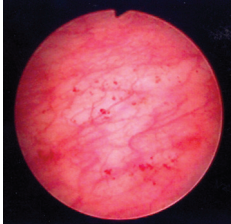
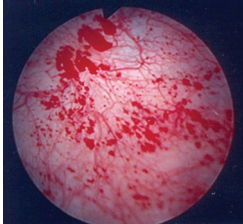

In addition to the presence or absence of glomerulation after hydrodistention, the MBC is also important in determining the bladder condition of IC/BPS. The IC/BPS bladders can be subtyped into different levels of MBC and glomerulation grades after cystoscopic hydrodistention [19]. Patients with low grade of glomerulation and higher MBC usually have a better treatment outcome with time. Interestingly, we also noted that these patients had more medical comorbidities, implying the factors contributing to their bladder pain and irritative symptoms might not completely originated from the urinary bladder but might be a result from outside the bladder.

In patients with intravesical treatment for IC/BPS, the glomerulations will also change in response to therapeutic success. After intravesical hyaluronic acid therapy, the changes of glomerulations are not prominent [42], but in patients with intravesical botulinum toxin injections or platelet-rich plasma injections, improvement of clinical symptoms is usually associated with the decrease of glomerulation grade and increase of MBC [43,44].

CONCLUSION

IC/BPS bladders have characteristic cystoscopic findings after hydrodistention. The presence of Hunner's lesions can be found under cystoscopy without anesthesia. Patients with NHIC might have different grade of glomerulation and MBC after hydrodistention. These cystoscopic findings are associated with severe bladder inflammation and clinical symptoms and also relate with the treatment outcome.

Table 1: The clinical and histopathological findings in patients with interstitial cystitis/bladder pain syndrome and different cystoscopic characteristics

	Grade 0–1 glomerulation	Grade 2–3 glomerulation	Presence of Hunner's lesion
Age [13]	Younger	Younger	Older
Clinical symptoms	Frequency urgency mild bladder pain	Frequency urgency moderate bladder pain	Frequency urgency severe bladder pain
CT scan of bladder wall thickening [2]	Smooth bladder wall	Some focal thickening	Focal or diffuse thickening
Cystoscopic hydrodistention[10,11,13-19]	None or focal (1/4 or \leq 1/2) glomerulations, small petechial hemorrhage after decompression Usually high MBC	Diffuse glomerulations, splotch hemorrhage, rainfall hemorrhage, mucosal cracks, MBC varied	Fragile mucosa central coagulum and easy spotting erythematous lesions and radiating vessels Small MBC
Histopathological finding*[36,37]			
Inflammatory cell infiltration (%)	Mild (61.4), moderate (7.1) severe (0.6)	Mild (61.4), moderate (7.1) severe (0.6)	Mild (46.7), moderate (26.7) severe (6.7)
Urothelial denudation (%)	Mild (36.5), moderate (6.5)	Mild (36.5), moderate (6.5)	Mild (46.7), moderate (20)
Eosinophil and plasma cell infiltration (%)	Presence (8.6)	Presence (8.6)	Presence (20)
Lamina propria hemorrhage (%)	Presence (14.5)	Presence (14.5)	Presence (33.3)
Granulation (%)	Presence (4.7)	Presence (4.7)	Presence (6.7)
Nerve hyperplasia (%)	Presence (3.9)	Presence (3.9)	Presence (33.3)
Figures of cystoscopic characteristics			

*The histopathological findings were not classified between glomerulations Grade 0–1 and Grade 2–3. MBC: Maximal bladder capacity after cystoscopic hydrodistention, CT: Computed tomography

Declaration of patient consent

The authors certify that they have obtained all appropriate patient consent forms. In the form the patients have given their consent for their images and other clinical information to be reported in the journal. The patients understand that their names and initials will not be published and due efforts will be made to conceal their identity, but anonymity cannot be guaranteed.

Data availability statement

Data sharing not applicable to this article as no datasets were generated or analyzed during the current study.

Financial support and sponsorship

This work was supported by Hualien Tzu Chi Hospital, Buddhist Tzu Chi Medical Foundation, Hualien, Taiwan, grant number: TCMF-SP 112–01.

Conflicts of interest

Dr. Yuan-Hong Jiang and Hann-Chorng Kuo, the editorial board members at *Tzu Chi Medical Journal*, had no roles in the peer review process of or decision to publish this article. The other authors declared no conflicts of interest in writing this paper.

REFERENCES

- Gohritz A, Dellon AL. Bladder pain syndrome/interstitial cystitis due to pudendal nerve compression: Described in 1915-A reminder for

treating pelvic pain a century later. *J Brachial Plex Peripher Nerve Inj* 2020;15:e5-8.

- Messing EM, Stamey TA. Interstitial cystitis: Early diagnosis, pathology, and treatment. *Urology* 1978;12:381-92.
- Clemens JQ, Erickson DR, Varela NP, Lai HH. Diagnosis and treatment of interstitial cystitis/bladder pain syndrome. *J Urol* 2022;208:34-42.
- Akiyama Y, Maeda D, Katoh H, Morikawa T, Niimi A, Nomiya A, et al. Molecular taxonomy of interstitial cystitis/bladder pain syndrome based on whole transcriptome profiling by next-generation RNA sequencing of bladder mucosal biopsies. *J Urol* 2019;202:290-300.
- Homma Y, Akiyama Y, Tomoe H, Furuta A, Ueda T, Maeda D, et al. Clinical guidelines for interstitial cystitis/bladder pain syndrome. *Int J Urol* 2020;27:578-89.
- van de Merwe JP, Nordling J, Bouchelouche P, Bouchelouche K, Cervigni M, Daha LK, et al. Diagnostic criteria, classification, and nomenclature for painful bladder syndrome/interstitial cystitis: An ESSIC proposal. *Eur Urol* 2008;53:60-7.
- Hanno PM, Burks DA, Clemens JQ, Dmochowski RR, Erickson D, Fitzgerald MP, et al. AUA guideline for the diagnosis and treatment of interstitial cystitis/bladder pain syndrome. *J Urol* 2011;185:2162-70.
- Kuo HC. Urodynamic study and potassium sensitivity test for women with frequency-urgency syndrome and interstitial cystitis. *Urol Int* 2003;71:61-5.
- Gillenwater JY, Wein AJ. Summary of the national institute of arthritis, diabetes, digestive and kidney diseases workshop on interstitial cystitis, national institutes of health, Bethesda, Maryland, August 28-29, 1987. *J Urol* 1988;140:203-6.
- Akiyama Y, Luo Y, Hanno PM, Maeda D, Homma Y. Interstitial cystitis/

- bladder pain syndrome: The evolving landscape, animal models and future perspectives. *Int J Urol* 2020;27:491-503.
11. Ronstrom C, Lai HH. Presenting an atlas of Hunner lesions in interstitial cystitis which can be identified with office cystoscopy. *Neurourol Urodyn* 2020;39:2394-400.
 12. Jhang JF, Hsu YH, Ho HC, Jiang YH, Lee CL, Yu WR, et al. Possible association between bladder wall morphological changes on computed tomography and bladder-centered interstitial cystitis/bladder pain syndrome. *Biomedicines* 2021;9:1306.
 13. Watanabe D, Akiyama Y, Niimi A, Nomiya A, Yamada Y, Sato Y, et al. Clinical characterization of interstitial cystitis/bladder pain syndrome in women based on the presence or absence of Hunner lesions and glomerulations. *Low Urin Tract Symptoms* 2021;13:139-43.
 14. Whitmore KE, Fall M, Sengiku A, Tomoe H, Logadottir Y, Kim YH. Hunner lesion versus non-Hunner lesion interstitial cystitis/bladder pain syndrome. *Int J Urol* 2019; 26(Suppl 1): 26-34.
 15. Koziol JA, Adams HP, Frutos A. Discrimination between the ulcerous and the nonulcerous forms of interstitial cystitis by noninvasive findings. *J Urol* 1996;155:87-90.
 16. Doiron RC, Tolls V, Irvine-Bird K, Kelly KL, Nickel JC. Clinical phenotyping does not differentiate Hunner lesion subtype of interstitial cystitis/bladder pain syndrome: A relook at the role of cystoscopy. *J Urol* 2016;196:1136-40.
 17. Yu WR, Jiang YH, Jhang JF, Kuo HC. Use of urinary cytokine and chemokine levels for identifying bladder conditions and predicting treatment outcomes in patients with interstitial cystitis/bladder pain syndrome. *Biomedicines* 2022;10:1149.
 18. Arlandis S, Bonillo MÁ, Franco A, Peri L, González-López R, Martínez-Cuenca E, et al. Cystoscopy in the assessment of patients with bladder pain syndrome: Results of a national multicenter observational study. *Arch Esp Urol* 2021;74:459-69.
 19. Yu WR, Jhang JF, Ho HC, Jiang YH, Lee CL, Hsu YH, et al. Cystoscopic hydrodistention characteristics provide clinical and long-term prognostic features of interstitial cystitis after treatment. *Sci Rep* 2021;11:455.
 20. Hillelsohn JH, Rais-Bahrami S, Friedlander JI, Okhunov Z, Kashan M, Rosen L, et al. Fulguration for Hunner ulcers: Long-term clinical outcomes. *J Urol* 2012;188:2238-41.
 21. Rofeim O, Hom D, Freid RM, Moldwin RM. Use of the neodymium: YAG laser for interstitial cystitis: A prospective study. *J Urol* 2001;166:134-6.
 22. Hanno PM, Erickson D, Moldwin R, Faraday MM, American Urological Association. Diagnosis and treatment of interstitial cystitis/bladder pain syndrome: AUA guideline amendment. *J Urol* 2015;193:1545-53.
 23. Jiang YH, Jhang JF, Kuo HC. Revisiting the role of potassium sensitivity testing and cystoscopic hydrodistention for the diagnosis of interstitial cystitis. *PLoS One* 2016;11:e0151692.
 24. Hsu LN, Tsai YS, Tong YC. Low-pressure hydrodistension induces bladder glomerulations in female patients with interstitial cystitis/bladder pain syndrome. *Neurourol Urodyn* 2022;41:296-305.
 25. Homma Y, Ueda T, Tomoe H, Lin AT, Kuo HC, Lee MH, et al. Clinical guidelines for interstitial cystitis and hypersensitive bladder syndrome. *Int J Urol* 2009;16:597-615.
 26. Tamaki M, Saito R, Ogawa O, Yoshimura N, Ueda T. Possible mechanisms inducing glomerulations in interstitial cystitis: Relationship between endoscopic findings and expression of angiogenic growth factors. *J Urol* 2004;172:945-8.
 27. Denson MA, Griebing TL, Cohen MB, Kreder KJ. Comparison of cystoscopic and histological findings in patients with suspected interstitial cystitis. *J Urol* 2000;164:1908-11.
 28. Proaño A, Garde G, Garrido G, Mazza O. ESSIC criteria for the diagnosis of bladder pain syndrome/interstitial cystitis (BPS/IC) and comparison with the NIDDK criteria. *Arch Esp Urol* 2013;66:206-14.
 29. Morlacco A, Mancini M, Soligo M, Zattoni F, Calpista A, Vizzielli G, et al. Relevance of the endoscopic evaluation in the diagnosis of bladder pain syndrome/interstitial cystitis. *Urology* 2020;144:106-10.
 30. Wennevik GE, Meijlink JM, Hanno P, Nordling J. The role of glomerulations in bladder pain syndrome: A review. *J Urol* 2016;195:19-25.
 31. Erol B, Kazan HO, Keser F, Efiloglu O, Danacioğlu YO, Onur R. Effect of focal and diffuse hypervascularization as cystoscopic findings on predicting intravesical therapy response in patients with bladder pain syndrome. *Turk J Urol* 2021;47:325-37.
 32. Kuo YC, Kuo HC. The urodynamic characteristics and prognostic factors of patients with interstitial cystitis/bladder pain syndrome. *Int J Clin Pract* 2013;67:863-9.
 33. Jiang YH, Jhang JF, Hsu YH, Kuo HC. Usefulness of urinary biomarkers for assessing bladder condition and histopathology in patients with interstitial cystitis/bladder pain syndrome. *Int J Mol Sci* 2022;23:12044.
 34. Akiyama Y, Miyakawa J, O'Donnell MA, Kreder KJ, Luo Y, Maeda D, et al. Overexpression of HIF1 α in Hunner lesions of interstitial cystitis: Pathophysiological implications. *J Urol* 2022;207:635-46.
 35. Akiyama Y, Hanno P. Phenotyping of interstitial cystitis/bladder pain syndrome. *Int J Urol* 2019; 26(Suppl 1): 17-9.
 36. Jhang JF, Jiang YH, Hsu YH, Ho HC, Kuo HC. Decreased urothelial cytoskeleton and cell proliferation protein expression suggest interstitial cystitis/bladder pain syndrome patients with Hunner's lesion and grade 3 glomerulation might be different from other types of patients. *Int J Urol* 2021;28:823-30.
 37. Jhang JF, Ho HC, Jiang YH, Lee CL, Hsu YH, Kuo HC. Electron microscopic characteristics of interstitial cystitis/bladder pain syndrome and their association with clinical condition. *PLoS One* 2018;13:e0198816.
 38. Lee YK, Jhang JF, Jiang YH, Hsu YH, Ho HC, Kuo HC. Difference in electron microscopic findings among interstitial cystitis/bladder pain syndrome with distinct clinical and cystoscopic characteristics. *Sci Rep* 2021;11:17258.
 39. Hoke TP, Goldstein H, Saks EK, Vakili B. Hydrodistention of the bladder for the treatment of bladder pain syndrome/interstitial cystitis (BPS/IC). *Neurourol Urodyn* 2017;36:784-6.
 40. Inoue R, Takahashi S, Sunaoshi K, Ichihara K, Masumori N, Tsukamoto T. Hydrodistention of the bladder in patients with interstitial cystitis – Clinical efficacy and its association with immunohistochemical findings for bladder tissues. *Hinyokika Kyo* 2006;52:765-8.
 41. Kirk PS, Santiago-Lastra Y, Qin Y, Stoffel JT, Clemens JQ, Cameron AP. The effects of cystoscopy and hydrodistention on symptoms and bladder capacity in interstitial cystitis/bladder pain syndrome. *Neurourol Urodyn* 2018;37:2002-7.
 42. Lin CJ, Liu CK, Hsieh HY, Chen MJ, Tsai CP. Changes in cystoscopic findings after intravesical hyaluronic acid instillation therapy in patients with interstitial cystitis. *Diagnostics (Basel)* 2022;12:2009.
 43. Shie JH, Liu HT, Wang YS, Kuo HC. Immunohistochemical evidence suggests repeated intravesical application of botulinum toxin A injections may improve treatment efficacy of interstitial cystitis/bladder pain syndrome. *BJU Int* 2013;111:638-46.
 44. Jhang JF, Lin TY, Kuo HC. Intravesical injections of platelet-rich plasma is effective and safe in treatment of interstitial cystitis refractory to conventional treatment—a prospective clinical trial. *Neurourol Urodyn* 2019;38:703-9.