



## Original Article

# An innovation percutaneous needle knife use for trigger finger: A retrospective cohort study

Bharath Kumar Velmurugan<sup>a</sup>, Chih-Yang Huang<sup>a,b,c,d,e</sup>, Dah-Ching Ding<sup>f,g</sup>, Kun-Chi Wu<sup>h\*</sup>

<sup>a</sup>Department of Medical Laboratory Science and Biotechnology, Asia University, Taichung, Taiwan, <sup>b</sup>Graduate Institute of Biomedical Sciences, China Medical University, Taichung, Taiwan, <sup>c</sup>Cardiovascular and Mitochondrial Related Disease Research Center, Hualien Tzu Chi Hospital, Buddhist Tzu Chi Medical Foundation, Hualien, Taiwan, <sup>d</sup>Center of General Education, Buddhist Tzu Chi Medical Foundation, Tzu Chi University of Science and Technology, Hualien, Taiwan, <sup>e</sup>Department of Medical Research, China Medical University Hospital, China Medical University, Taichung, Taiwan, <sup>f</sup>Department of Obstetrics and Gynecology, Hualien Tzu Chi Hospital, Buddhist Tzu Chi Foundation and Tzu Chi University, Hualien, Taiwan, <sup>g</sup>Institute of Medical Sciences, Tzu Chi University, Hualien, Taiwan, <sup>h</sup>Department of Orthopedics, Hualien Tzu Chi Hospital, Buddhist Tzu Chi Medical Foundation and Tzu Chi University, Hualien, Taiwan

Submission : 05-Oct-2022  
Revision : 08-Nov-2022  
Acceptance : 17-Jan-2023  
Web Publication : 02-May-2023

## ABSTRACT

**Objectives:** This study retrospectively evaluated the effectiveness of percutaneous pulley release by our newly designed needle knife in terms of cure, relapse, and complication rates. **Materials and Methods:** Two hundred and fifty-seven patients were allocated into male and female groups between October 2014 and September 2021. We included patients >15 years of age with a trigger finger (TF) (types II–VI). The primary outcome was the absence of a TF and pain-free movement. In contrast, the secondary outcome included second-time surgery and the number of complications such as infection and admission for antibiotics. **Results:** One hundred patients were male, and 157 patients were female. Males and females had mean ages of  $62.45 \pm 11.76$  and  $61.50 \pm 8.57$  years, respectively. The operative time was significantly longer in males than in females ( $7.88 \pm 6.02$  vs.  $6.52 \pm 3.74$  min in males and females, respectively,  $P = 0.027$ ). However, the percentages of diabetes mellitus and gout were the same in both groups. For the percutaneous methods with our needle knife, remission of the trigger was achieved in all cases. In addition, seven patients received revision and three patients with complications. After needle surgery, topical and joint pain scores were improved in both groups (from  $5.09 \pm 1.31$  to  $0.80 \pm 1.56$ ). **Conclusion:** The percutaneous methods with our needle knife displayed effectiveness. The cure rate was high, and the relapse rate was low. Further large-scale clinical trials comparing percutaneous needle to open surgery for releasing the TF will be needed to confirm our results.

**KEYWORDS:** Cohort, Needle knife, Surgery, Tendon entrapment, Trigger finger

## INTRODUCTION

Discomforts are experienced by individuals suffering from trigger finger (TF) during finger movements, with some having joint excursion. Triggering is a way of triggering the finger, which describes the sudden catching and release occurring during the movement of the fingers. It is a disorder that can occur in adults (prevalence 2.5% in nondiabetic adults) and children (prevalence <0.05%) [1,2]. The first annular (A1) pulley is where the main triggering occurs, followed by compression and long-term friction obstructing

the flexor tendon to glide in the fibrous sheath involving the thumb [3]. There have been various proven effective treatments (percutaneous needle [PN] release under local anesthesia with a 93% success rate, corticosteroid injections, and nonsteroidal anti-inflammatory drugs with an 85% success rate) to overcome this painful condition [4,5]. However,


\*Address for correspondence: Dr. Kun-Chi Wu,

Department of Orthopedics, Hualien Tzu Chi Hospital, Buddhist Tzu Chi Medical Foundation, 707, Section 3, Chung-Yang Road, Hualien, Taiwan.  
E-mail: drwukunchi@yahoo.com.tw

This is an open access journal, and articles are distributed under the terms of the Creative Commons Attribution-NonCommercial-ShareAlike 4.0 License, which allows others to remix, tweak, and build upon the work non-commercially, as long as appropriate credit is given and the new creations are licensed under the identical terms.

For reprints contact: WKHLRPMedknow\_reprints@wolterskluwer.com

**How to cite this article:** Velmurugan BK, Huang CY, Ding DC, Wu KC. An innovation percutaneous needle knife use for trigger finger: A retrospective cohort study. Tzu Chi Med J 2023;35(3):242-6.

Access this article online	
<b>Quick Response Code:</b> 	<b>Website:</b> www.tcmjmed.com
	<b>DOI:</b> 10.4103/tcmj.tcmj_277_22

all cases could only be resolved partially [4,5]. The overall success rate ranges from 35% to 85% in the decrease in pain and triggering after corticosteroid injection [6]. Surgery remains the only option to relieve the A1 pulley when other essential treatments fail with high success and satisfaction rates but are often associated with complications such as digital nerve, artery injury, contracture, and infection [7].

Physical and subjective observations are the main clinical diagnosis examinations. It is also possible to diagnose the TF with ultrasound [8]. The typical ultrasonic feature of the TF is nodular or global hypoechoic thickening of the A1 pulley [8]. The severity of TF is divided into four grades as proposed by Froimson [9], where Grade I gives tenderness to the metacarpophalangeal joint of the palm in hand; Grade II can extend the triggering and flex actively; Grade III triggers but is unable to extend or flex; and Grade IV shows joint contracture issues [10]. High success rates are associated with open trigger release. It has a low morbidity and should be considered the standard operative procedure [11]. First described by Lorthioir in 1958, percutaneous trigger release has become increasingly popular recently as an alternative to open release [12]. Merits of this procedure include decreased pain, quick recovery, lack of palmar scar, and cost reduction [13,14]. Designer hypodermic needles for the procedure are used, but some reports use blades or scalpels [15-17]. Using a fine tenotome to treat TF has become popular among patients [18]. Still, more advanced and suitable tools are required when triggering is high, and nodules are present, for which high-resolution instruments are required. Previous studies revealed several shortages of needles to release TFs [19]. Usually, the needle size is 19 gauge and is connected to the syringe. The disadvantages of such needle include poor handling, the needle breaking at the surgical site, and insufficient strength to cut the pulley.

Therefore, we designed a novel needle knife to conquer the shortage of needles. In this study, we used our newly developed needle knife to perform the minimally invasive procedure for the release TF.

## MATERIALS AND METHODS

### Ethics

Ethical approval for this study was provided by the Research Ethical Committee of Hualien Tzu Chi Hospital. The approval no. was IRB111-077-B. The Research Ethical Committee of Hualien Tzu Chi Hospital waived the written informed consent because of the low risk to patient safety.

### Study period

A retrospective cohort study was conducted from October 2014 to September 2021. Two hundred and sixty-two patients with TFs, finger pain, and clumped fingers were recruited for the study population. In addition, those with recurrent TFs or infections ( $n = 5$ ) were excluded from the study. Finally, 257 patients were included in the study. The demographic division includes gender, age, lesion site, grade of severity, and past medical history (gout and diabetes mellitus [DM]) [Figure 1].

The primary outcome was the absence of a TF and pain-free movement. However, the secondary outcome

included second-time surgery and several complications such as infection and admission for antibiotics. The study design included the Quinell grading system used to evaluate the preoperative status. In addition, the pain in the wound, digital nerve injured, flexor tendon injured bowstringing, recurrent TF, stiffness, scar formation, and patient satisfaction was compared.

### The design of the needle knife

Figure 2a is a perspective exploded view illustrating the preferred embodiment of the TF scalpel; Figure 2b is a partial cross-sectional side view illustrating the preferred embodiment, and Figure 2c is the preferred embodiment in operation.

### The surgical procedure of percutaneous release for trigger finger

This procedure uses a needle through the skin to treat the affected tendon sheath, and research suggests that this procedure has results similar to open surgery [20,21]. The procedure is as follows:

- Disinfection of the patient and surgeon's hands is required, and the touching area needs a local anesthetic, typically lidocaine [Figure 3a]
- The surgeon's finger palpation guides the needle toward the affected tendon sheath to avoid tendon or nearby nerve damage. A patent needle knife was used for this procedure
- The knife broke the constricting tissue around the tendon sheath [Figure 3b]. After locating the A1 pulley, a needle knife was inserted through the A1 pulley and into the flexor tendon. A sweeping motion of the needle knife on the A1 pulley was used to divide the A1 pulley longitudinally. The disappearance of a gating sound and active range of motion could be confirmed as fully releasing TF
- As no incisions are made, stitches are not required after the procedure [Figure 3c].

### Statistical analysis

The Chi-square test was used to test the difference in the distribution of the categorical variables between the two

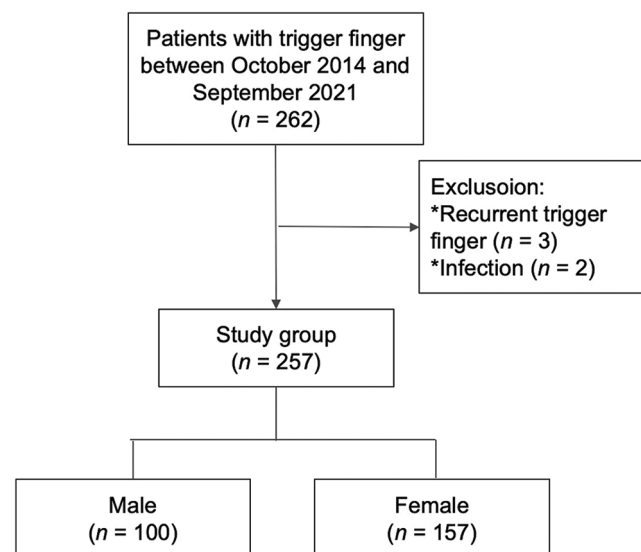
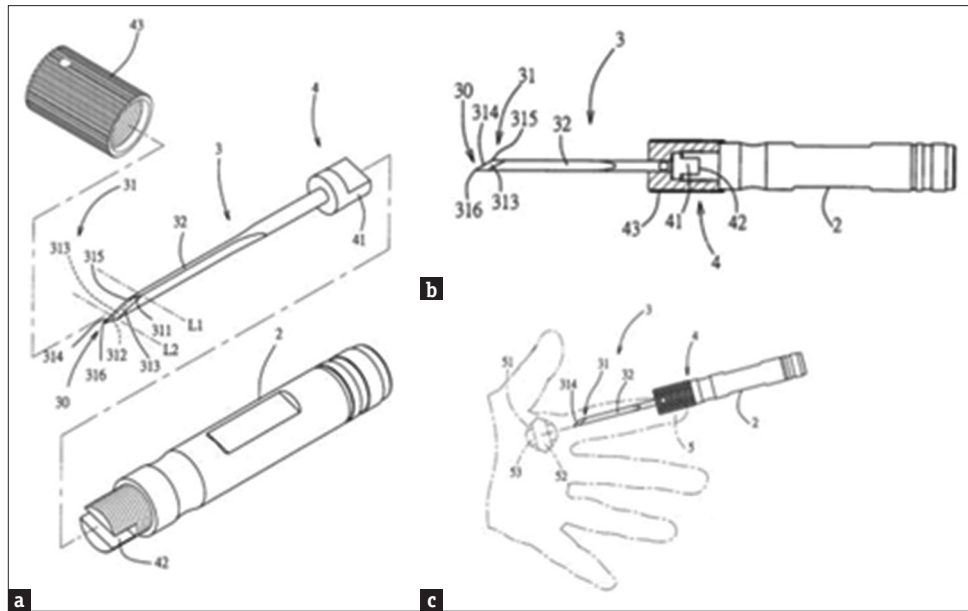
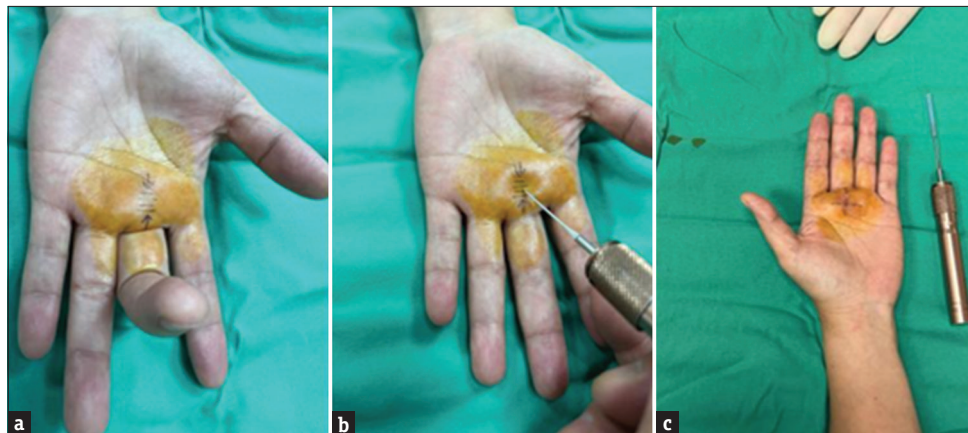


Figure 1: Study design



**Figure 2:** The design of the needle knife for the trigger finger. (a) Respective modules of the knife: 2, holder; 3, blade; 4, connecting device; 5, finger. (b) The complete device. (c) The use of the knife to release the trigger finger



**Figure 3:** Percutaneous release for trigger finger by our uniquely designed and patented needle knife. (a) A1 pulley localization, (b) percutaneous release, (c) cutting completion

groups, and the Student’s *t*-test assessed the difference in numerical variables. All statistical analyses were performed by SPSS (version 24.0, IBM, NY, USA). All statistical significances were set at a *P* < 0.05.

**RESULTS**

**Patient characteristics**

The demographic data of patients who received needle knife surgery are listed in Table 1. The previous study showed the incidence of TFs in women more in men [22]. Our study also found more women than men in our cohort (157 vs. 100) [Table 1]. The mean ages of males and females were 62.45 ± 11.76 and 61.50 ± 8.57 years, respectively [Table 1]. The two groups were homogenous regarding age and operative time [Table 1]. The data containing the age, percentage of DM and gout, different types of TF, revision, and complications are shown in Table 1.

**Table 1: Demographic (n=257)**

	Gender		Total, n (%)	P
	Male, n (%)	Female, n (%)		
n	100	157	257	
Age	62.45±11.76	61.50±8.57	61.87±9.93	0.455
Operative time (min)	7.88±6.01	6.52±3.74	7.05±4.78	0.027*
DM	5 (5.0)	8 (5.1)	13 (5.1)	0.973
Gout	1 (1.0)	0	1 (0.4)	0.389
Type	-	-	-	1.000
II	4 (4.0)	6 (3.8)	10 (3.9)	
III	43 (43.0)	67 (42.7)	110 (42.8)	
IV	47 (47.0)	75 (47.8)	122 (47.5)	
V	1 (1.0)	2 (1.3)	3 (1.2)	
VI	5 (5.0)	7 (4.5)	12 (4.7)	
Revision	2 (2.0)	5 (3.2)	7 (2.7)	0.709
Complication	3 (3.0)	0	3 (1.2)	0.058

\**P*<0.05 was considered statistically significant after test. Data are presented as n (%) or mean±SD. DM: Diabetes mellitus, SD: Standard deviation

## Treatment for trigger finger

The operative time of female patients was significantly shorter than that of male patients [ $6.52 \pm 3.74$  vs.  $7.88 \pm 6.01$  min,  $P < 0.027$ , Table 1]. No difference was noted in the comorbidities such as DM and gout and different types of TF [Table 1].

## Revision

Revisions were found in 2.7% of the total cases [Table 1].

## Complications

There was a complication in 3% of the male cases of TF [Table 1].

## Topical and joint pain

The number of patients experiencing topical and joint pain was statistically lower in both the sexes [Table 2].

## DISCUSSION

In our study, we found no difference in the comorbidities such as DM and gout and different types of TF between the two groups. The operative time was significantly shorter in female patients than in male patients. The topical and joint pain showed no difference between the two groups. However, the pain score improved a lot after surgery. Our knife design, surgery for mini-percutaneous release of the TF, is more feasible for outpatient surgery. The procedure during outpatient department (OPD) is practical, straightforward, and time-saving.

However, all physicians must be trained or choose to use this device during this procedure [23]. Compared to open surgery, percutaneous release is less popular due to the obvious ones, as the former offers the surgeon a clear picture of the affected tissues [23]. In addition, most physicians opined that percutaneous release might have increased damage to the unseen tissue along with the nearby nerves, which are present may be a 2-mm or 3-mm distance from the affected tendon [24]. The likelihood of nerve and tendon damage is less when a trained physician conducts this needle procedure [23]. Recovery time for percutaneous release is shorter than open surgery giving the patients to resume work sooner [21].

Percutaneous sonographically guided release of the TF is a good option to prevent injury to the digital artery, nerve, and tendon [23,25,26]. A shorter recovery time allows patients to move and rehabilitate earlier and avoid postoperative contractures [26]. In our practice, patients must avoid touching water for 1 day after needle knife surgery. After needle knife surgeries, the finger movements become flexible. After needle

and knife surgeries, no particular rehabilitation program was required.

The operative time of female patients was significantly shorter than that of male patients ( $6.52 \pm 3.74$  vs.  $7.88 \pm 6.01$  min,  $P < 0.027$ ), which is time-saving compared to the open method provided with local anesthesia alone, which in the open method requires general anesthesia [Table 1]. Furthermore, the previous study showed a shorter operative time in blind needle surgery than in ultrasound-guided needle surgery ( $5.23 \pm 0.55$  min vs.  $15.21 \pm 0.87$  min,  $P < 0.05$ ) [23]. Therefore, the operative time of blind needle surgery was comparable to that in our study. Regarding shorter operative time in females than males, stronger tissue strength and bigger palm size in males might cause a longer operative time.

However, differences were not found for DM and gout comorbidities with different types of TF [Table 1]. A 2.7% revision rate was found for all cases, and the complication rate was 3% in males, as shown in Table 1. A statistically lower number of patients experienced topical and joint pain for both sexes [Table 2].

Percutaneous micro-release is comparatively more useful for the surgery outpatients. TF can be treated in clinics or OPD with local treatment. However, due to lack of equipment most clinics refer these patients to to big hospitals or medical centers, where general anesthesia will be given. Therefore, the current instrument might be useful to promote such micro-release surgery performed in clinics or OPD and reduce patient crowding in big hospitals.

Before the PN method, 100% of the patients required hospitalization for at least 1 day in our hospital. However, a previous study showed that open surgery could be an outpatient basis surgery [27]. Furthermore, the open surgery method also required antibiotics, and stitches were removed 1 week later. In contrast, using the PN method, 90% of the patients do not require hospitalization and are far away from stitches removal or other OPD surgery risks such as infection, surgical experience, and needle fracture [25]. Thus, the PN method, as reported in this study, may be 100% comparable to OPD surgery, which is simple, effective, and helps the patients resume work rather quickly.

## CONCLUSIONS

Percutaneous release for the TF is an easy and effective safe method compared to open surgery. This novel needle knife surgery resolved the problems encountered by old needle surgery, such as being easily broken, having less strength to cut the pulley, and not easily handling the needle. Further large-scale clinical trials comparing needle knife surgery to open surgery for releasing the TF will be needed to confirm our results.

## Data availability statement

The datasets generated during and/or analyzed during the current study are not publicly available due to the data generated using the hospital electric chart but are available from the corresponding author on reasonable request.

**Table 2: Distribution of topical and joint pain at 1 week (n=257)**

	Gender		Total	P
	Male	Female		
n	100	157	257	
1 week				
Topical pain (VAS)	5.11±1.36	5.08±1.29	5.09±1.31	0.870
Joint pain (VAS)	0.85±1.77	0.77±1.41	0.80±1.56	0.691

Data are presented as n (%) or mean±SD. VAS: Visual Analog Scale, SD: Standard deviation



**Financial support and sponsorship**

Nil.

**Conflicts of interest**

Dr. Dah-Ching Ding, an editorial board member at *Tzu Chi Medical Journal*, had no role in the peer review process of or decision to publish this article. The other authors declared no conflicts of interest in writing this paper.

**REFERENCES**

1. Womack ME, Ryan JC, Shillingford-Cole V, Speicher S, Hogue GD. Treatment of paediatric trigger finger: A systematic review and treatment algorithm. *J Child Orthop* 2018;12:209-17.
2. Makkouk AH, Oetgen ME, Swigart CR, Dodds SD. Trigger finger: Etiology, evaluation, and treatment. *Curr Rev Musculoskelet Med* 2008;1:92-6.
3. Saldana MJ. Trigger digits: Diagnosis and treatment. *J Am Acad Orthop Surg* 2001;9:246-52.
4. Jiménez I, Garcés GL, Marcos-García A, Medina J. A randomized controlled trial of dorsal web space versus palmar midline injection of steroid in the treatment of trigger digits. *J Hand Surg Eur Vol* 2020;45:1071-7.
5. Blumberg N, Arbel R, Dekel S. Percutaneous release of trigger digits. *J Hand Surg Br* 2001;26:256-7.
6. Chang CJ, Chang SP, Kao LT, Tai TW, Jou IM. A meta-analysis of corticosteroid injection for trigger digits among patients with diabetes. *Orthopedics* 2018;41:e8-14.
7. Lin FY, Manrique OJ, Lin CL, Cheng HT. Incidence of trigger digits following carpal tunnel release: A nationwide, population-based retrospective cohort study. *Medicine (Baltimore)* 2017;96:e7355.
8. Bianchi S, Gitto S, Draghi F. Ultrasound features of trigger finger: Review of the literature. *J Ultrasound Med* 2019;38:3141-54.
9. Froimson AI. Tenosynovitis and tennis elbow. In: Green DP, editor. *Operative hand surgery*. New York: Churchill Livingstone; 1993, p. 1989-2006.
10. Lu SC, Kuo LC, Hsu HY, Jou IM, Sun YN, Su FC. Finger movement function after ultrasound-guided percutaneous pulley release for trigger finger: Effects of postoperative rehabilitation. *Arch Phys Med Rehabil* 2015;96:91-7.
11. Fowler JR, Baratz ME. Percutaneous trigger finger release. *J Hand Surg Am* 2013;38:2005-8.
12. Lorthioir J Jr. Surgical treatment of trigger-finger by a subcutaneous method. *J Bone Joint Surg Am* 1958;40-A: 793-5.
13. Calleja H, Tanchuling A, Alagar D, Tapia C, Macalalad A. Anatomic outcome of percutaneous release among patients with trigger finger. *J Hand Surg Am* 2010;35:1671-4.
14. Eastwood DM, Gupta KJ, Johnson DP. Percutaneous release of the trigger finger: An office procedure. *J Hand Surg Am* 1992;17:114-7.
15. Bamroongshawgasame T. A comparison of open and percutaneous pulley release in trigger digits. *J Med Assoc Thai* 2010;93:199-204.
16. Chao M, Wu S, Yan T. The effect of miniscalpel-needle versus steroid injection for trigger thumb release. *J Hand Surg Eur Vol* 2009;34:522-5.
17. Dierks U, Hoffmann R, Meek MF. Open versus percutaneous release of the A1-pulley for stenosing tendovaginitis: A prospective randomized trial. *Tech Hand Up Extrem Surg* 2008;12:183-7.
18. Zyluk A, Mosiejczuk H. Outcomes of the treatment of trigger digits by extracorporeal shock wave therapy (ESWT). *Handchir Mikrochir Plast Chir* 2020;52:25-8.
19. Cebesoy O, Kose KC, Baltaci ET, Isik M. Percutaneous release of the trigger thumb: Is it safe, cheap and effective? *Int Orthop* 2007;31:345-9.
20. Amirfeyz R, McNinch R, Watts A, Rodrigues J, Davis TR, Glassey N, et al. Evidence-based management of adult trigger digits. *J Hand Surg Eur Vol* 2017;42:473-80.
21. Fiorini HJ, Tamaoki MJ, Lenza M, Gomes Dos Santos JB, Faloppa F, Belloti JC. Surgery for trigger finger. *Cochrane Database Syst Rev* 2018;2:CD009860.
22. Lee YK, Kam BS, Lee KW, Kim WJ, Choy WS. Ten trigger fingers in an adult man: A case report. *J Korean Med Sci* 2007;22:170-2.
23. Pan M, Sheng S, Fan Z, Lu H, Yang H, Yan F, et al. Ultrasound-guided percutaneous release of A1 pulley by using a needle knife: A prospective study of 41 cases. *Front Pharmacol* 2019;10:267.
24. Marij Z, Aurangzeb Q, Rizwan HR, Haroon R, Pervaiz MH. Outpatient percutaneous release of trigger finger: A cost effective and safe procedure. *Malays Orthop J* 2017;11:52-6.
25. Nikolaou VS, Malahias MA, Kaseta MK, Sourlas I, Babis GC. Comparative clinical study of ultrasound-guided A1 pulley release versus open surgical intervention in the treatment of trigger finger. *World J Orthop* 2017;8:163-9.
26. Lapègue F, André A, Meyrignac O, Pasquier-Bernachot E, Dupré P, Brun C, et al. US-guided percutaneous release of the trigger finger by using a 21-gauge needle: A prospective study of 60 Cases. *Radiology* 2016;280:493-9.
27. Lin CJ, Huang HK, Wang ST, Huang YC, Liu CL, Wang JP. Open versus percutaneous release for trigger digits: Reversal between short-term and long-term outcomes. *J Chin Med Assoc* 2016;79:340-4.