



Original Article

Clinical outcomes of benign brain tumors treated with single fraction LINAC-based stereotactic radiosurgery: Experience of a single institute

Chia-Hui Chew^{a†}, Jin-Cherng Chen^{b†}, Shih-Kai Hung^{a, c}, Tsung-Hsien Wu^b, Moon-Sing Lee^{a, c}, Wen-Yen Chiou^{a, c}, Liang-Cheng Chen^{a, c}, Hon-Yi Lin^{a, c, d*}

^aDepartment of Radiation Oncology, Dalin Tzu Chi Hospital, Buddhist Tzu Chi Medical Foundation, Chiayi, Taiwan, ^bDepartment of Neurosurgery, Dalin Tzu Chi Hospital, Buddhist Tzu Chi Medical Foundation, Chiayi, Taiwan, ^cSchool of Medicine, Tzu Chi University, Hualien, Taiwan, ^dInstitute of Molecular Biology, National Chung Cheng University, Chiayi, Taiwan

[†]Both authors contributed equally to this work.

ABSTRACT

Objectives: Accelerator-based stereotactic radiosurgery (SRS) is a noninvasive and effective treatment modality widely used for benign brain tumors. This study aims to report 20-year treatment outcomes in our institute. **Materials and Methods:** From May 2001 to December 2020, 127 patients treated with LINAC-based single-fraction SRS for their benign brain lesions were included. A neurosurgeon and two radiation oncologists retrospectively reviewed all data. Computed tomography (CT) simulation was performed after head-frame fixation under local anesthesia. All planning CT images were co-registered and fused with gadolinium-enhanced magnetic resonance imaging taken within 3 months for lesions targeting and critical organs delineation. The marginal dose was prescribed at 60%–90% isodose lines, respectively, to cover $\geq 95\%$ planning target volume. Outcome evaluations included clinical tumor control rate (TCR), defined as the need for salvage therapy, and radiological response, defined as no enlargement of >2 cm in the maximal diameter. Overall survival (OS) and adverse reaction (defined according to CTCAE 5.0) were also analyzed. **Results:** The present study included 76 female and 51 male patients for analysis. The median age was 59 years (range, 20–88 years). Their diagnoses were vestibular schwannoma (VS, $n = 54$), nonvestibular cranial nerve schwannoma ($n = 6$), meningioma ($n = 50$), and pituitary adenoma ($n = 17$). Totally 136 lesions were treated in a single fraction, predominantly skull base tumors, accounting for 69.1%. Median and mean follow-up duration was 49 and 61 months (range, 1–214 months). Overall TCR was 92.9%. The 5-year disease-specific TCR for VS, nonvestibular schwannoma, meningioma, and pituitary adenoma were 97.4%, 91.7%, 93.8%, and 83.3%. Salvage therapy was indicated for eight patients at 4–110 months after SRS. Among symptomatic patients, post-SRS symptom(s) was improved, stable, and worse in 68.2%, 24.3%, and 3.6%, respectively. Radiological response rate for 111 evaluable patients was 94.6% (shrinkage, 28.8%; stable, 65.8%). OS was 96.1% without treatment-related mortality. One patient with post-SRS cranial nerve injury (0.8%, involving the trigeminal nerve, grade 2 toxicities). No grade 3–4 acute or late toxicity was found. **Conclusion:** Our results suggested that LINAC-based SRS effectively controls tumor growth and tumor-related neurological symptoms for patients with benign brain tumors. SRS is less aggressive, associated with low neurological morbidity and no mortality. Continuous follow-up is indicated to conclude longer outcomes.

KEYWORDS: Benign brain tumor, LINAC, Stereotactic radiosurgery, Tumor control rate

Submission : 16-Sep-2021
Revision : 25-Oct-2021
Acceptance : 14-Jan-2022
Web Publication : 27-Jun-2022

INTRODUCTION

Lars Leksell, a Swedish neurosurgeon at Karolinska Institute, first introduced Stereotactic radiosurgery (SRS) in managing various intracranial benign and malignant diseases with high-dose radiation without opening the skull. The first isotope radiation machine, called the Gamma knife (GK), was built up

*Address for correspondence:

Dr. Hon-Yi Lin,
Department of Radiation Oncology, Dalin Tzu Chi Hospital, Buddhist Tzu Chi Medical Foundation, 2, Min-Sheng Road, Dalin, Chiayi, Taiwan.
E-mail: doc16021@gmail.com

This is an open access journal, and articles are distributed under the terms of the Creative Commons Attribution-NonCommercial-ShareAlike 4.0 License, which allows others to remix, tweak, and build upon the work non-commercially, as long as appropriate credit is given and the new creations are licensed under the identical terms.

For reprints contact: WKHLRPMedknow_reprints@wolterskluwer.com

How to cite this article: Chew CH, Chen JC, Hung SK, Wu TH, Lee MS, Chiou WY, et al. Clinical outcomes of benign brain tumors treated with single fraction LINAC-based stereotactic radiosurgery: Experience of a single institute. Tzu Chi Med J 2022;34(4):462-72.

Access this article online

Quick Response Code:



Website: www.tcmjmed.com

DOI: 10.4103/tcmj.tcmj_260_21

to perform radiosurgery in 1968 [1]. The term “stereotactic” refers to a three-dimensional coordinate system that enables accurate simulation of a target. Radiosurgery is the procedure to deliver high doses of ionizing radiation to eradicate the selected target lesion. The dose is delivered through a large number of evenly distributed and precisely collimated narrow beams of ionizing radiation. In most models, there are usually 201 hemispherical arrays of collimated Cobalt-60 beams. The dose gradient is highly steep, showing rapid dose falloff and resulting in lesions sharply circumscribed by targeted radiation dose [2-4]. Adjacent normal or critical structures nearby the target receive very little radiation [5,6]. Patients who receive GK SRS need to have head frame fixation on achieving high precision and accuracy. So, this is a minimally invasive procedure and needs to be completed in 1 day.

SRS can be performed with GK utilizing Cobalt-60 source or X-knife generated from a linear accelerator (LINAC, CyberKnife) or heavy particles (proton therapy, heavy carbon ion) [7-19]. GK is exclusively designed for intracranial lesions, in maximal size <3 cm, such as meningioma, vestibular schwannoma (VS), trigeminal neuralgia, arteriovenous malformation, and pituitary adenoma. In contrast, LINAC can be used to deliver fractionated radiotherapy (FRT) to all parts of the body. In some instances, we deliver conventional radiation dose (1.8–2.0 Gy per fraction), known as FRT, to treat intracranial lesions close to a critical organ with less tolerance to a single-fraction high radiation dose [20-23]. LINAC-based SRS was developed in early 1980 [24]. After a series of modifications, SRS-capable LINAC is increasingly utilized for both primary and metastatic brain tumors because of its cost-effectiveness and ease of use. Solitary and multiple lesions can be treated simultaneously. Literature showed that advanced and well-equipped linear accelerators have the same effectiveness and safety profiles compatible with the GK. Improvement of multi-leaflet collimator technology, delivery technology (e.g., volumetric modulated arc therapy [VMAT]), guiding devices, and treatment planning system, LINAC SRS was proven to have similarly acceptable precision, accuracy, and mechanical stability. Here, we present the long-term results of benign tumors treated with single fraction frame-based LINAC SRS in a single institute.

MATERIALS AND METHODS

Research ethics and data collection

This study had been approved by the Institutional Review Board of Buddhist Dalin Tzu Chi Hospital (approval number: B11003015) on September 12, 2021. Informed written consent was waived because the study was a retrospective data analysis. We retrospectively retrieved and analyzed data from medical records and our prospective departmental database, the Integrated Radiotherapy Oncology Information Platform [25,26]. From May 2001 to December 2020, 127 patients who received single-fraction SRS for their benign brain tumors were analyzed. Indications of treatment included all symptomatic or progressive tumors that had either tumor-rated locally inoperable or bearing a high surgical risk for permanent neurologic deficits; residual or recurrent tumors after previous surgery; refused surgery, or increased risk of

surgery due to comorbidity. A single lesion with maximal diameter <5 cm or two to three separated lesions with each maximal diameter <3 cm was illegible. In general, treatment decisions were made by an interdisciplinary discussion between neurosurgeon and radiation oncologist.

Patients who had no complete clinical information and radiotherapy record were excluded. Patient data were retrieved from chart review and digital patient information (Hospital Information System and Integrated Radiotherapy Oncology Information Platform). Documented data included patient profiles, tumor-specific profiles, and treatment parameters. Radiation parameters, including tumor volume, marginal dose, and the number of noncoplanar arcs, were evaluated on a radiotherapy treatment planning system. Duration of treatment could be retrieved for patients who received treatment utilizing the current planning system. Treatment time was between the first cone-beam computed tomography (CBCT) acquisition and the last radiation beam completed. Beam-on time was the time that the radiation source delivered radiation.

Equipment and radiosurgery technique

All patients were co-reviewed by a neurosurgeon and a radiation oncologist before SRS. Gadolinium-enhanced brain magnetic resonance imaging (MRI) with standardized MRI protocol, including 1-mm or 3-mm T1-weight contrast-enhanced sequences, were performed within 3 months before treatment. On treatment day, 123 (96.9%) patients received head-frame fixation under local anesthesia, and 4 (3.1%) patients used bite block and intensified-thermoplastic mask immobilization. Then, a high-resolution contrast-enhanced brain computed tomography (CT) scan (i.e., 1-mm slice thickness) simulation was obtained for treatment planning. The planning CT images were co-registered and fused with MRI images to aid the delineation of the target, defined as gross tumor volume (GTV). Critical organs, including the optic nerve, optic chiasm, brainstem, cochlear, and adjacent cranial nerves, were also contoured. No margin expansion was added from GTV to generate planning target volume (PTV). Radiotherapy planning was done using FastPlan 5.5.1 (2002–2009) or Eclipse™ after 2010 (Varian Medical System, Palo Alto, CA, USA).

Prescription dose for meningioma followed the NCCN guideline. The planning and dose prescription for Schwannoma was referred to RTOG studies. In cases of pituitary adenoma, the prescription dose was based on the recommendation of large-scale studies. Marginal doses were prescribed at 60%–90% isodose line to cover at least 95% of the PTV. The marginal dose was tailored regarding the patient’s condition, tumor characteristics, tolerance of adjacent normal organs, and existing neurological functions. Therefore, the marginal doses we used for schwannoma, meningioma, and pituitary adenoma were 8–13, 8–15, and 12–16, respectively. Constraints of normal organs were brainstem (<12 Gy), cochlear (<9 Gy), optic nerve (<8 Gy), and chiasm (<8 Gy). We used multiple noncoplanar arcs of beam converging on one to three isocenter(s). After an experienced medical physicist generated the SRS plan, quality assurance for the treatment system and dry run were carried out before treatment.

SRS was delivered using 6MV LINAC equipped with VMAT technique. We used Varian Clinic 2300IX (80 multileaf collimators) system before February 2010 ($n = 15$). Then, the treatment system was upgraded to Varian Trilogy® after April 2010 ($n = 112$), which had strengths of increased dose rate and whole 360° arc of delivery to shorten treatment duration, 2D- and 3D-image guidance for better target visualization and targeting, and dynamic high-resolution 120 multileaf collimators for precise treatment. All patients received dexamethasone 4 mg, metoclopramide 10 mg, and ranitidine 50 mg injection within 1 h before SRS. Patients were treated in a supine position. The headframe and CT localizer or intensified-thermoplastic mask were fixed on a treatment couch. Precise localization was achieved by the sensitive optical guidance platform monitoring system detecting variation in 0.1 mm and CBCT for image-guided radiotherapy. The accuracy for the whole treatment was limited to <1 mm. After treatment, the head frame was removed. Patients were discharged on the following day after dexamethasone 4 mg injection.

Outcome evaluations

Contrast-enhanced T1-weighted MRI was performed in 1 year for 5 years, then at least 2 years subsequently, depending on the clinical status and physician's judgment. The follow-up schedule was 2 weeks after the procedure, then at 6 and 12 months after SRS, followed by per year subsequently. Physical and neurological examinations were evaluated on each visit.

Tumor control rate (TCR) was defined as the percentage of patients who had no requirement for salvage therapy, including re-irradiation and surgery. The period was calculated from the date of SRS to the date of salvage therapy, defined as events. Follow-up was censored at last evaluation or death. On evaluating the cumulative risk of salvage therapy, the date of the first salvage therapy after SRS was recorded. Ventriculoperitoneal shunt (VP shunt) procedure was counted as a complication. We also evaluated overall survival (OS); the period of survival was calculated from the day of SRS to the date of death. If no events happened, follow-up was censored at the last evaluation.

To determine radiologic tumor control, we measured the largest axial tumor diameter in the anteroposterior and lateral extension on T1-weighted MRIs. The interval change of the tumor size was evaluated on the latest MRI, compared with the image before SRS. Radiologic tumor control was classified into three groups, control (tumor diameter reduced by ≥ 2 mm), stable (the diameter reduced by <2 mm), and progression (tumor growth by >2 mm). Volumetric quantification on series MRIs was analyzed to study volumetric change patterns after SRS.

At each clinical follow-up, the development of symptoms was classified either as symptoms improved, stable, or worse. Toxicity of SRS was assumed when new, permanent, objectified symptoms developed after SRS. Symptoms were classified according to the Common Terminology Criteria for Adverse Events (CTCAE 5.0).

Statistics and data analysis

Accordingly, the data were analyzed using SAS (version 9.2; SAS Institute, Inc., Cary, NC, USA) and IBM SPSS (version 26, SPSS Inc., Chicago, IL, USA). Survival and local control rates were analyzed using the Kaplan-Meier method with the log-rank test. A $P < 0.05$ was considered significant statistically.

RESULTS

Patients

We identified 127 patients who received SRS within 20 years. There were 76 (59.8%) female and 51 (40.2%) male patients, at median age 60 years (range: 11–88 years). Lesion diagnoses for SRS were VS ($n = 54$, 42.5%), nonvestibular cranial nerve schwannoma (NVCNS) ($n = 6$, 4.7%), benign meningioma ($n = 50$, 39.4%), and pituitary adenoma ($n = 17$, 13.4%). The median duration between the date of diagnosis and SRS was 2 months (range: 0–149 months); 99 patients (78.0%) were treated within 1 year after a confirmed brain tumor. Indications for SRS were symptomatic tumor in 80 (63.0%), progressive asymptomatic tumor growth in eight (6.3%), and adjuvant after surgical resection in 24 (18.8%) patients. Sixteen patients (11.7%) received salvage SRS because the follow-up MRI showed tumor enlargement after previous treatment (surgery, $n = 15$; surgery and FRT, $n = 1$). Seventy-eight patients (61.4%) had a tumor with cranial nerve involvement, and seven of them had two cranial nerves involvement. All VS patients were considered as vestibulocochlear nerve involvement. Dizziness (31.5%) was the most common presentation, followed by headache and tinnitus.

Seven patients had cancer before SRS (three breast cancers, three colorectal cancers, and one hypopharyngeal cancer), as shown in Table 1. Half of them had at least one comorbidity ($n = 64$), one third had more than two comorbidities. Two patients were neurofibromatosis type II, presented with bilateral VS.

Tumor characteristics and radiation parameters

Total 136 lesions were treated. The number of patients who received SRS for one, two, and three lesions in a single session was 119 (93.7%), 7 (5.5%), and 1 (0.8%). Brain tumors were predominantly located at the skull base (69.1%), followed by supratentorial (19.9%) and infratentorial lesions (10.3%). The median tumor volume was 2.6 cm³ (range 0.1–36.6 cm³).

The median marginal doses for VS, NVCNS, meningioma, functional and nonfunctional pituitary adenoma were 12 Gy, 13 Gy, 14 Gy, 13 Gy, and 12 Gy, respectively. We prescribed marginal doses at 60% to 90% isodose lines cover $\geq 95\%$ of the PTV. LINAC systemic delivered radiation dose utilizing four to ten noncoplanar arcs (median, five arcs). Duration of treatment was available for 78 patients; median treatment time and beam on time were 25 min 52 s and 4 min 12 s, respectively [Table 2].

Tumor control rate

The median and mean duration of follow-up were 49 and 61 months (range 1–214 months). Fifty patients (39.3%) had a

duration of follow-up for more than five years; 14 patients were more than 10 years (11%). The crude rate of tumor control after SRS was 93.4%. Eight patients required salvage therapy after SRS, five received surgical resection, and three had salvage radiotherapy (one conventional radiotherapy, one hypo FRT, and one re-SRS). The indications for salvage therapy were associated with deteriorated symptoms in all patients; five of them had radiological tumor enlargement, another

three had a residual tumor. Overall, the 1-year, 2-year, 5-year, and 10-year TCR were 98.3%, 97.5%, 95.3%, and 82.8%, respectively [Figure 1a]. The 5-year disease-specific TCR s for VS, NVCNS, meningioma, and pituitary adenoma were 97.4%, 83.3%, 91.7%, and 93.8%, respectively [Figure 1b].

Table 1: Patient characteristics, n=127

Factors	n (%)
Age at SRS (year), median (range)	60 (20–88)
Gender	
Male	51 (40.2)
Female	76 (59.8)
Tumor type	
Vestibular schwannoma	54 (42.5)
Nonvestibular schwannoma	6 (4.7)
Meningioma	50 (39.4)
Pituitary adenoma	17 (13.4)
From diagnosis to SRS (year)	
≤1	99 (78.0)
>1	28 (22.0)
Indications	
Symptomatic	80 (63.0)
Asymptomatic	8 (6.3)
Postsurgery, adjuvant	23 (18.1)
Postsurgery, tumor progression	15 (11.8)
Postsurgery and RT, tumor progression	1 (0.8)
Clinical symptoms	
Cranial nerve involvement	
CN 1	1 (0.8)
CN 2	13 (10.2)
CN 5	13 (10.2)
CN 7	2 (1.6)
CN 8	56 (44.1)
Dizziness/vertigo	40 (31.5)
Headache	31 (24.4)
Hearing impairment	30 (23.6)
Tinnitus	29 (22.8)
Unsteady gait	18 (14.2)
Focal weakness	5 (3.9)
Ataxia	2 (1.6)
Endocrine disorder	6 (4.7)
Comorbidities	
Diabetes mellitus	19 (15.0)
Hypertension	46 (36.2)
Coronary artery disease	3 (2.4)
Arrhythmia	3 (2.4)
Cerebrovascular disease	3 (2.4)
End-stage renal disease	4 (3.1)
Chronic pulmonary obstructive disease	2 (1.6)
NF2	2 (1.6)
Cancer*	7 (5.5)
Auto-immune disease**	3 (2.4)
Depression	2 (1.6)

*Breast cancer (n=3), colorectal cancer (n=3), hypopharyngeal cancer (n=1), **Systemic lupus erythematosus (n=2), sicca syndrome (n=2). NF2: Neurofibrosis type 2, CN: Cranial nerve, RT: Radiotherapy, SRS: Stereotactic radiosurgery

Clinical outcome

Before SRS, 115 patients had tumor-related symptoms; the other 12 patients were asymptomatic. All asymptomatic patients remained symptom-free after treatment. Among symptomatic patients, symptom improvement, stable, and worse were 76 (66.1%), 27 (23.5%), and 4 (3.5%), respectively [Table 3].

Radiological response rate

We evaluated the radiological response for 111 patients with a median radiological follow-up interval of 38 months. The overall radiological control rate was 94.6%. Thirty-two patients (28.8%) achieved tumor control with a size reduction of at least 2 mm in diameter, and 73 patients (65.8%) had stable disease. Tumor enlargement was found in six patients (four meningiomas, one VS, and one NVCNS). Salvage intervention was performed for five patients because the enlarged tumor demonstrated neurological symptoms. Only one meningioma patient had an enlarged tumor on MRI took 1 year after SRS followed by stability; no salvage intervention was introduced because he was asymptomatic. On the analysis of the patterns of tumor volume change, eight

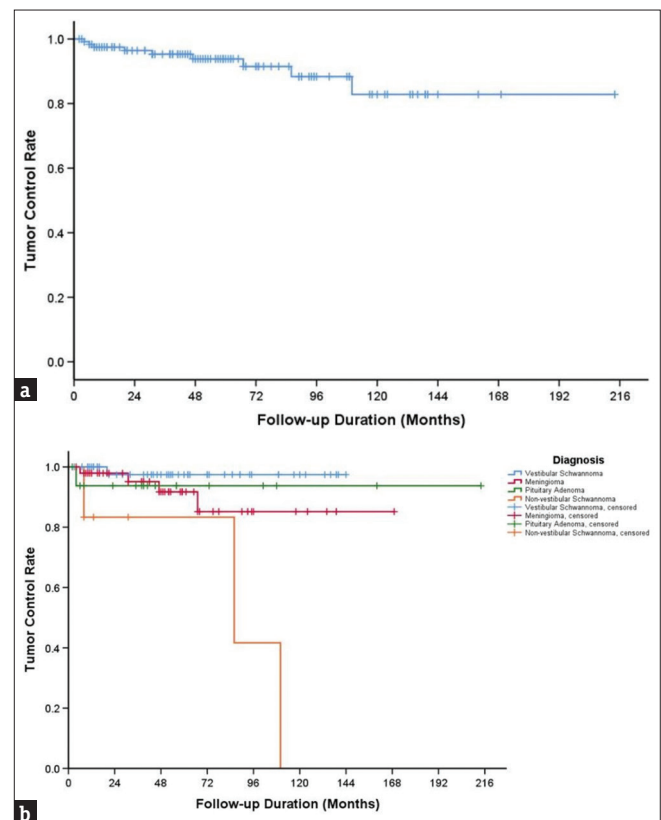


Figure 1: Tumor control rate. Kaplan-Meier plot shows the 5-year tumor control rate of 92.9% for all included patients (a). By histological grouping, 5-year Tumor control rates for vestibular schwannoma, meningioma, pituitary adenoma, and nonvestibular schwannoma were 97.4%, 91.7%, 93.8%, and 83.3%, respectively (b)

patients with VS had increased in tumor size, followed by continuous shrinkage, during a period of 13 months (range, 6–31 months). There was no need to offer salvage treatment for them [Table 4].

Overall survival

The OS rate was 96.1%, with five deaths (mean age of 72 years). Of these, three patients died due to underlying disease and old age. Two patients had advanced malignant diseases. One patient was colon cancer diagnosed 6 years before SRS and progressed to terminal stage 4 years after SRS. Another patient had multiple myeloma diagnosed 2 years after SRS [Figure 2].

Evaluation of adverse events

All patients were well tolerated to SRS. No CTCAE grade 2 or higher acute toxicity was reported. No early cranial nerve injury occurred 6 months after SRS. Four

patients developed transient adverse events, and two meningioma patients had Grade 1 headaches. A trigeminal schwannoma patient and a VS patient had transient dizziness. Gait disturbance related to hydrocephalus was diagnosed 5 months later for one VS patient who improved after VP shunt placement.

No severe late adverse events greater than Grade 2 occurred during long-term follow-up. A VS patient (0.8%) had a new-onset trigeminal injury and hydrocephalus treated with VP shunt. The other two patients with meningioma developed post-SRS hydrocephalus and were then managed by VP shunt. One left VS patient developed persistent dizziness 7 years after SRS, also associated with chronic otitis media. After local surgery, the patient continued medications for symptomatic control. There was no evidence of radionecrosis on MRIs [Table 5].

DISCUSSION

In the present study, the indications for SRS were schwannoma, meningioma, and pituitary adenoma. Predominantly, these tumors are located at the skull base. Meningioma, pituitary adenoma, and schwannoma were the three most common benign brain tumors, composing 36.4%, 15.5%, and 8.1%–11.5% of all primary intracranial tumors [27,28]. Managements for these benign tumors include observation, microsurgery, and radiation therapy. The TCR s after microsurgery correlate with the extension of tumor removal. In managing meningioma, if total or near-total, i.e., Simpson grade I/II, resection is achieved, TCR is up to 97% [29-31]. However, the TCR decreases to 29% [32,33]. If safety and functional preservation are the primary concern, it is technically challenging to perform complete tumor resection. Surgical morbidity is high for tumors located in high-risk regions of the skull base [34-43]. In this regard, SRS plays a crucial role in managing tumors located at the skull base or adjacent to critical neurovascular structures. Therefore, most neurosurgeons may prefer to manage high-risk and deep-location tumors less aggressively unless these tumors cause mass effect, mechanical compression, and bleeding. Remarkably, observation is reasonable for elderly and vulnerable patients, especially when tumor-related symptoms are mild [44-46]. Managing brain tumors is challenging; interdisciplinary decision-making between neurosurgeons and radiation oncologists is critical.

Table 2: Tumor characteristics of the 136 lesions treated with stereotactic radiosurgery and radiotherapy parameters (n=127)

Factors	Results
Number of lesions per patient, n (%)#	
1 lesion	119 (93.7)
2 lesions	7 (5.5)
3 lesions	1 (0.8)
Number of noncoplanar arcs, median (range)#	5 (4–10)
Location of lesions, n (%)*	
Supratentorial	27 (19.9)
Infratentorial	14 (10.3)
Skull base	94 (69.1)
Optic nerve	1 (0.7)
Tumor volume (cm ³), median (range)*	2.6 (0.1–36.6)
Prescription dose (Gy), median (range)*	
VS (n=54)	12 (8–18)
Nonvestibular schwannoma (n=6)	13 (10–15)
Meningioma (n=57)	14 (8–20)
Pituitary adenoma	
Functional (n=4)	13 (12–16)
Nonfunctional (n=13)	12 (8–16)
Duration of treatment (n=78)	
Treatment time, hh: mm: ss	00:25:52 (00:12:46–01:43:20)
Beam on time, mm: ss, median	04:12 (02:02–15: 7)

*Account for the 136 treated lesions, #Account for the 127 patients in study. VS: Vestibular schwannoma

Table 3: Clinical improvement after stereotactic radiosurgery

Disease type	Pre-SRS		Post-SRS		
	Symptoms	n (%)*	Improved, n (%)*	Stable, n (%)*	Deteriorating, n (%)*
Schwannoma (n=60)	No	1 (0.7)	-	-	-
	Yes	59 (98.3)	34 (56.7)	18 (30.0)	3 (5.0)
Meningioma (n=50)	No	13 (26.0)	-	-	-
	Yes	37 (74.0)	29 (58.0)	7 (14.0)	1 (2.0)
Pituitary adenoma (n=17)	No	2 (11.8)	-	-	-
	Yes	15 (88.2)	13 (76.5)	2 (11.7)	0
Total	Symptomatic	111 (87.4)†	76 (68.5)†	27 (24.3)†	4 (3.6)†

Among 111 symptomatic patients, patient had improved, stable, and deteriorating symptoms were 68.5%, 24.3%, and 3.6%, respectively. *Percentage of symptoms based on the total patient number for each tumor subgroup, †Percentage based on the 111 symptomatic patients. SRS: Stereotactic radiosurgery

Table 4: Radiological response rate and patterns of tumor response of the 111 patients with evaluable contrast-enhanced magnetic resonance imaging

Parameters	n	Percentage (%)
Radiological control	32	28.8
Stable	73	65.8
Stable, both image and asymptomatic	71	
Stable, with neurological deficit, with salvage surgery	3	
Progression	6	5.4
Salvage surgery	2	
Salvage RT	3*	
No treatment	1†	
Changes of tumor volume		
Shrinkage, no swelling/enlargement	30	27.0
Stability, no swelling/enlargement	66	59.5
Increased in size first, followed by shrinkage	8	7.2
Increased in size first, followed by stability	1	0.9
Continues to increase in size but no need for salvage treatment	1	0.9
Stability followed by growth years later	2	1.8
Continued growth beyond the expected swelling period	3	2.7

Overall radiological response rate was 94.6%. *Types of salvage radiotherapy were as follows: Conventional RT, n=1; hypofractionated radiotherapy, n=1; and, re-SRS, n=1. †MRI at 1-year follow-up showed enlargement but asymptomatic. MRI: Magnetic resonance imaging, RT: Radiotherapy

Table 5: Overview of early and late onset of adverse events after stereotactic radiosurgery according to the common terminological criteria for adverse events 5.0 criteria

Grade	Early onset (≤6 months)				Late onset (>6 months)			
	1	2	3	4	1	2	3	4
Dizziness (n=4)	2	0	0	0	1	1	0	0
Headache (n=3)	2	0	0	0	1	0	0	0
Trigeminal neuropathy (n=1)	0	0	0	0	0	1	0	0
Gait disturbance (n=4)	0	1*	0	0	0	3*	0	0

*Ventriculoperitoneal shunt placement after SRS due to hydrocephalus. SRS: Stereotactic radiosurgery

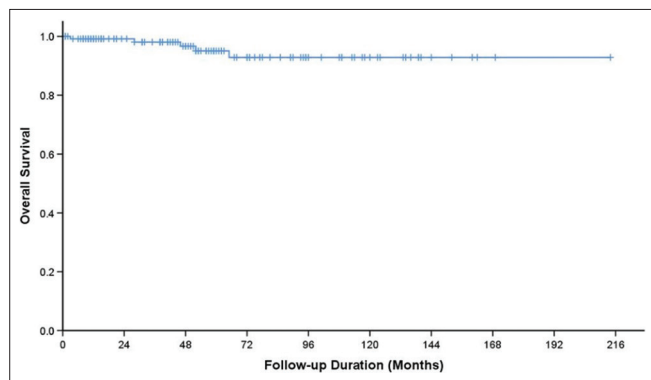


Figure 2: Overall survival. Kaplan-Meier curve of overall survival shows 96.1%

SRS is widely used to treat benign brain tumors because it is less invasive and offers high long-term effectiveness. In our study with a mean follow-up period of 5 years,

TCR s are high and comparable with previous studies, being 90%–99% [47-50]. Although responses to SRS for different histology types demonstrate some variation, the differences are not largely significant. Five-year and 10-year local TCR s for VS treated with SRS were 90%–100% and 92%–98% [51-57]. In meningioma, 5-year and 10-year TCR s were 86%–99%, and 69%–97%, respectively [43,58-63]. The main purpose of delivering SRS for pituitary adenoma is to prevent tumor progression, but it shows a relatively slow response for hypersecretion of functional adenoma. The tumor growth-control rate for pituitary adenoma was around 90%–93% at 5–10 years [64-69]. A comprehensive review of the long-term outcome of a large population treated with SRS was summarized [Table 6]. Our analysis revealed that clinical tumor control was within this range after 5 and 10 years.

The VS subgroup achieved the highest and durable TCR in the present study. The median marginal dose we prescribed was 12 Gy. According to current practice guidelines, including ASTRO Quantec, AANS and CNS association, and ESTRO Guidelines, a marginal dose of less than 13 Gy is recommended [44,46,70]. Compared with higher doses, 12–13 Gy showed no clinical and radiological control difference. It was proven beneficial for hearing preservation, increased from 20%–26% to 32%–68% and minimized trigeminal and facial nerve complications from >90% to 14%–60% [52-54,56,57,71,72]. Notably, 31% of our patients who received lower marginal doses with 8–11 Gy obtained favorable TCR during the long-term follow-up period. Our patients had no cranial nerve injury or deterioration of hearing.

With an advanced skull base endoscopic approach, surgical resection is the mainstay of treatment. In the surgical series, 67%–90% of patients achieved total tumor removal, but the newly developed morbidity rates were 5%–62%, and mortality rates were 0%–3% [73]. The morbidity of resection is still relatively high, depending on the size and location of the tumor. Patients with NVCNS demonstrate a higher rate of salvage therapy after SRS. SRS technique possesses safety advantages and reduces the rates of symptoms deterioration to 0-16% [74-78]. Unlike VS, NVCNS had a lower 5-year tumor growth control rate when treated with SRS alone, being around 80% [73,79-81]. Among our six NVCNS patients, one patient showed tumor growth with deterioration of neurological symptoms and required microsurgery at 8 months after SRS. The other two patients required salvage surgery at 86 months and conventional radiotherapy at 110 months after SRS due to neurological symptoms. The latter patient had tumor enlargement. All patients were stable after salvage management. The patient number in our study is too small to conclude the effectiveness of SRS. Long-term follow-up is crucial to monitor late recurrence. Salvage therapy, either surgical or radiation therapy, can provide the opportunity to improve or at least preserve neurological function.

In the present study, tumor control failure was defined as the requirement for salvage radiotherapy, surgery, or a combination of these procedures. This endpoint is also presented in many large population studies for meningiomas

Table 6: Summary of selected studies for benign tumors treated with stereotactic radiosurgery

Author	n	FU (months)	Technique	Tumor volume	Median dose	Tumor control, 5-year	Outcome parameters		
Vestibular schwannoma							CN V (%)*	CN VII (%)*	Hearing (%)*
Kondziolka et al., 1998 [51]	162	>60	GK	2.2 cm ³	16.6 [†]	98% (5 year, 10 year)	73	73q	51
Chopra et al., 2007 [52]	383	43.2	CK	1.3 cm ³	13 Gy	98.3% (10 year)	94.9	100	44
Murphy et al., 2011 [53]	103	37.5	GK	1.95 cm ³	13 Gy	91.1%	99	95	84.6
Rueß et al., 2018 [54]	335	30	LINAC/CK	1.1 cm ³	12 Gy	89% (5 year); 88% (10 year)	96.2	96.4	56
Dupic et al., 2020 [55]	97	98.4	LINAC	1.96 cm ^{3†}	14 Gy	98.4% (5 year); 95.6% (10 year)	92.8	93.8	64.3
The present study	54	53	LINAC	1.0 cm ³	12 Gy	97.4% (5 year, 10 year)	98.1	100	72.2
Author	n	FU (months)	Technique	Tumor volume (cm ³)	Median dose (Gy)	Tumor control, 5-year (%)	Outcome parameters		
Meningioma							Toxicity (%)		
Kondziolka et al., 2008 [58]	972	48	GK	7.4 [†]	14	93	7.7		
Skeie et al., 2010 [59]	100	82 [†]	GK	7.39 [†]	12.4	84	6.0		
Spiegelmann et al., 2010 [60]	102	67 [†]	LINAC	7 [†]	13.5 [†]	98	5		
Pollock et al., 2012 [61]	251	62.9 [†]	GK	7.7	15.8	99.4	Temporary 3.2; permanent 9.2		
El-Khatib et al., 2015 [43]	148	144	LINAC	4.7	12	93.6	7.8		
Faramand et al., 2019 [62]	135	75	GK	8.1	13	90	10		
The present study	50	50	LINAC	5.1	14	96	No CN toxicity; VP shunt: n=2 (4)		
Author	n	FU (months)	Technique	Tumor volume (cm ³)	Median dose (Gy)	Tumor control, 5-year (%)	Outcome parameters		
Pituitary adenoma							Endocrine remission (%)	Hypopituitarism (%)	
Devin et al., 2004 [64]	35	42 [†]	GK	NA	14.7 [†]	91	49	40	
Voges et al., 2006 [65]	142	81.9 [†]	LINAC	4.3 [†]	15.3	96.5	32.4	12.3	
Sheehan et al., 2011 [66]	418	31	GK	1.9	24	90.3	24.4	24.4	
Runge et al., 2012 [67]	65	83	LINAC	3.5	13	98	NA	9.8	
Li et al., 2021 [68]	369	144.1	GK	3.5	13.3	93.5	NA	NA	
The present study	17	41	LINAC	3.05	12	94.10	33	28.6	
Author	n	FU (months)	Technique	Tumor volume (cm ³)	Median dose (Gy)	Tumor control, 5-year (%)	Outcome parameters		
Nonvestibular schwannoma							Toxicity (%)		
Pan et al., 2005 [76]	56	68 [†]	GK	8.7	13.3 [†]	93	NA		
Ryu et al., 2018 [74]	22	90.5	GK	3.55	13	86.2 (5 year)	6.25		
The present study	6	37	LINAC	9	12	50	0		

*Functional preservation rate, [†]Mean, [‡]Dimension. CN: Cranial nerve, CN V: Trigeminal nerve, CN VII: Facial nerve, CK: CyberKnife, FU: Follow-up, fx: Fraction, GKS: Gamma knife radiosurgery, Gy: Gray, LINAC: Linear accelerator, n: number of cases, NA: Not available, PTV: Planning target volume

and VS [74,82-84]. Surgery for VP shunt was considered a complication but not treatment failure. Besides, radiological tumor response is defined by the variation of maximal tumor diameter, and volumetric quantification is considered a sensitive indicator for tumor progression [85-88]. On evaluating maximal tumor diameter, we selected the stricter threshold of the change of diameter, 2 mm, which was used in large population studies [51,89,90]. In meningioma and VS, a temporary enlargement of tumor size may occur within 6–18 months after SRS, followed by long-term stability or regression. This enlargement pattern followed by volumetric regression was found in nine patients (eight VS and one meningioma). As a result, it was essential to have regular neuroimaging in the first 3 years after treatment. Close observation was advised if the tumor enlargement do not associate with aggravated neurological symptoms and signs in this period [91-93]. Such a pattern

of pseudoprogression did not occur in our cases of pituitary adenoma or NVCNS.

This study reported our 20-year experience of performing LINAC-based SRS, which showed similar results as previous studies for meningioma [43,90,94-97], schwannoma [56,89], and pituitary adenoma [64,65]. The 5-year TCR s were comparable with GK series, and the neurological toxicities were not increased. The measured radiological accuracy for GK is down to 0.15–0.3 mm [98,99] compared with about 0.5–1.00 mm for LINAC system [100-102]. However, advancement of the treatment planning system, incorporated with MRI guidance (MR-LINAC), and smart frameless stereotactic navigation devices are under development to minimize the differences between these two systems.

There are three advantages of LINAC-based SRS. First, LINAC-based SRS can perform FRT. Fractionation

radiotherapy delivered a lower dose per fraction to allow a higher accumulative dose to the target. This benefit can improve tumor control while sparing radiosensitive normal tissue to high radiation doses. The center nervous system is susceptible to radiation, especially the optic nerve, chiasm, and brainstem. High concern to limit radiation dose exposure to these critical structures is the mainstay to avoid irreversible neurological complications. Therefore, tumors in proximity to the optic chiasm, such as pituitary adenoma, AVM, and meningioma at cavernous sinus, are preferred to be treated with fractionated stereotactic radiotherapy. Second, the immobilization and localization of LINAC-based SRS can apply head-frame fixation for single-use (similar to GK) or noninvasive methods, such as thermoplastic, upper-jaw fixation mold, or vacuum-formed masks, incorporated with precise treatment couch and highly stable treatment isocenters identified by CBCT for targeting and optical tracking system. Third, the LINAC system is relatively easy to use, low-cost, and wide-range indicated. SRS-capable LINAC offers radiotherapy for intra- and extracranial lesions, while indications of GK are limited to small intracranial or upper cervical spine lesions. It is also difficult for GK to treat peripherally or laterally located lesions due to collision of the head or the head frame with the helmet. These lesions are generally can be approached by LINAC. Furthermore, the Cobalt-based GK system required additional maintenance and replacing the decaying cobalt sources. Therefore, LINAC-based SRS is more flexible and financially feasible for a smaller community hospital.[103,104]. Patients in our regional hospital find it more accessible to receive LINAC-based SRS than referral for GK SRS in another farther center.

Benign brain tumors seldom lead to mortality. No patients in our cohort had SRS-related mortality. The causes of death were mainly due to comorbidities and aging. The two patients died of terminal cancer; they were diagnosed with colon cancer and multiple myeloma, not at the treatment fields. The risk of radiation-induced tumors is rare. A retrospective review of 1837 patients who received single-fraction SRS for arteriovenous malformation or benign brain tumors found that no patients had radiation-induced tumors at 5 and 10 years [105].

Most of the patients who suffered from treatment-related toxicities had skull base tumors, including VS and NVCNS. Most acute adverse reactions were mild and transient. The incidence of late toxicity was low, and all could be managed medically. Four patients with skull base tumors required VP shunt placement after SRS due to new or worsening hydrocephalus. Previous results showed that the incidence of VP procedure after SRS was around 1%–5% [56,72,97]. All patients improved after the procedure without long-term sequelae. Older studies showed high cranial nerve complications after SRS because the higher marginal dose was prescribed. After dose reduction, recent studies suggested that the cranial nerve injuries to trigeminal or facial after SRS for VS of skull base tumors was reported as low as 5% at 10 years [57]. Our cranial nerve complication was <1% because our marginal dose prescriptions followed the dose

reduction strategy. More notably, critical organ delineations were guided by using MRI, and dose constraints strictly adhered to our brain irradiation principle.

Limitations

The present study has some limitations. First, the study's retrospective nature is the reason for incomplete data, particularly regarding late toxic effects. Second, tumor-contouring images were based on one treating radiation oncologist; thus, there would be some variations on tumor volume. However, gadolinium-enhanced MRIs were obtained for all patients to define the target lesions accurately. Two experienced radiation oncologists reviewed all contours well to avoid the variation or target miss. Third, about 5% of patients lost follow-up at our institute because they returned to their original hospital to continue treatment. Our nurses record their status by using the telephone for these patients, which accounted for about 1% of cases. Finally, the cohort has mixed histologic tumor subtypes; however, it represents a real-world scenario and, therefore, probably represents the best data available to answer the clinical questions.

CONCLUSION

LINAC-based SRS is an effective treatment modality for benign brain tumors, including VS, meningioma, and pituitary schwannoma. In patients with NVCNS, more prolonged surveillance is indicated because late progression may occur, which can be salvaged with aggressive intervention. High clinical and radiological control rates can be achieved with this minimally invasive and safe procedure. The most concern toxicity is neurological deficit caused by high radiation dose; the complication rate is <1%. Disease-specific analysis showed that VS achieved the highest benefit, although the prescription dose was lower (<12 Gy).

Financial support and sponsorship

Nil.

Conflicts of interest

There are no conflicts of interest.

REFERENCES

1. Leksell DG. Stereotactic radiosurgery. Present status and future trends. *Neurol Res* 1987;9:60-8.
2. Larson DA, Flickinger JC, Loeffler JS. The radiobiology of radiosurgery. *Int J Radiat Oncol Biol Phys* 1993;25:557-61.
3. Paskalev KA, Seuntjens JP, Patrocinio HJ, Podgorsak EB. Physical aspects of dynamic stereotactic radiosurgery with very small photon beams (1.5 and 3 mm in diameter). *Med Phys* 2003;30:111-8.
4. Sheehan JP, Yen CP, Lee CC, Loeffler JS. Cranial stereotactic radiosurgery: Current status of the initial paradigm shifter. *J Clin Oncol* 2014;32:2836-46.
5. Shaw E, Kline R, Gillin M, Souhami L, Hirschfeld A, Dinapoli R, et al. Radiation Therapy Oncology Group: Radiosurgery quality assurance guidelines. *Int J Radiat Oncol Biol Phys* 1993;27:1231-9.
6. Reynolds TA, Jensen AR, Bellairs EE, Ozer M. Dose Gradient Index for stereotactic radiosurgery/radiation therapy. *Int J Radiat Oncol Biol Phys* 2020;106:604-11.
7. Yoon SC, Suh TS, Jang HS, Chung SM, Kim YS, Ryu MR, et al. Clinical results of 24 pituitary macroadenomas with linac-based stereotactic radiosurgery. *Int J Radiat Oncol Biol Phys* 1998;41:849-53.

8. Mitsumori M, Shrieve DC, Alexander E 3rd, Kaiser UB, Richardson GE, Black PM, et al. Initial clinical results of LINAC-based stereotactic radiosurgery and stereotactic radiotherapy for pituitary adenomas. *Int J Radiat Oncol Biol Phys* 1998;42:573-80.
9. Chang SD, Main W, Martin DP, Gibbs IC, Heilbrun MP. An analysis of the accuracy of the CyberKnife: A robotic frameless stereotactic radiosurgical system. *Neurosurgery* 2003;52:140-6.
10. Bolsi A, Fogliata A, Cozzi L. Radiotherapy of small intracranial tumours with different advanced techniques using photon and proton beams: A treatment planning study. *Radiother Oncol* 2003;68:1-14.
11. Milker-Zabel S, Zabel-du Bois A, Huber P, Schlegel W, Debus J. Intensity-modulated radiotherapy for complex-shaped meningioma of the skull base: Long-term experience of a single institution. *Int J Radiat Oncol Biol Phys* 2007;68:858-63.
12. Calcerrada Diaz-Santos N, Blasco Amaro JA, Cardiel GA, Andradas Aragonés E. The safety and efficacy of robotic image-guided radiosurgery system treatment for intra- and extracranial lesions: A systematic review of the literature. *Radiother Oncol* 2008;89:245-53.
13. Arvold ND, Lessell S, Bussiere M, Beaudette K, Rizzo JF, Loeffler JS, et al. Visual outcome and tumor control after conformal radiotherapy for patients with optic nerve sheath meningioma. *Int J Radiat Oncol Biol Phys* 2009;75:1166-72.
14. Halasz LM, Bussière MR, Dennis ER, Niemierko A, Chapman PH, Loeffler JS, et al. Proton stereotactic radiosurgery for the treatment of benign meningiomas. *Int J Radiat Oncol Biol Phys* 2011;81:1428-35.
15. Amichetti M, Amelio D, Minniti G. Radiosurgery with photons or protons for benign and malignant tumours of the skull base: A review. *Radiat Oncol* 2012;7:210.
16. Eaton DJ, Lee J, Patel R, Millin AE, Paddick I, Walker C. Stereotactic radiosurgery for benign brain tumors: Results of multicenter benchmark planning studies. *Pract Radiat Oncol* 2018;8:e295-304.
17. Germano IM, Sheehan J, Parish J, Atkins T, Asher A, Hadjipanayis CG, et al. Congress of neurological surgeons systematic review and evidence-based guidelines on the role of radiosurgery and radiation therapy in the management of patients with vestibular schwannomas. *Neurosurgery* 2018;82:E49-51.
18. Fanous AA, Prasad D, Mathieu D, Fabiano AJ. Intracranial stereotactic radiosurgery. *J Neurosurg Sci* 2019;63:61-82.
19. Combs SE, Hartmann C, Nikoghosyan A, Jäkel O, Karger CP, Haberer T, et al. Carbon ion radiation therapy for high-risk meningiomas. *Radiother Oncol* 2010;95:54-9.
20. Williams JA. Fractionated stereotactic radiotherapy for acoustic neuromas. *Acta Neurochir (Wien)* 2002;144:1249-54.
21. Minniti G, Scaringi C, Paolini S, Lanzetta G, Romano A, Cicone F, et al. Single-fraction versus multifraction (3×9 Gy) stereotactic radiosurgery for large (>2 cm) brain metastases: A comparative analysis of local control and risk of radiation-induced brain necrosis. *Int J Radiat Oncol Biol Phys* 2016;95:1142-8.
22. Lehrer EJ, Peterson JL, Zaorsky NG, Brown PD, Sahgal A, Chiang VL, et al. Single versus multifraction stereotactic radiosurgery for large brain metastases: An international meta-analysis of 24 trials. *Int J Radiat Oncol Biol Phys* 2019;103:618-30.
23. Oh HJ, Cho YH, Kim JH, Kim CJ, Kwon DH, Lee D, et al. Hypofractionated stereotactic radiosurgery for large-sized skull base meningiomas. *J Neurooncol* 2020;149:87-93.
24. Winston KR, Lutz W. Linear accelerator as a neurosurgical tool for stereotactic radiosurgery. *Neurosurgery* 1988;22:454-64.
25. Yeh PH, Hung SK, Lee MS, Chiou WY, Lai CL, Tsai WT, et al. Implementing web-based Ping-Pong-type e-communication to enhance staff satisfaction, multidisciplinary cooperation, and clinical effectiveness: A SQUIRE-compliant quality-improving study. *Medicine (Baltimore)* 2016;95:e5236.
26. Lin YH, Hung SK, Lee MS, Chiou WY, Lai CL, Shih YT, et al. Enhancing clinical effectiveness of pre-radiotherapy workflow by using multidisciplinary-cooperating e-control and e-alerts: A SQUIRE-compliant quality-improving study. *Medicine (Baltimore)* 2017;96:e7185.
27. Tos M, Stangerup SE, Cayé-Thomasen P, Tos T, Thomsen J. What is the real incidence of vestibular schwannoma? *Arch Otolaryngol Head Neck Surg* 2004;130:216-20.
28. Ostrom QT, Gittleman H, Fulop J, Liu M, Blanda R, Kromer C, et al. CBTRUS statistical report: Primary brain and central nervous system tumors diagnosed in the United States in 2008-2012. *Neuro Oncol* 2015;17 (Suppl 4):iv1-62.
29. Chan RC, Thompson GB. Morbidity, mortality, and quality of life following surgery for intracranial meningiomas. A retrospective study in 257 cases. *J Neurosurg* 1984;60:52-60.
30. Giombini S, Solero CL, Lasio G, Morello G. Immediate and late outcome of operations for Parasagittal and falx meningiomas. Report of 342 cases. *Surg Neurol* 1984;21:427-35.
31. Couldwell WT, Fukushima T, Giannotta SL, Weiss MH. Petroclival meningiomas: Surgical experience in 109 cases. *J Neurosurg* 1996;84:20-8.
32. Barbaro NM, Gutin PH, Wilson CB, Sheline GE, Boldrey EB, Wara WM. Radiation therapy in the treatment of partially resected meningiomas. *Neurosurgery* 1987;20:525-8.
33. Goldsmith BJ, Wara WM, Wilson CB, Larson DA. Postoperative irradiation for subtotally resected meningiomas. A retrospective analysis of 140 patients treated from 1967 to 1990. *J Neurosurg* 1994;80:195-201.
34. Sughrue ME, Yang I, Aranda D, Rutkowski MJ, Fang S, Cheung SW, et al. Beyond audiofacial morbidity after vestibular schwannoma surgery. *J Neurosurg* 2011;114:367-74.
35. Sylvester MJ, Shastri DN, Patel VM, Raikundalia MD, Eloy JA, Baredes S, et al. Outcomes of vestibular schwannoma surgery among the elderly. *Otolaryngol Head Neck Surg* 2017;156:166-72.
36. Hatch JL, Bauschard MJ, Nguyen SA, Lambert PR, Meyer TA, McRackan TR. National trends in vestibular schwannoma surgery: Influence of patient characteristics on outcomes. *Otolaryngol Head Neck Surg* 2018;159:102-9.
37. Kallio M, Sankila R, Hakulinen T, Jääskeläinen J. Factors affecting operative and excess long-term mortality in 935 patients with intracranial meningioma. *Neurosurgery* 1992;31:2-12.
38. Sacko O, Sesay M, Roux FE, Riem T, Grenier B, Liguoro D, et al. Intracranial meningioma surgery in the ninth decade of life. *Neurosurgery* 2007;61:950-4.
39. Black PM, Villavicencio AT, Rhouddou C, Loeffler JS. Aggressive surgery and focal radiation in the management of meningiomas of the skull base: Preservation of function with maintenance of local control. *Acta Neurochir (Wien)* 2001;143:555-62.
40. DeMonte F, Smith HK, al-Mefty O. Outcome of aggressive removal of cavernous sinus meningiomas. *J Neurosurg* 1994;81:245-51.
41. Dufour H, Muracciole X, Métellus P, Régis J, Chinot O, Grisoli F. Long-term tumor control and functional outcome in patients with cavernous sinus meningiomas treated by radiotherapy with or without previous surgery: Is there an alternative to aggressive tumor removal? *Neurosurgery* 2001;48:285-94.
42. Samii M, Tatagiba M, Monteiro ML. Meningiomas involving the parasellar region. *Acta Neurochir Suppl* 1996;65:63-5.
43. El-Khatib M, El Majdoub F, Hunsche S, Hoevels M, Kocher M, Sturm V, et al. Stereotactic LINAC radiosurgery for the treatment of typical intracranial meningiomas. Efficacy and safety after a follow-up of over 12 years. *Strahlenther Onkol* 2015;191:921-7.
44. Combs SE, Baumert BG, Bendszus M, Bozzao A, Brada M, Fariselli L, et al. ESTRO ACROP guideline for target volume delineation of skull base tumors. *Radiother Oncol* 2021;156:80-94.
45. Goldbrunner R, Stavrinou P, Jenkinson MD, Sahm F, Mawrin C, Weber DC, et al. EANO guideline on the diagnosis and management of

- meningiomas. *Neuro Oncol* 2021;23:1821-34.
46. Olson JJ, Kalkanis SN, Ryken TC. Congress of neurological surgeons systematic review and evidence-based guidelines on the treatment of adults with vestibular schwannomas: Executive summary. *Neurosurgery* 2018;82:129-34.
 47. Rueß D, Weyer V, Tutunji J, Grau S, Kocher M, Hoevens M, et al. Stereotactic radiosurgery of benign brain tumors in elderly patients: Evaluation of outcome and toxicity. *Radiat Oncol* 2020;15:274.
 48. Tzikoulis V, Gkantaifi A, Alongi F, Tsoukalas N, Saraireh HH, Charalampakis N, et al. Benign intracranial lesions – Radiotherapy: An overview of treatment options, indications and therapeutic results. *Rev Recent Clin Trials* 2020;15:93-121.
 49. Jahanbakhshi A, Azar M, Kazemi F, Jalessi M, Chanideh I, Amini E. Gamma Knife stereotactic radiosurgery for cerebellopontine angle meningioma. *Clin Neurol Neurosurg* 2019;187:105557.
 50. Kondziolka D, Nathoo N, Flickinger JC, Niranjan A, Maitz AH, Lunsford LD. Long-term results after radiosurgery for benign intracranial tumors. *Neurosurgery* 2003;53:815-21.
 51. Kondziolka D, Lunsford LD, McLaughlin MR, Flickinger JC. Long-term outcomes after radiosurgery for acoustic neuromas. *N Engl J Med* 1998;339:1426-33.
 52. Chopra R, Kondziolka D, Niranjan A, Lunsford LD, Flickinger JC. Long-term follow-up of acoustic schwannoma radiosurgery with marginal tumor doses of 12 to 13 Gy. *Int J Radiat Oncol Biol Phys* 2007;68:845-51.
 53. Murphy ES, Barnett GH, Vogelbaum MA, Neyman G, Stevens GH, Cohen BH, et al. Long-term outcomes of Gamma Knife radiosurgery in patients with vestibular schwannomas. *J Neurosurg* 2011;114:432-40.
 54. Rueß D, Pöhlmann L, Hellerbach A, Hamisch C, Hoevens M, Treuer H, et al. Acoustic neuroma treated with stereotactic radiosurgery: Follow-up of 335 patients. *World Neurosurg* 2018;116:e194-202.
 55. Dupic G, Urcissin M, Mom T, Verrelle P, Dedieu V, Molnar I, et al. Stereotactic radiosurgery for vestibular schwannomas: Reducing toxicity with 11 Gy as the marginal prescribed dose. *Front Oncol* 2020;10:598841.
 56. Benghiat H, Heyes G, Nightingale P, Hartley A, Tiffany M, Spooner D, et al. Linear accelerator stereotactic radiosurgery for vestibular schwannomas: A UK series. *Clin Oncol (R Coll Radiol)* 2014;26:309-15.
 57. Murphy ES, Suh JH. Radiotherapy for vestibular schwannomas: A critical review. *Int J Radiat Oncol Biol Phys* 2011;79:985-97.
 58. Kondziolka D, Mathieu D, Lunsford LD, Martin JJ, Madhok R, Niranjan A, et al. Radiosurgery as definitive management of intracranial meningiomas. *Neurosurgery* 2008;62:53-8.
 59. Skeic BS, Enger PO, Skeic GO, Thorsen F, Pedersen PH. Gamma knife surgery of meningiomas involving the cavernous sinus: Long-term follow-up of 100 patients. *Neurosurgery* 2010;66:661-8.
 60. Spiegelmann R, Cohen ZR, Nissim O, Alezra D, Pfeffer R. Cavernous sinus meningiomas: A large LINAC radiosurgery series. *J Neurooncol* 2010;98:195-202.
 61. Pollock BE, Stafford SL, Link MJ, Garces YI, Foote RL. Single-fraction radiosurgery for presumed intracranial meningiomas: Efficacy and complications from a 22-year experience. *Int J Radiat Oncol Biol Phys* 2012;83:1414-8.
 62. Faramand A, Kano H, Niranjan A, Park KJ, Flickinger JC, Lunsford LD. Tumor control and cranial nerve outcomes after adjuvant radiosurgery for low-grade skull base meningiomas. *World Neurosurg* 2019;127:e221-9.
 63. Lee CC, Trifiletti DM, Sahgal A, DeSalles A, Fariselli L, Hayashi M, et al. Stereotactic radiosurgery for benign (World Health Organization Grade I) Cavernous Sinus Meningiomas-International Stereotactic Radiosurgery Society (ISRS) practice guideline: A systematic review. *Neurosurgery* 2018;83:1128-42.
 64. Devin JK, Allen GS, Cmelak AJ, Duggan DM, Blevins LS. The efficacy of linear accelerator radiosurgery in the management of patients with Cushing's disease. *Stereotact Funct Neurosurg* 2004;82:254-62.
 65. Voges J, Kocher M, Runge M, Poggenborg J, Lehrke R, Lenartz D, et al. Linear accelerator radiosurgery for pituitary macroadenomas: A 7-year follow-up study. *Cancer* 2006;107:1355-64.
 66. Sheehan JP, Pouratian N, Steiner L, Laws ER, Vance ML. Gamma Knife surgery for pituitary adenomas: Factors related to radiological and endocrine outcomes. *J Neurosurg* 2011;114:303-9.
 67. Runge MJ, Maarouf M, Hunsche S, Kocher M, Ruge MI, El Majdoub F, et al. LINAC-radiosurgery for nonsecreting pituitary adenomas. Long-term results. *Strahlenther Onkol* 2012;188:319-25.
 68. Li Y, Wu L, Quan T, Fu J, Cao L, Li X, et al. Characteristic of tumor regrowth after gamma knife radiosurgery and outcomes of repeat gamma knife radiosurgery in nonfunctioning pituitary adenomas. *Front Oncol* 2021;11:627428.
 69. Minniti G, Osti MF, Niyazi M. Target delineation and optimal radiosurgical dose for pituitary tumors. *Radiat Oncol* 2016;11:135.
 70. Bhandare N, Jackson A, Eisbruch A, Pan CC, Flickinger JC, Antonelli P, et al. Radiation therapy and hearing loss. *Int J Radiat Oncol Biol Phys* 2010;76:S50-7.
 71. Lunsford LD, Niranjan A, Flickinger JC, Maitz A, Kondziolka D. Radiosurgery of vestibular schwannomas: Summary of experience in 829 cases. *J Neurosurg* 2005;102 (Suppl):195-9.
 72. Klijn S, Verheul JB, Beute GN, Leenstra S, Mulder JJ, Kunst HP, et al. Gamma knife radiosurgery for vestibular schwannomas: Evaluation of tumor control and its predictors in a large patient cohort in The Netherlands. *J Neurosurg* 2016;124:1619-26.
 73. Suárez C, López F, Mendenhall WM, Andreasen S, Mikkelsen LH, Langendijk JA, et al. Trends in the management of non-vestibular skull base and intracranial schwannomas. *Cancer Manag Res* 2021;13:463-78.
 74. Ryu J, Lee SH, Choi SK, Lim YJ. Gamma knife radiosurgery for trigeminal schwannoma: A 20-year experience with long-term treatment outcome. *J Neurooncol* 2018;140:89-97.
 75. Snyder MH, Shepard MJ, Chen CJ, Sheehan JP. Stereotactic radiosurgery for trigeminal schwannomas: A 28-year single-center experience and review of the literature. *World Neurosurg* 2018;119:e874-81.
 76. Pan L, Wang EM, Zhang N, Zhou LF, Wang BJ, Dong YF, et al. Long-term results of Leksell gamma knife surgery for trigeminal schwannomas. *J Neurosurg* 2005;102 (Suppl):220-4.
 77. Sun J, Zhang J, Yu X, Qi S, Du Y, Ni W, et al. Stereotactic radiosurgery for trigeminal schwannoma: A clinical retrospective study in 52 cases. *Stereotact Funct Neurosurg* 2013;91:236-42.
 78. Hasegawa T, Kato T, Kida Y, Sasaki A, Iwai Y, Kondoh T, et al. Gamma knife surgery for patients with jugular foramen schwannomas: A multiinstitutional retrospective study in Japan. *J Neurosurg* 2016;125:822-31.
 79. D'Astous M, Ho AL, Pendharkar A, Choi CY, Soltys SG, Gibbs IC, et al. Stereotactic radiosurgery for non-vestibular cranial nerve schwannomas. *J Neurooncol* 2017;131:177-83.
 80. Elsharkawy M, Xu Z, Schlesinger D, Sheehan JP. Gamma knife surgery for non-vestibular schwannomas: Radiological and clinical outcomes. *J Neurosurg* 2012;116:66-72.
 81. Sheehan J, Yen CP, Arkha Y, Schlesinger D, Steiner L. Gamma knife surgery for trigeminal schwannoma. *J Neurosurg* 2007;106:839-45.
 82. Santacroce A, Walier M, Régis J, Liščák R, Motti E, Lindquist C, et al. Long-term tumor control of benign intracranial meningiomas after radiosurgery in a series of 4565 patients. *Neurosurgery* 2012;70:32-9.
 83. Boari N, Bailo M, Gagliardi F, Franzin A, Gemma M, del Vecchio A, et al. Gamma knife radiosurgery for vestibular schwannoma: Clinical results at long-term follow-up in a series of 379 patients. *J Neurosurg* 2014;121 (Suppl):123-42.
 84. Watanabe S, Yamamoto M, Kawabe T, Koiso T, Yamamoto T, Matsumura A, et al. Stereotactic radiosurgery for vestibular schwannomas: Average 10-year follow-up results focusing on long-term hearing preservation. *J Neurosurg* 2016;125:64-72.
 85. van de Langenberg R, de Bondt BJ, Nelemans PJ, Baumert BG,

- Stokroos RJ. Follow-up assessment of vestibular schwannomas: Volume quantification versus two-dimensional measurements. *Neuroradiology* 2009;51:517-24.
86. DiBiase SJ, Kwok Y, Yovino S, Arena C, Naqvi S, Temple R, et al. Factors predicting local tumor control after gamma knife stereotactic radiosurgery for benign intracranial meningiomas. *Int J Radiat Oncol Biol Phys* 2004;60:1515-9.
87. Rogers L, Jensen R, Perry A. Chasing your dural tail: Factors predicting local tumor control after gamma knife stereotactic radiosurgery for benign intracranial meningiomas: In regard to DiBiase et al. (Int J Radiat Oncol Biol Phys 2004;60:1515-1519). *Int J Radiat Oncol Biol Phys* 2005;62:616-8.
88. van de Langenberg R, Dohmen AJ, de Bondt BJ, Nelemans PJ, Baumert BG, Stokroos RJ. Volume changes after stereotactic LINAC radiotherapy in vestibular schwannoma: Control rate and growth patterns. *Int J Radiat Oncol Biol Phys* 2012;84:343-9.
89. Hughes M, Skilbeck C, Saeed S, Bradford R. Expectant management of vestibular schwannoma: A retrospective multivariate analysis of tumor growth and outcome. *Skull Base* 2011;21:295-302.
90. Wegner RE, Hasan S, Abel S, Anderson S, Fuhrer R, Williamson RW, et al. Linear accelerator-based stereotactic radiotherapy for low-grade meningiomas: Improved local control with hypofractionation. *J Cent Nerv Syst Dis* 2019;11:1179573519843880.
91. Nakamura H, Jokura H, Takahashi K, Boku N, Akabane A, Yoshimoto T. Serial follow-up MR imaging after gamma knife radiosurgery for vestibular schwannoma. *AJNR Am J Neuroradiol* 2000;21:1540-6.
92. Patibandla MR, Lee CC, Sheehan J. Stereotactic radiosurgery of central skull base meningiomas-volumetric evaluation and long-term outcomes. *World Neurosurg* 2017;108:176-84.
93. Cohen-Inbar O, Tata A, Moosa S, Lee CC, Sheehan JP. Stereotactic radiosurgery in the treatment of parasellar meningiomas: Long-term volumetric evaluation. *J Neurosurg* 2018;128:362-72.
94. Jensen RL, Jensen PR, Shrieve AF, Hazard L, Shrieve DC. Overall and progression-free survival and visual and endocrine outcomes for patients with parasellar lesions treated with intensity-modulated stereotactic radiosurgery. *J Neurooncol* 2010;98:221-31.
95. dos Santos MA, de Salcedo JB, Gutiérrez Diaz JA, Calvo FA, Samblás J, Marsiglia H, et al. Long-term outcomes of stereotactic radiosurgery for treatment of cavernous sinus meningiomas. *Int J Radiat Oncol Biol Phys* 2011;81:1436-41.
96. Martinez-Perez R, Florez-Perdomo W, Freeman L, Ung TH, Youssef AS. Long-term disease control and treatment outcomes of stereotactic radiosurgery in cavernous sinus meningiomas. *J Neurooncol* 2021;152:439-49.
97. Spiegelmann R, Nissim O, Menhel J, Alezra D, Pfeffer MR. Linear accelerator radiosurgery for meningiomas in and around the cavernous sinus. *Neurosurgery* 2002;51:1373-79.
98. Warrington AP, Laing RW, Brada M. Quality assurance in fractionated stereotactic radiotherapy. *Radiother Oncol* 1994;30:239-46.
99. Carminucci A, Nie K, Weiner J, Hargreaves E, Danish SF. Assessment of motion error for frame-based and noninvasive mask-based fixation using the Leksell Gamma Knife Icon radiosurgery system. *J Neurosurg* 2018;129:133-9.
100. Ahn KH, Yenice KM, Koshy M, Slavin KV, Aydogan B. Frame-based radiosurgery of multiple metastases using single-isocenter volumetric modulated arc therapy technique. *J Appl Clin Med Phys* 2019;20:21-8.
101. Das IJ, Downes MB, Corn BW, Curran WJ, Werner-Wasik M, Andrews DW. Characteristics of a dedicated linear accelerator-based stereotactic radiosurgery-radiotherapy unit. *Radiother Oncol* 1996;38:61-8.
102. Brezovich IA, Wu X, Popple RA, Covington E, Cardan R, Shen S, et al. Stereotactic radiosurgery with MLC-defined arcs: Verification of dosimetry, spatial accuracy, and end-to-end tests. *J Appl Clin Med Phys* 2019;20:84-98.
103. Stern RL, Perks JR, Pappas CT, Boggan JE, Chen AY. The option of Linac-based radiosurgery in a Gamma Knife radiosurgery center. *Clin Neurol Neurosurg* 2008;110:968-72.
104. Park HS, Wang EH, Rutter CE, Corso CD, Chiang VL, Yu JB. Changing practice patterns of Gamma Knife versus linear accelerator-based stereotactic radiosurgery for brain metastases in the US. *J Neurosurg* 2016;124:1018-24.
105. Pollock BE, Link MJ, Stafford SL, Parney IF, Garces YI, Foote RL. The risk of radiation-induced tumors or malignant transformation after single-fraction intracranial radiosurgery: Results based on a 25-year experience. *Int J Radiat Oncol Biol Phys* 2017;97:919-23.