



## Original Article

# Extreme horseshoe and circumanal anal fistulas-challenges in diagnosis and management

Pankaj Garg<sup>a\*</sup>, Baljit Kaur<sup>b</sup>, Vipul D. Yagnik<sup>c</sup>, Geetha R. Menon<sup>d</sup>

<sup>a</sup>Department of Colorectal Surgery, Indus International Hospital, Mohali, Punjab, India, <sup>b</sup>Department of Radiodiagnosis, SSRD Imaging Centre, Chandigarh, India, <sup>c</sup>Department of Surgical Gastroenterology, Nishtha Surgical Hospital and Research Centre, Patan, Gujarat, India, <sup>d</sup>Indian Council of Medical Research, National Institute of Medical Statistics, New Delhi, India

Submission : 02-Dec-2020  
Revision : 04-Feb-2021  
Acceptance : 09-Feb-2021  
Web Publication : 01-Apr-2021

### ABSTRACT

**Objectives:** Extreme horseshoe anal fistulas are rare, and there are little data on the diagnosis and management of these fistulas. **Materials and Methods:** Patients with horseshoe anal fistula, in which the fistula tract encircled more than 75% of the anal circumference were included in the study. All patients were assessed by a preoperative magnetic resonance imaging (MRI). The patients were managed by a sphincter-sparing procedure. The continence was evaluated by an objective continence scoring system (Vaizey's scores). **Results:** 1059 anal fistula patients were operated on over 7-years with a median follow-up of 36 months (range: 5–79 months). There were 47/1059 (4.4%) patients with extreme horseshoe anal fistulas. In 4/47 patients, the fistulas were complete circumanal (encircling anal canal completely). The mean age was  $39.5 \pm 10.9$  years, M/F-41/6. The fistula was supralelevator in 12/47 (25.5%), had an associated abscess in 28/47 (59.6%), and was recurrent in 33/47 (70.2%) patients. The tracts were intersphincteric in 27/47, transsphincteric in 2/47, and both (intersphincteric and transsphincteric) in 18/47 patients. All patients ( $n = 47$ ) were managed by a sphincter-sparing procedure. Four patients were lost to follow-up. The fistula healed completely in 34/43 (79%) patients. There was no significant difference between preoperative and postoperative Vaizey's continence scores  $0.031 \pm 0.17$  and  $0.033 \pm 0.18$  respectively ( $P=0.90$ , Mann-Whitney U-test). **Conclusion:** Extreme horseshoe fistulas are rare, with an incidence of about 4% (in a referral practice). The missed diagnosis of circumferential tracts could lead to a recurrence. MRI was pivotal to confirm the diagnosis. Proper identification and management of internal opening and adequate drainage of all tracts were crucial for successfully treating extreme horseshoe fistulas.

**KEYWORDS:** Anal fistula, Circumferential, Extreme, Horseshoe, Incontinence, Magnetic resonance imaging

## INTRODUCTION

Horseshoe fistula tracts are common among complex fistula and occur in about 20% of complex fistulas [1,2]. Horseshoe fistula are the fistulas in which the fistula tracts encircle the anal canal and form a horseshoe figure. Extreme horseshoe fistulas are rare, and there is no literature available which describes the characteristics and management of such fistulas. We retrospectively analyzed our data for the incidence and management of extreme horseshoe fistulas.

## MATERIALS AND METHODS

In this retrospective study, all patients of anal fistula operated at a single center by a single surgeon (PG) between July 2013 and February 2020 were screened. As the study

center was a referral center for anal fistulas, preoperative magnetic resonance imaging (MRI) was done in all the patients, and a schematic diagram was made for each of them [Figures 1-4]. Patients with horseshoe anal fistula in which the fistula tract encircled more than 75% of the anal circumference were defined as extreme horseshoe fistulas. During the study, the schematic diagrams were initially screened to shortlist the extreme horseshoe fistulas. Then the MRI scans of the shortlisted cases were analyzed in detail

### \*Address for correspondence:

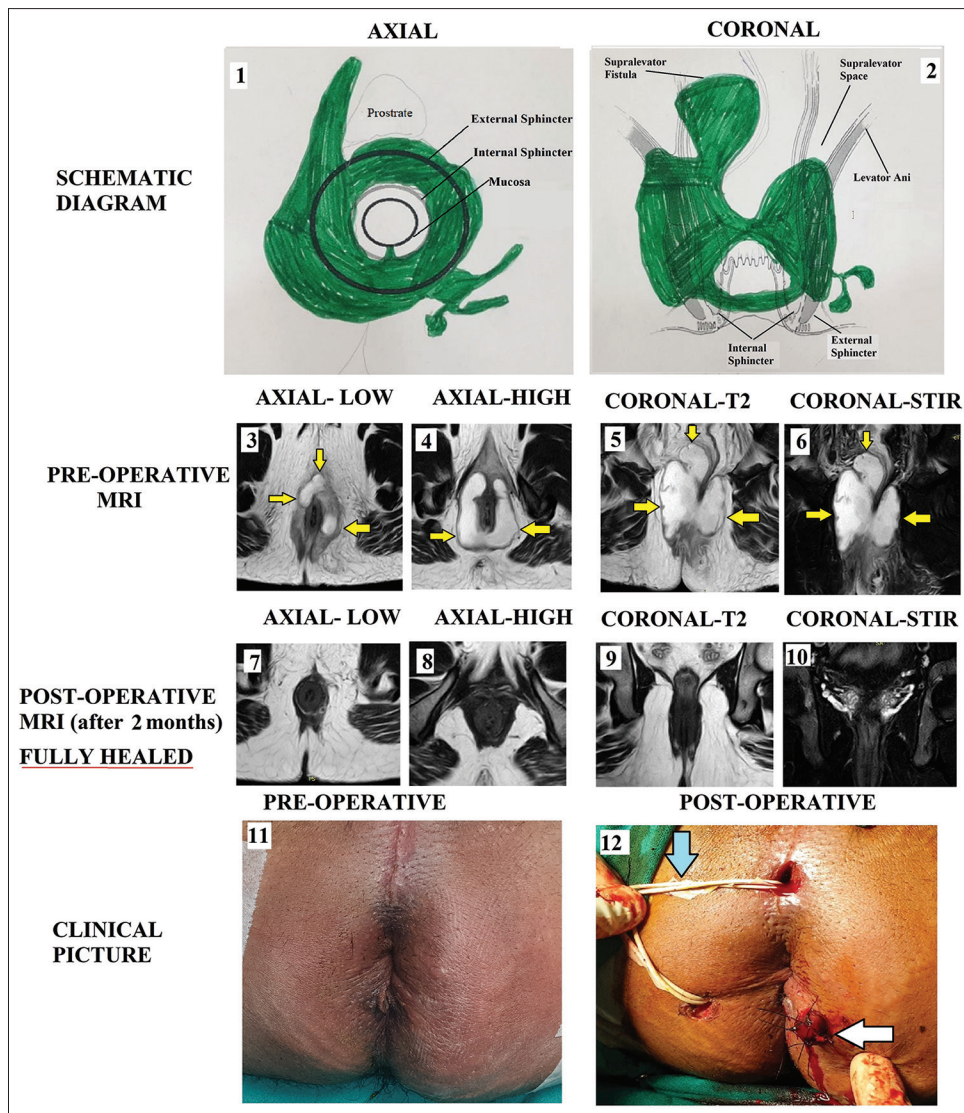
Dr. Pankaj Garg,  
Department of Colorectal Surgery, Indus International Hospital, Mohali,  
Punjab, 140507, India.  
E-mail: [drgargpankaj@yahoo.com](mailto:drgargpankaj@yahoo.com)

This is an open access journal, and articles are distributed under the terms of the Creative Commons Attribution-NonCommercial-ShareAlike 4.0 License, which allows others to remix, tweak, and build upon the work non-commercially, as long as appropriate credit is given and the new creations are licensed under the identical terms.

For reprints contact: [WKHLRPMedknow\\_reprints@wolterskluwer.com](mailto:WKHLRPMedknow_reprints@wolterskluwer.com)

**How to cite this article:** Garg P, Kaur B, Yagnik VD, Menon GR. Extreme horseshoe and circumanal anal fistulas-challenges in diagnosis and management. Tzu Chi Med J 2021; 33(4): 374-9.

Access this article online	
Quick Response Code: 	Website: <a href="http://www.tcmjmed.com">www.tcmjmed.com</a>
	DOI: 10.4103/tcmj.tcmj_287_20



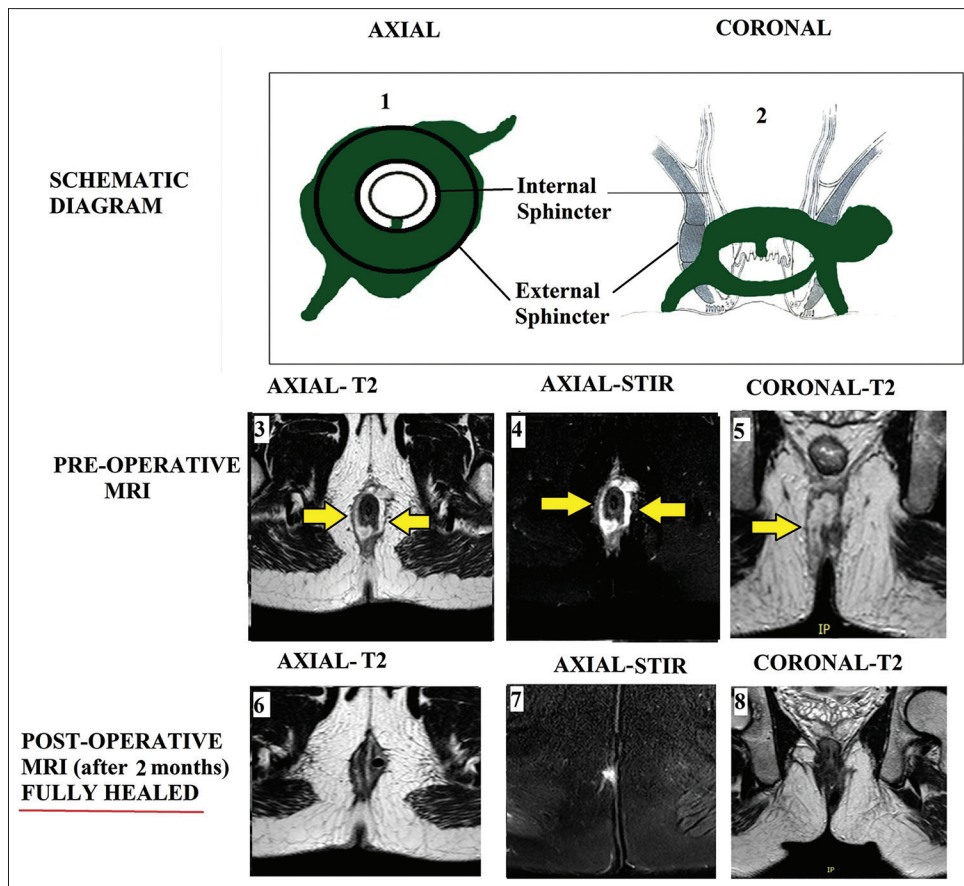
**Figure 1:** A 31-year-old male patient presented in septicemia with a huge complete circumanal abscess and fistula. He underwent the transanal opening of intersphincteric space (TROPIS) procedure and the fistula healed completely in two months. Schematic diagram-Panel-1: Axial section, Panel-2: Coronal section, Preoperative-Panel-3: magnetic resonance imaging-Axial section (low level), Panel-4: magnetic resonance imaging-Axial section (high level), Panel-5: magnetic resonance imaging-Coronal section (T2), Panel-6: magnetic resonance imaging-Coronal section (STIR). Postoperative (After two months- Fistula healed completely)-Panel-7: magnetic resonance imaging-Axial section (low level), Panel-8: magnetic resonance imaging-Axial section (high level), Panel-9: magnetic resonance imaging-Coronal section (T2), Panel-10: magnetic resonance imaging-Coronal section (STIR). Clinical picture-Panel-11: Preoperative, Panel-12: Postoperative image showing a wide tube (abdominal drain kit tube) in the high abscess cavity (white arrow) and a loose seton passing from 8 o'clock position to 12 o'clock position in the circumrectal tract (blue arrow) but not through the internal opening (yellow arrows show fistula tracts)

to confirm the presence of an extreme horseshoe fistula. The fistulas proved to be extreme horseshoe on MRI scans were finally included in the study.

Since fistulotomy was not possible in these patients, these patients were operated on by a sphincter-saving procedure-transanal opening of intersphincteric space (TROPIS) [2-6]. TROPIS is quite similar to the ligation of intersphincteric fistula tract (LIFT) procedure with a slight modification. Unlike LIFT, in which the fistula tract is ligated and cut in the intersphincteric plane, in TROPIS, the intersphincteric portion of the fistula is laid open (deroofed) into the anal canal [Figure 3] [6]. The deroofing is done so that the intersphincteric part of the fistula tract is thoroughly drained, and the drainage of pus persists even in the postoperative

period. This ensures healing of the intersphincteric portion of the fistula tract by secondary intention [2-5].

The transsphincteric tracts in the ischioanal fossa were curetted and cleaned from the external (secondary) openings and a tube was inserted into the transsphincteric tracts up to the level of the external sphincter. The tube was sutured to the skin [Figure 1]. Once the wound inside the anal canal was healed by secondary intention, the tube (or tubes in case of multiple tracts) was taken out. Thus, without cutting or damaging the external sphincter, the tracts on both sides of the external sphincter were dealt with-the tract inner to external sphincter (intersphincteric tract and internal opening) from inside the rectum and tracts outside the external sphincter (tracts in ischioanal fossa) from outside through



**Figure 2:** A 21-year-old male patient presented with a complete circumanal recurrent fistula. He underwent the transanal opening of intersphincteric space (TROPIS) procedure and the fistula healed completely in two months. Schematic diagram-Panel-1: Axial section, Panel-2: Coronal section, Preoperative-Panel-3: magnetic resonance imaging-Axial section (T2), Panel-4: magnetic resonance imaging-Axial section (STIR), Panel-5: magnetic resonance imaging-Coronal section. Postoperative (After two months- Fistula healed completely)-Panel-6: magnetic resonance imaging-Axial section (T2), Panel-7: magnetic resonance imaging-Axial section (STIR), Panel-8: magnetic resonance imaging-Coronal section (yellow arrows show the fistula tracts)

external openings. The regular drainage and avoidance of collection in all external tracts in the ischioanal fossa was pertinent till the intrarectal wound was completely healed. For deep straight tracts, a tube was compatible, but tube insertion was not possible for a curved tract in the ischioanal fossa. A loose seton was inserted for drainage for circumferential tracts, wherever necessary [Figures 1 and 3]. This seton was inserted in external perianal curved tracts from one external opening to another external opening. This seton was not passed through the internal opening because that would have prevented the internal opening's closure [Figures 1 and 3].

The patients were followed by monthly visits to the clinic. Once the healing was complete, the follow-up was done telephonically or on what's app. The fistula was considered healed when there was a complete cessation of pus discharge from the anus and all the tracts. Continuous or persistent discharge of pus from even a single tract (in fistula with multiple tracts) was considered as a failure of the treatment.

The following parameters were analyzed: the position of the internal (primary) opening, whether the tracts were intersphincteric, transsphincteric (perianal), or both, supraleator extension, horseshoe fistula, recurrent fistula, associated abscess, the procedure done on the patient, and

the number of fistulas which healed. The continence was evaluated by Vaizey's continence scoring [7] preoperatively and postoperatively (at three months). This scoring assessed six parameters-incontinence to gas, liquid or solid, any alteration in lifestyle, any need to take constipation medicines, inability to hold defecation for 15 min, and need to wear a pad. A score of zero would imply perfect continence, and a score of 24 would mean that the patient was incontinent [7]. Vaizey's scores were used as this is more comprehensive than other scoring systems.

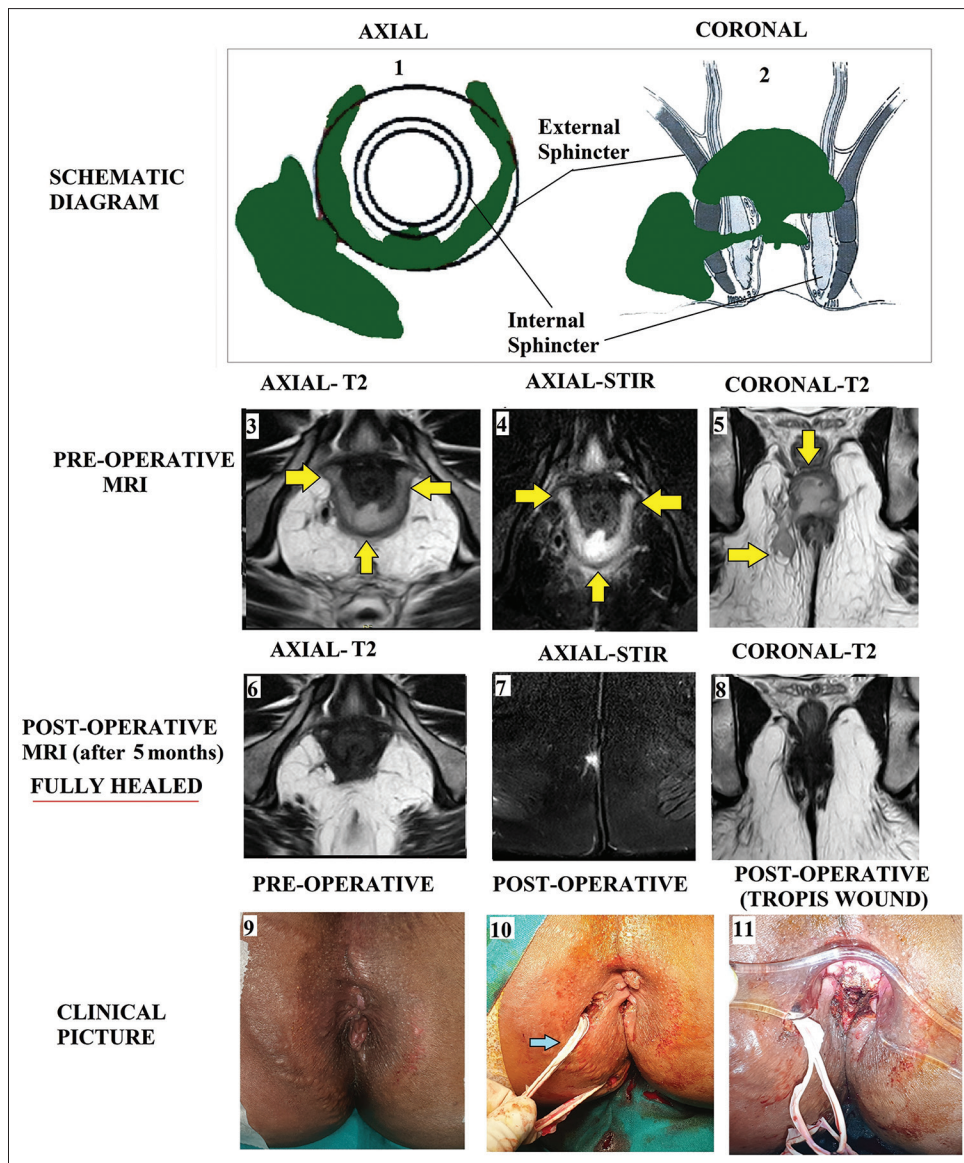
Ethical approval for this study (Ethical Committee N EC/ IHH-IEH/SP6) was provided by the Ethical Committee of Indus International Hospital Ethics Committee on March 26, 2020. Informed written consent was waived because the study was a retrospective data analysis.

**Statistical analysis**

The categorical variables were compared by performing Fisher's exact test or Chi-squared analysis. When the data were normally distributed, the continuous variables were analyzed by *t*-test when there were two samples or ANOVA test when there were more than two samples.

If the data were not distributed normally, Wilcoxon signed-rank test was applied for paired samples, and the





**Figure 3:** A 34-year-old male patient presented with extreme horseshoe fistula and an abscess in the right ischio-rectal fossa. He underwent the transanal opening of intersphincteric space (TROPIS) procedure and the fistula healed completely in three months. Schematic diagram-Panel-1: Axial section, Panel-2: Coronal section, Preoperative-Panel-3: magnetic resonance imaging-Axial section (T2), Panel-4: magnetic resonance imaging-Axial section (STIR), Panel-5: magnetic resonance imaging-Coronal section (T2). Postoperative (After five months- Fistula healed)-Panel-6: magnetic resonance imaging-Axial section (T2), Panel-7: magnetic resonance imaging-Axial section (STIR), Panel-8: magnetic resonance imaging-Coronal section (T2). Clinical picture-Panel-9: Preoperative, Panel-10: Postoperative image showing a loose seton passing from 7 o'clock position to 11 o'clock position in the circum-rectal tract (blue arrow) but not through the internal opening, Panel-11: Postoperative picture showing the transanal opening of intersphincteric space wound at the posterior midline (yellow arrows showing fistula tracts)

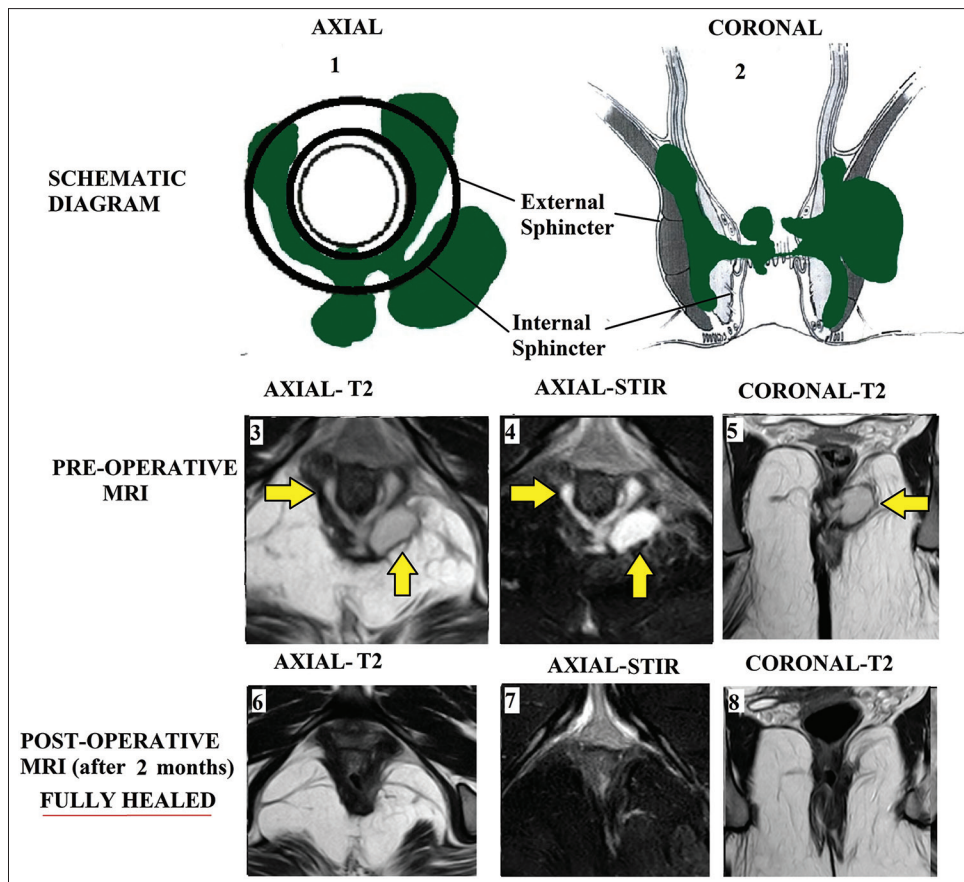
Mann-Whitney U test was performed for unpaired samples. The significant cut-off point was set at  $P < 0.05$ .

## RESULTS

One thousand and fifty-nine fistula patients were operated on over seven years with a median follow-up of 36 months (range: 5–79 months). The mean age was  $39.5 \pm 10.9$  years, and the M/F ratio was 41/6. There were 206/1059 (19.4%) horseshoe fistula, and out of these, there were 47/1059 (4.4%) extreme horseshoe fistula. 4/47 were “complete circumanal” fistulas as they were encircling the anal canal completely [Figures 1 and 2]. There was supralelevator extension of fistula in 12/47 (25.5%) patients, an associated

abscess in 28/47 (59.6%), and recurrent fistula in 33/47 (70.2%) patients [Table 1]. The internal opening was at the posterior midline in 40/47 (85.1%), anterior midline in 4/47 (8.5%), and at both (anterior + posterior midline) locations in 3/47 (6.4%) patients. The horseshoe fistula tracts were intersphincteric in 27/47 (57.4%), transsphincteric (in ischio-rectal fossa) in 2/47 (4.3%), and in both intersphincteric and transsphincteric regions in 18/47 (38.3%) patients [Table 1].

Four patients were lost to follow-up. In 43 patients, the fistula healed in 32/43 (74.4%) of them. Four patients were reoperated, and in two of them, the fistulas healed completely. Thus, the overall healing rate was 34/43 (79%) patients. The difference between preoperative and postoperative Vaizey’s continence scores



**Figure 4:** A 31-year-old female patient presented with extreme horseshoe recurrent fistula. She underwent the transanal opening of intersphincteric space (TROPIS) procedure and the fistula healed completely in two months. Schematic diagram-Panel-1: Axial section, Panel-2: Coronal section, Preoperative-Panel-3: magnetic resonance imaging-Axial section (T2), Panel-4: magnetic resonance imaging-Axial section (STIR), Panel-5: magnetic resonance imaging-Coronal section. Postoperative (After two months- Fistula healed)-Panel-6: magnetic resonance imaging-Axial section (T2), Panel-7: magnetic resonance imaging-Axial section (STIR), Panel-8: magnetic resonance imaging-Coronal section (yellow arrows show fistula tract/ abscess)

was  $0.031 \pm 0.17$  and  $0.033 \pm 0.18$ , respectively, and was also not significantly different ( $P = 0.90$ , Mann-Whitney U-test) [Table 1].

## DISCUSSION

Extreme horseshoe fistulas are relatively uncommon, with hardly any literature published on this topic. This is the first study that has analyzed and highlighted the diagnosis and management of such fistulas. The extreme horseshoe fistulas were quite complex fistulas. This could be gauged from the fact that the fistulas were recurrent in 70% of patients, there was associated abscess in 60%, and there was a supralelevator extension in 25% of cases.

The diagnosis and management of extreme horseshoe fistulas presented few challenges. The diagnosis was challenging because it was difficult to diagnose an extreme horseshoe fistula on clinical examination alone. MRI, primarily the axial (transverse) section, made these fistulae's diagnosis relatively easy [Figures 1-4] [8-11]. Needless to say, the proper diagnosis was mandatory for successful treatment. A missed circumferential tract would have led to a recurrence.

There were few critical issues in the management of extreme horseshoe fistulas. First was the accurate location of the internal opening. In some cases, when the fistula

tract was encircling anorectum almost completely, it became difficult to locate the internal opening even on MRI scan [Figures 1 and 2]. In such cases, feeling induration during per rectal examination on the operating table provided an invaluable clue to the internal opening site. Moreover, in horseshoe fistulas' internal opening is invariably present in the posterior (mostly) or anterior (occasionally) midline. The present study also corroborated this fact.

The second key issue in the management was adequate and persistent drainage of circumferential horseshoe tracts till the internal opening had healed. The internal opening might be managed by any method comfortable to the operating surgeon like LIFT, advancement flap, or TROPIS procedure [1,12-15]. However, caution must be exercised in managing the circumferential tracts. These tracts could not be laid open as that would have increased the risk of anal stenosis or stricture formation in the postoperative period. Once the internal opening was properly managed, the circumferential horseshoe tracts were best addressed by adequate drainage. This was conveniently done with a high degree of success by using single or multiple loose setons [Figures 1 and 3] without needing to open the curved tracts in any of the patients. The seton was inserted to drain different segments of circumferential tracts and was not passed through the internal opening [Figures 1 and 3].

**Table 1: Extreme horseshoe anal fistulas-patient parameters and results**

	Circumrectal fistula (n=47) (complete-4, incomplete-43)
Age (years)	39.5±10.9
Male/female	41/6
Suprlevator, n (%)	12/47 (25.5)
Associated abscess, n (%)	28/47 (59.6)
Recurrent, n (%)	33/47 (70.2)
Position of internal opening, n (%)	Posterior midline - 40/47 (85.1) Anterior midline - 4/47 (8.5) Both (anterior + posterior midline) - 3/47 (6.4)
Position of circumrectal tract, n (%)	Intersphincteric - 27/47 (57.4) Transsphincteric (in ischiorectal fossa) - 2/47 (4.3) Both intersphincteric and transsphincteric - 18/47 (38.3)
Fistula healing, n (%)	34/43 (79) (4 - lost to follow-up)
Incontinence scores (Vaizey's scores)	Preoperative - 0.031±0.17 Postoperative - 0.033±0.18 P=0.90 (Mann-Whitney U-test)

Extreme horseshoe anal fistulas-involving >75% anorectal circumference

The latter would have prevented the closure of the internal opening and thus prevented fistula healing. Once the internal opening healed completely, the setons were taken out.

The healing was assessed clinically when all the tracts had completely healed, and there was a cessation of pus discharge from all the tracts. However, the postoperative MRI was done wherever the patient was keen to confirm the fistula healing [Figures 1-4]. Since a high proportion of patients had recurrent fistulas (70%), many were eager to get the postoperative MRI to confirm the fistula healing. Therefore, postoperative MRI was done in 23/43 (53.4%). Recent studies in many patients showed that postoperative MRI was highly accurate in predicting the closure of internal opening and fistula tract healing, which correlated quite well with long-term fistula healing [8,9].

There were few limitations in the study. First, it was a retrospective study. Second, there was no control group.

## CONCLUSIONS

Extreme horseshoe fistulas are rare, but they must be looked at carefully in all horseshoe looking fistulas. The missed tracts could lead to a recurrence. MRI or transrectal ultrasound would be pivotal to confirm the diagnosis. Proper management of

internal opening and adequate drainage of the circumferential tracts is critical to successfully treat these circumanal fistulas.

## Financial support and sponsorship

Nil.

## Conflicts of interest

There are no conflicts of interest.

## REFERENCES

- Emile SH, Khan SM, Adejumo A, Koroye O. Ligation of intersphincteric fistula tract (LIFT) in treatment of anal fistula: An updated systematic review, meta-analysis, and meta-regression of the predictors of failure. *Surgery* 2020;167:484-92.
- Garg P. Transanal opening of intersphincteric space (TROPIS)-A new procedure to treat high complex anal fistula. *Int J Surg* 2017;40:130-4.
- Garg P. A new understanding of the principles in the management of complex anal fistula. *Med Hypotheses* 2019;132:109329.
- Garg P. Understanding and treating suprlevator fistula-in-ano: MRI analysis of 51 cases and a review of literature. *Dis Colon Rectum* 2018;61:612-21.
- Garg P. Multiple openings in the anterior abdominal wall draining pus for a decade. *Gastroenterology* 2017;153:e12-3.
- Garg P, Kaur B, Menon GR. Transanal opening of the intersphincteric space: a novel sphincter-sparing procedure to treat 325 high complex anal fistulas with long-term follow-up. *Colorectal Dis* 2021;23:1213-24.
- Vaizey CJ, Carapeti E, Cahill JA, Kamm MA. Prospective comparison of faecal incontinence grading systems. *Gut* 1999;44:77-80.
- Garg P. Comparison of preoperative and postoperative MRI after fistula-in-ano surgery: Lessons learnt from an audit of 1323 MRI at a single centre. *World J Surg* 2019;43:1612-22.
- Garg P, Singh P, Kaur B. Magnetic resonance imaging (MRI): Operative findings correlation in 229 fistula-in-ano patients. *World J Surg* 2017;41:1618-24.
- Erden A. MRI of anal canal: normal anatomy, imaging protocol, and perianal fistulas: Part 1. *Abdom Radiol (NY)* 2018;43:1334-52.
- Erden A. MRI of anal canal: common anal and perianal disorders beyond fistulas: Part 2. *Abdom Radiol (NY)* 2018;43:1353-67.
- Zhao B, Wang Z, Han J, Zheng Y, Cui J, Yu S. Long-term outcomes of ligation of the inter-sphincteric fistula tract plus bioprosthetic anal fistula plug (LIFT-Plug) in the treatment of trans-sphincteric perianal fistula. *Med Sci Monit* 2019;25:1350-4.
- Hong KD, Kang S, Kalaskar S, Wexner SD. Ligation of intersphincteric fistula tract (LIFT) to treat anal fistula: systematic review and meta-analysis. *Tech Coloproctol* 2014;18:685-91.
- van Koperen PJ, Wind J, Bemelman WA, Slors JF. Fibrin glue and transanal rectal advancement flap for high transsphincteric perianal fistulas; is there any advantage? *Int J Colorectal Dis* 2008;23:697-701.
- Chew SS, Adams WJ. Anal sphincter advancement flap for low transsphincteric anal fistula. *Dis Colon Rectum* 2007;50:1090-3.