



Original Article

Detection rate of breast malignancy of needle localization biopsy of breast microcalcification

Kian-Hwee Chong^a, Kuo-Feng Huang^{b,c}, Hsiu-Wen Kuo^d, I-Shiang Tzeng^e, Jia-Hui Chen^{a,c,f,*}

^aDivision of General Surgery, Department of Surgery, Taipei Tzu Chi Hospital, Buddhist Tzu Chi Medical Foundation, New Taipei, Taiwan, ^bDivision of Neurosurgery, Department of Surgery, Taipei Tzu Chi Hospital, Buddhist Tzu Chi Medical Foundation, New Taipei, Taiwan, ^cSchool of Medicine, Tzu Chi University, Hualien, Taiwan, ^dDepartment of Radiology, Taipei Tzu Chi Hospital, Buddhist Tzu Chi Medical Foundation, New Taipei, Taiwan, ^eDepartment of Research, Taipei Tzu Chi Hospital, Buddhist Tzu Chi Medical Foundation, New Taipei, Taiwan, ^fInstitute of Medical Sciences, Tzu Chi University, Hualien, Taiwan

Submission : 26-Jul-2020
Revision : 11-Sep-2020
Acceptance : 25-Sep-2020
Web Publication : 22-Mar-2021

ABSTRACT

Objective: The current study aimed to retrospectively assess the cancer detection rate of needle localization biopsy of breast microcalcifications undetectable on sonography. **Materials and Methods:** Patients who underwent mammography-guided needle localization biopsy of breast microcalcifications undetectable on sonography from January 2005 to December 2017 were included in the study. Patients with incomplete medical records were excluded from the study. Patient mammograms were categorized using the Breast Imaging-Reporting and Data System (BI-RADS) assessment criteria. The percentages of benign and malignant lesions were determined by pathological examination of surgically recovered specimens. Correlation between preoperative imaging assessment and final diagnosis was investigated, and the complications associated with the procedures were recorded. **Results:** A total of 301 needle-localized biopsies were performed under mammographic guidance. The mean age of the patients was 58.18 ± 7.73 years. The overall ductal carcinoma *in situ* (DCIS) and cancer detection rate was 23.3%. The proportion of patients with BI-RADS 0 category and undergoing second mammography was higher in the DCIS and cancer group. A total of 227 patients did not undergo second mammography. Of these patients, 70 demonstrated BI-RADS 4 category, 34 were diagnosed with DCIS, and 5 were diagnosed with breast cancer during subsequent follow-up. **Conclusion:** Needle-localized excision of microcalcifications undetectable on sonography has high detection rate for early stage of breast cancer with low risk of associated complications. Regular mammography is a satisfactory follow-up tool for female patients with microcalcifications in the breasts. Additional studies should be performed to compare between needle-localized excision and vacuum-assisted breast biopsy.

KEYWORDS: Breast cancer, Microcalcification, Needle localization excision, Screening mammography, Vacuum-assisted breast biopsy

INTRODUCTION

Breast cancer, which comprises 23% of all cancer cases globally, is the most prevalent cancer, and contributes to 14% of cancer deaths annually [1]. Early diagnosis of breast cancer has been achieved by the increasing application of mammography. This diagnostic tool has improved the therapeutic success rate of breast cancer.

Clustered microcalcifications are accepted as one of the early signs of breast cancer, and mammography is considered a favorable diagnostic tool for detection and categorization of the lesions [2,3]. However, the malignant lesion is not easily differentiated from the clustered microcalcifications on mammography [4]. Identification of microcalcifications on breast ultrasound is challenging when camouflaged by the echogenic and fibroglandular breast tissue. Limited

studies have reported the detection of microcalcifications using sonography [5].

Clustered microcalcifications detected on mammography are commonly further diagnosed using either needle-localized surgical excision or stereotactic-guided percutaneous core needle biopsy. Needle-localized surgical excision was introduced in 1965 to obtain tissue sample of clustered microcalcifications for diagnosis of the pathology. A radiopaque wire is inserted percutaneously into the

*Address for correspondence:

Dr. Jia-Hui Chen,
Division of General Surgery, Department of Surgery, Taipei Tzu Chi Hospital, Buddhist Tzu Chi Medical Foundation, 289, Jianguo Road, Xindian District, New Taipei, Taiwan.
E-mail: procto77@gmail.com

This is an open access journal, and articles are distributed under the terms of the Creative Commons Attribution-NonCommercial-ShareAlike 4.0 License, which allows others to remix, tweak, and build upon the work non-commercially, as long as appropriate credit is given and the new creations are licensed under the identical terms.

For reprints contact: WKHLRPMedknow_reprints@wolterskluwer.com

How to cite this article: Chong KH, Huang KF, Kuo HW, Tzeng IS, Chen JH. Detection rate of breast malignancy of needle localization biopsy of breast microcalcification. Tzu Chi Med J 2021;33:275-81.

Access this article online	
Quick Response Code: 	Website: www.tcmjmed.com
	DOI: 10.4103/tcmj.tcmj_191_20

lesion by a radiologist under sonography or mammography guidance. Accurate excision of the lesion is achieved under wire guidance and any excessive surgical trauma could be minimized [6-8]. Needle localization biopsy is considered the most precise technique with minimal rate of associated complications.

The current study aimed to assess the effectiveness of mammography-guided needle localization biopsy for clustered microcalcifications. The study also evaluated the association between preoperative imaging evaluation and pathological results, to define its value in diagnosis and prevent any related complications.

MATERIALS AND METHODS

The institutional review board No. 06-X09-024 of the Buddhist Taipei Tzu Chi Hospital, Buddhist Tzu Chi Medical Foundation, approved this retrospective study. The medical chart review did not necessitate patient agreement. Mammography-guided excision biopsy was performed after informed consent was obtained from all patients.

Patients

Patients scheduled to undergo needle localization excision biopsy between January 2015 and December 2017 were enrolled in the current study. Clustered microcalcifications were detected by mammography. Exclusion criteria of patients were as follows: presence of a tumor in the microcalcifications, features of the microcalcifications could not be confirmed by pathological examination, history of mammographic follow-up in <6 months prior to the study, or incomplete medical records. Age of the included female patients was between 40 and 82 years at the time of needle localization excision biopsy (mean age [\pm standard deviation], 58.18 \pm 7.73 years). The presence of malignancy in a suspicious lesion was determined by pathological analysis. The final study cohort included 301 patients. Patient mammographs were categorized using Breast Imaging-Reporting and Data System (BI-RADS) assessment criteria. The association between preoperative image evaluation and definitive pathologic results was investigated and any associated complications were recorded.

Mammography

Microcalcifications were categorized as per the BI-RADS guidelines, based on a consensus between two breast radiologists, each with more than 5 years of experience in reading mammography images. The lesions were categorized as probably benign (BI-RADS 3), with suspected malignancy (BI-RADS 4), or highly suggestive of malignancy (BI-RADS 5). Due to the broad spectrum and the corresponding wide range of risk of malignancy in the BI-RADS 4 category, this group was subclassified as Groups 4A, 4B, and 4C. Follow-up was recommended for lesions categorized as probably benign (BI-RADS 3). Biopsy was performed in cases with a strong family history of breast cancer and in cases where the patient and referring physician expressed a particular concern.

Needle localization excision biopsy

Hook wire localization was performed using a fenestrated compression plate and a 20G hook wire needle (Hawkins II FlexStrand Breast localization needle; Argon, Frisco, Texas, USA) under a digital mammography (2000D, DR, GE, Bracknell, Berkshire, UK) guide. All procedures were performed as carefully as possible to avoid tissue damage or bleeding in the breast. Wire placement mammography was done with craniocaudal and true lateral projections. The localizing wire was placed within 5 mm of the entire lesion. After the procedure, the patients were bandaged and immediately transferred to the operating room for the subsequent surgical procedure. The excised specimen was viewed under magnification to confirm the adequate removal of tissue. The specimen was then diagnosed based on histopathological examination. The percentage of benign and malignant lesions was determined by pathological examination of the surgically removed specimens.

Follow-up

In patients with microcalcifications identified as benign on biopsy, follow-up included mammography at least 12 months after biopsy to ascertain carcinoma. For microcalcifications identified as malignant on biopsy, postsurgical histological diagnosis was used as the end point. In the current study, malignancy was defined as a pathologic diagnosis of invasive carcinoma or ductal carcinoma *in situ* (DCIS). Any lesion with an invasive component was categorized as an invasive carcinoma. High-risk lesions, including atypical ductal hyperplasia (ADH), atypical lobular hyperplasia, and lobular carcinoma *in situ*, were considered benign lesions for statistical analysis. All patients found to have ADH, lobular neoplasia, or columnar cell lesions with atypia (flat epithelial cell atypia) over the excision margin or patients with discordant results of pathological analysis on needle localized excision biopsy were recommended to undergo wider surgical excision.

Statistical analysis

The Shapiro-Wilk test was employed as a test for normality. Statistical significance was determined by the Student's *t*-test for continuous variables and Chi-square test for categorical variables. $P < 0.05$ was considered to indicate statistical significance. Logistic regression analysis was performed to evaluate the correlation between DCIS, cancer group, and second mammography follow-up after adjusting for other factors.

RESULTS

Of the 301 microcalcification lesions biopsied, 175 (58.13%) were cluster microcalcifications, 48 (15.94%) were pleomorphic microcalcifications, and 51 (16.94%) were regional microcalcifications based on mammography. [Figure 1] showed the flowchart of initial mammography report, microcalcification subtype, and final pathologic result. The 70 DCIS and cancer patients included 38 cases of cluster microcalcifications. The overall positive predictive value (PPV) of suspicious microcalcifications included in the current study was 23.3% (70/301). The 231 non-DCIS and noncancer patients included 137 cases of cluster

microcalcifications. The distribution of microcalcifications between the two groups was significantly different. Based on mammography, most patients were classified as BI-RADS category 0. Table 1 details the distribution of mammography, which was significantly different between the two groups. The number of patients in the DCIS and cancer groups who underwent two or more follow-up mammographies was higher than that in the non-DCIS and noncancer groups. In addition, a significant difference was observed in the number of patients at the second follow-up between DCIS and cancer groups. The survival percentage was not significantly different between the two groups. Table 2 illustrates the results of the logistic regression analysis. The age-adjusted odds ratio of second-time mammography follow-up patients to nonsecond-time mammography follow-up patients was 2.273. This implies that the probability of patients who belonged to the DCIS and cancer groups who underwent mammography for the second time was 2.273 times higher than that of patients who belonged to the non-DCIS and noncancer group. Only one patient had subcutaneous hematoma after the needle-localized excision procedure.

Seventy-four patients underwent second mammography at follow-up and 227 patients did not undergo the procedure for the second time. Among the 227 patients who did not undergo second mammography, 70 patients were classified into BI-RADS 4 category based on the first mammography [Table 3], 34 were diagnosed with DCIS, and 5 patients were diagnosed with breast cancer [Table 4].

In the current study, 44 patients were diagnosed with ADH based on the results of the needle-localized excision biopsy. Initial mammography of the patients included 27 (61.4%) BI-RADS 0, 1 (2.3%) BI-RADS 2, and 16 (36.3%) BI-RADS 4 categories [Table 5]. Forty-two patients were on regular follow-up and 40 patients were determined to have no breast cancer. One patient was diagnosed with DCIS and one with Stage IIIC breast cancer [Table 6].

DISCUSSION

From the initial mammography report, we suggested further magnified mammography and needle localization excision for indeterminate microcalcification. We then identified 70/301 cases (23.3%) with DCIS and breast cancer with mostly clustered microcalcification. Therefore, we suggested needle localization excision for all mammography suspicious microcalcification, which led to high DCIS and cancer detection rate. Only 74 patients received secondary mammography follow-up and 26 patients (35.1%) were diagnosed with DCIS and breast cancer. Due to higher DCIS and cancer detection rate from secondary mammography, we also suggested regular mammography follow-up after needle localization excision.

Screening of breast cancer reduced the mortality rate among female patients at risk, by approximately 20% [9]. An increase in the incidence of breast cancer was observed from 1970 to 1990, and randomized clinical trials demonstrated the efficacy of screening by mammography. Therefore, population-based

Table 1: Patient classification

(Total (n=301))	Mean±SD, frequency (%)			P
	Overall (n=301), n (%)	DCIS and cancer (n=70), n (%)	Non-DCIS and noncancer (n=231), n (%)	
Age (years)	58.18±7.73	57.80±7.94	58.29±7.68	0.649
Pattern measurements				
Cluster microcalcifications	175 (58.13)	38 (54.28)	137 (59.30)	0.006
Pleomorphic	48 (15.94)	18 (25.71)	30 (12.98)	
Regional	51 (16.94)	5 (7.14)	46 (19.91)	
Other	27 (8.99)	9 (12.85)	18 (7.79)	
Radiology (BI-RADS)				
0	186 (61.79)	35 (50.00)	151 (65.36)	0.029
1	-	-	-	
2	2	-	2	
3	11	1	10	
4	51	21	30	
4A	45	10	35	
4B	4	2	2	
4C	2	1	1	
Mammography follow-up times				
First mammography	301	70	231	0.008
Second mammography	74	26	48	
Third mammography	33	16	17	
Fourth mammography	9	3	6	
Fifth mammography	4	1	3	
Sixth mammography	1	1	0	
Seventh mammography	1	1	0	
Survival status	269 (89.36)	63 (90.00)	206 (89.17)	0.999

DCIS: Ductal carcinoma *in situ*, BI-RADS: Breast Imaging-Reporting and Data System, SD: Standard deviation

Table 2: Odds ratio of factors related to ductal carcinoma *in situ* and cancer

Factor	OR (95% CI)	P
Cluster microcalcifications	0.261 (0.026–2.564)	0.2494
Second mammography follow-up	2.273 (1.214–4.254)	0.0102
Age	0.993 (0.955–1.032)	0.7322

OR: Odds ratio, CI: Confidence interval

Table 3: Initial Breast Imaging-Reporting and Data System category and follow-up results of 227 patients without second mammography and 44 atypical ductal hyperplasia patients

BI-RADS/stage	227 patients without second mammography	44 ADH patients
0	148	27
1	-	-
2	1	1
3	8	-
4	40	6
4A	26	9
4B	3	1
4C	1	-
DCIS	34	1
Stage I	1	-
Stage IIA	2	-
Stage IIIA	1	-
Stage IIIC	1	1
Lost to follow-up	27	2
No breast cancer	161	40

DCIS: Ductal carcinoma *in situ*, BI-RADS: Breast Imaging-Reporting and Data System, ADH: Atypical ductal hyperplasia

Table 4: Follow-up results of 227 patients without second mammography

	Total (n=227)
Lost to follow-up	27
No breast cancer	161
DCIS	34
Stage I	1
Stage IIA	2
Stage IIIA	1
Stage IIIC	1

DCIS: Ductal carcinoma *in situ*

screening of breast cancer had become increasingly popular in the world [10-12]. The incidence rate of breast cancer doubled from 30/100,000 individuals in 1995 to 59.9/100,000 individuals in 2009 in Taiwan [13]. Taiwan's Bureau of Health Promotion and the Radiological Society Republic of China collaborated to implement a nationwide mammogram-based screening for breast cancer. Since 2010, women between the ages of 45 and 69 years in Taiwan are eligible to undergo a free mammogram every 2 years. Our hospital is a tertiary care center with 7000 mammographies performed every year. Based on the data from the current study, only 23.3% (70/301) of the patients who underwent needle-localized excision biopsy of microcalcifications underwent a second

mammography at follow-up. In contrast, 227 patients did not undergo second mammography at follow-up. Among them, 70 patients were classified into BI-RADS 4 category, based on the first mammography [Table 3]; 34 patients were diagnosed with DCIS; and five patients had breast cancer at follow-up [Table 4]. Although some patients were diagnosed with DCIS and malignancy based on the results of mammography, breast sonography may have been advised at follow-up. However, annual mammography is recommended for patients with benign microcalcifications and cancer at follow-up and bi-annual mammography screening is recommended for women aged 45–69 years. This implies that the nationwide mammography-screening program is not well accepted and executed in Taiwan. The benefit of mammography is not well known to the medical personnel. From the data shown in Table 1, we found that 74 patients received secondary mammography follow-up and 35.1% of the patients were finally diagnosed of DCIS and breast cancer. In addition, 33 patients received a third mammography follow-up and 48.5% of the patients were diagnosed of DCIS and breast cancer later. Furthermore, two patients received 6th and 7th mammography follow-ups and both of them were diagnosed of DCIS and breast cancer. It was also noted that patients who underwent more than two mammographies had a higher probability for detection of breast cancer. Therefore, improving the quality and compliance of mammography-based screening is important in Taiwan, with an attempt by the government to increase screening efforts.

The presence of microcalcifications is one of the earliest signs for the detection of breast cancer. Mammography is an extremely sensitive tool for the detection of microcalcifications. Distinguishing benign calcifications from malignant may sometimes be challenging; therefore, the specificity of mammography for lesions remains low [14]. Only 20%–30% of cases suspected to be malignant are eventually determined to have breast cancer based on mammography-guided needle localization and surgical excision [15,16]. In the current study, 70 DCIS and malignancies were detected among 301 patients. The rate of detection was 23.3%, which is consistent with the results of previous studies [15,16]. The majority of cases were categorized as BI-RADS 0 that warranted further investigation to define their characteristics. Subsequently, magnified mammography was employed to determine the requirement of a biopsy. As some surgeons preferred needle-localized excision biopsy to magnified mammography, most of the patients in the current study did not undergo magnified mammography. The detection rate of malignancy by needle localization excision depends on several factors, such as correct BI-RADS assessment, precise localization of the needle, good surgical technique, and conclusive report of pathology. We suggest that magnified mammography should be made mandatory for better and more accurate BI-RADS assessment, which may help avoid unnecessary surgical biopsy.

ADH refers to mammary ductal epithelial cell proliferation. The histological findings include cellular atypia and structural changes in the lesion, which are similar to DCIS. The difference between the lesion of ADH and DCIS is the extent

Table 5: Initial Breast Imaging-Reporting and Data System category of 44 atypical ductal hyperplasia patients

BI-RADS	Total (n=44)
0	27
2	1
4	6
4A	9
4B	1

BI-RADS: Breast Imaging-Reporting and Data System

Table 6: Follow-up results of 44 atypical ductal hyperplasia patients

	Total (n=44)
Lost to follow-up	2
No breast cancer	40
DCIS	1
Stage IIIC	1

DCIS: Ductal carcinoma *in situ*

of involvement and size. ADH only involves one or two ducts and the size of the lesion is <2 mm. Only 8%–17% of biopsy specimens detect ADH [17,18]. ADH is a marker of increased long-term risk of breast cancer. It is also a precursor lesion of DCIS and invasive cancer [19].

The main concern is the progression of ADH to malignancy. Malignancy was observed in 10%–13% of ADH cases that were surgically excised in which mammographic abnormality was proven by core biopsy. Various guidelines continue to recommend surgical resection for ADH [20]. A cluster of amorphous microcalcifications is the most common presentation of ADH on mammography. Among the 44 ADH patients in the current study, 42 patients underwent regular follow-up including ultrasound or mammography and 40 patients are currently free of breast cancer. However, one patient was diagnosed with DCIS and one with Stage IIIC breast cancer. Because ADH and DCIS may exist in the same lesion, it is difficult to differentiate between the two lesions in the limited biopsy specimen. Several studies have reported upgraded rates of 4%–54% after surgical excision [21]. In the present study, needle-localized excision biopsy was performed in all patients. The radiological-pathological concordance was superior to that of core needle biopsy.

Becker *et al.* conducted conventional mammography or digital mammography stereotactic guidance for core biopsy of indeterminate breast microcalcifications, and the malignancy detection rate was 18.5% [22]. A previous study found that stereotactic vacuum-assisted biopsy (VAB) in two different biopsy devices (ATEC® and Mammotome®) had different malignancy detection rates of 30% and 23%, respectively. Another study also used two different VAB systems (Mammotome® and EnCor®) and obtained the malignancy detection rate of 21.3% and 14.6%, respectively [23,24]. Because our radiologists were not familiar with mammography stereotactic core biopsy, our hospital did not provide the exam and our current study had no relative data. VAB was introduced in 1995 and has recently been employed as a substitute for surgical excision

as it is a less invasive procedure for pathological diagnosis of lesions of the breast. Conventional core needle biopsy has lower sensitivity; therefore, VAB has an advantage in detecting microcalcifications. Stereotactic VAB is an alternative diagnostic technique for undetermined clusters of microcalcifications [25]. However, stereotactic VAB is expensive, and a large space is required to house the stereotactic mammography unit. As the National Health Insurance of Taiwan does not cover the expenses of VAB, the investigation was not performed in cases with suspicious malignant microcalcifications until 2 years ago. Owing to the small number of individuals, the current study did not include patients who had undergone VAB. In order to compare the benefits and oncologic outcomes of mammography stereotactic core biopsy, VAB with those of needle localization excision for cluster microcalcifications undetectable on sonography, additional prospective randomized studies should be conducted.

The BI-RADS was developed by the American College of Radiology to standardize the assessment and description of findings and recommendations for management of breast lesions [26]. According to prior studies, the final assessment categories of BI-RADS lexicon are useful and effective in risk stratification of breast lesion malignancies [27,28]. Four morphology descriptors were used to describe suspicious microcalcifications as per the fourth edition of the BI-RADS, that is, amorphous, coarse heterogeneous, fine pleomorphic, and fine linear/fine linear branching [29]. Morphology descriptors were further subdivided into two groups, that is, those of intermediate concern (amorphous and coarse heterogeneous) and others with a high probability of malignancy (fine pleomorphic and fine linear/fine linear branching) [29]. Several studies have reported the PPV of amorphous, coarse heterogeneous, fine pleomorphic, and fine linear/fine linear branching microcalcifications to be approximately 21%, 13%, 29%, and 70%, respectively [30–32]. Forty-eight patients presented with pleomorphic pattern in the current study. Among them, 18 (25.71%) patients were diagnosed with DCIS and cancer, which is consistent with previous studies. Not all suspicious microcalcifications observed in the patients in the current study were assessed based on the fourth edition of the BI-RADS. Some patients were assessed according to the third edition of the BI-RADS. The final assessment categories of the fourth edition of the BI-RADS scored lesions with a likelihood of malignancy as follows: category 4A was low (2%–10%), 4B was intermediate (11%–50%), and 4C was moderate (51%–95%) [29]. There were 51 cases of BI-RADS 4, 45 of BI-RADS 4A, 4 of BI-RADS 4B, and 2 cases of BI-RADS 4C [Table 1]. Ten (22.22%) BI-RADS 4A cases, 2 (50%) BI-RADS 4B cases, and one (50%) case of BI-RADS 4C were diagnosed with DCIS and cancer after needle-localized excision. The percentage for category 4A was higher in the current study than the commonly reported range. The percentages for categories 4B and 4C were within the usual result. In our opinion, the results of the present study would support the BI-RADS to further define the Category 4 and contribute more evidence to clinical pathologists and physicians [33].

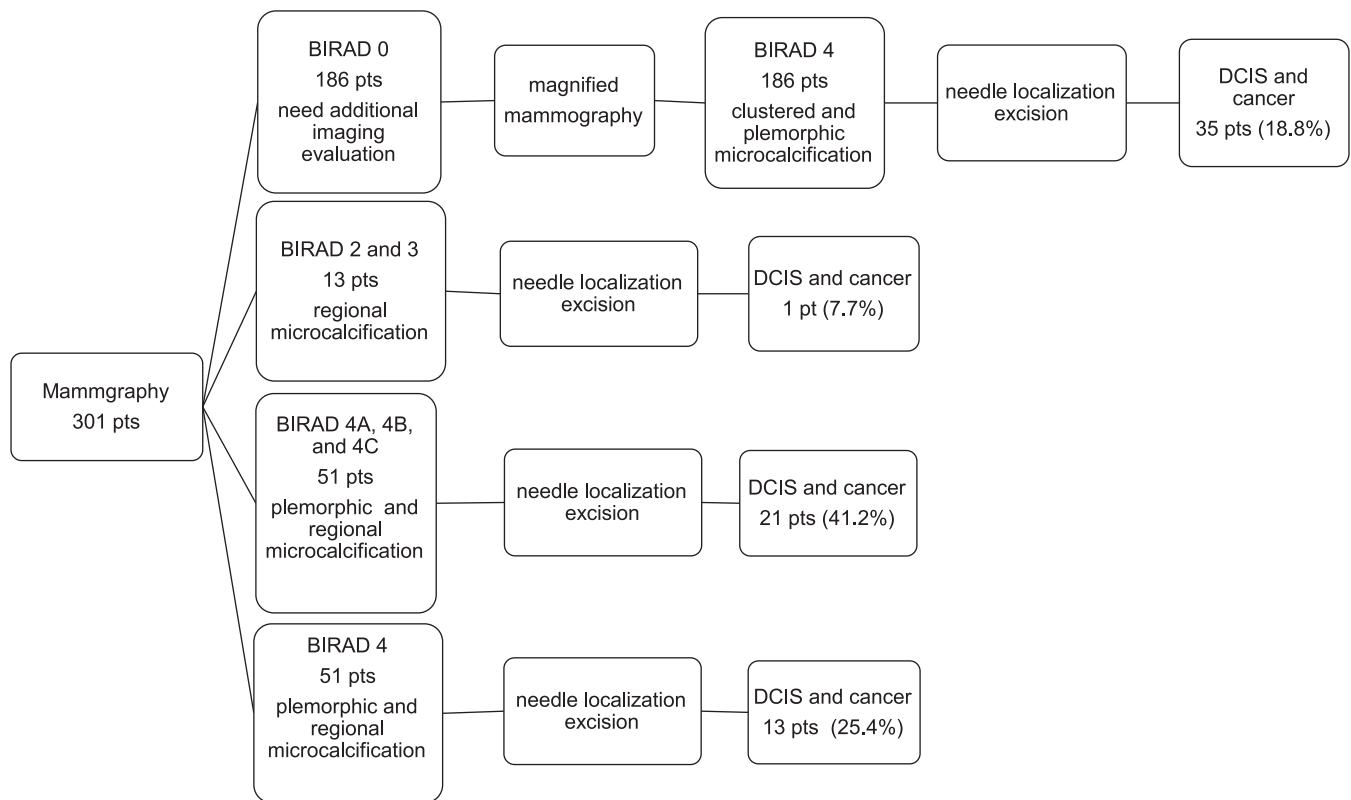


Figure 1: Flowchart of initial mammography report, microcalcification subtype, and final pathologic result. Pts: Patients

The current study has some limitations. First, the subject population in this retrospective study was rather small and restricted to one medical hospital, resulting in possible sample bias. Additional studies with a larger population are required to further assess the predictive value of needle-localized excision. Second, interobserver variability is a well-known concern in the characterization of microcalcifications. In order to manage this deviation and confirm appropriate handling of categories according to the BI-RADS, independent assessment by experienced breast-imaging subspecialists and a consensus resolution of any assessment discrepancies are suggested. Third, the current study included only patients who underwent biopsy due to suspicious microcalcifications on mammography. However, not every patient accepted this recommendation for biopsy. The general application of the results of the current study was affected by this selection bias. Fourth, although significant efforts were undertaken, the inherent limitations of the retrospective nature of studies may also be present in this study and must be acknowledged. For example, the detection rate of needle-localized excision for microcalcifications undetected by sonography was estimated among the study participants. Uncertainty of these estimates may be substantial as inaccurate sonographic readings and inadequate surgical techniques can limit the sample size and the predictive value of the current study.

CONCLUSIONS

Needle-localized excision for microcalcifications undetectable on sonography has a high rate for early detection of breast cancer with a low rate of associated

complications. In addition, regular and diligent mammography is a satisfactory screening tool for follow-up of female patients with microcalcifications and cancer. Additional studies that compare needle-localized excision, mammography stereotactic core biopsy, and VAB should be conducted.

Financial support and sponsorship

Nil.

Conflicts of interest

There are no conflicts of interest.

REFERENCES

- Jemal A, Bray F, Center MM, Ferlay J, Ward E, Forman D. Global cancer statistics. *CA Cancer J Clin* 2011;61:69-90.
- Jackson VP. The current role of ultrasonography in breast imaging. *Radiol Clin North Am* 1995;33:1161-70.
- Westerhof JP, Fischer U, Moritz JD, Oestmann JW. MR imaging of mammographically detected clustered microcalcifications: Is there any value? *Radiology* 1998;207:675-81.
- Moon WK, Im JG, Koh YH, Noh DY, Park IA. US of mammographically detected clustered microcalcifications. *Radiology* 2000;217:849-54.
- Zonderland HM, Coerkamp EG, Hermans J, van de Vijver MJ, van Voorthuisen AE. Diagnosis of breast cancer: Contribution of US as an adjunct to mammography. *Radiology* 1999;213:413-22.
- Bigelow R, Smith R, Goodman PA, Wilson GS. Needle localization of nonpalpable breast masses. *Arch Surg* 1985;120:565-9.
- Symmonds RE Jr., Roberts JW. Management of nonpalpable breast abnormalities. *Ann Surg* 1987;205:520-8.
- Gisvold JJ, Martin JK Jr. Prebiopsy localization of nonpalpable breast lesions. *AJR Am J Roentgenol* 1984;143:477-81.
- Myers ER, Moorman P, Gierisch JM, Havrilesky LJ, Grimm LJ, Ghatge S,

- et al. Benefits and harms of breast cancer screening: A systematic review. *JAMA* 2015;314:1615-34.
10. Tabár L, Fagerberg CJ, Gad A, Baldetorp L, Holmberg LH, Grontoft O, et al. Reduction in mortality from breast cancer after mass screening with mammography. Randomised trial from the Breast Cancer Screening Working Group of the Swedish National Board of Health and Welfare. *Lancet* 1985;1:829-32.
 11. Shapiro S, Venet W, Strax P, Venet L, Roeser R. Ten-to fourteen-year effect of screening on breast cancer mortality. *J Natl Cancer Inst* 1982;69:349-55.
 12. Bjurstram N, Björneld L, Warwick J, Sala E, Duffy SW, Nyström L, et al. The Gothenburg Breast Screening Trial. *Cancer* 2003;97:2387-96.
 13. Taiwan Cancer Registry. Available from: <http://cph.ntu.edu.tw/main.php?Page=N1>. [Last accessed on 2018 May 01].
 14. Scaranelo AM, Eiada R, Bukhanov K, Crystal P. Evaluation of breast amorphous calcifications by a computer-aided detection system in full-field digital mammography. *Br J Radiol* 2012;85:517-22.
 15. Masroor I, Afzal S, Shafqat G, Rehman H. Usefulness of hook wire localization biopsy under imaging guidance for nonpalpable breast lesions detected radiologically. *Int J Womens Health* 2012;4:445-9.
 16. Kouskos E, Gui GP, Mantas D, Revenas K, Rallis N, Antonopoulou Z, et al. Wire localisation biopsy of non-palpable breast lesions: Reasons for unsuccessful excision. *Eur J Gynaecol Oncol* 2006;27:262-6.
 17. McGhan LJ, Pockaj BA, Wasif N, Giurescu ME, McCullough AE, Gray RJ. Atypical ductal hyperplasia on core biopsy: An automatic trigger for excisional biopsy? *Ann Surg Oncol* 2012;19:3264-9.
 18. Pearlman MD, Griffin JL. Benign breast disease. *Obstet Gynecol* 2010;116:747-58.
 19. Ma XJ, Salunga R, Tuggle JT, Gaudet J, Enright E, McQuary P, et al. Gene expression profiles of human breast cancer progression. *Proc Natl Acad Sci U S A* 2003;100:5974-9.
 20. National Comprehensive Cancer Network. NCCN Guidelines v. 1.2016 Breast Cancer Screening and Diagnosis. Available from: https://www.nccn.org/professionals/physician_gls/pdf/breast-screening.pdf. [Last accessed 2017 Mar 14].
 21. Racz JM, Degnim AC. When does atypical ductal hyperplasia require surgical excision? *Surg Oncol Clin N Am* 2018;27:23-32.
 22. Becker L, Taves D, McCurdy L, Muscedere G, Karlik S, Ward S. Stereotactic core biopsy of breast microcalcifications: Comparison of film versus digital mammography, both using an add-on unit. *Am J Roentgenol* 2001;177:1451-7.
 23. Mariscotti G, Durando M, Robella M, Angelino F, Regini E, Campanino PP, et al. Mammotome(®) and EnCor (®): Comparison of two systems for stereotactic vacuum-assisted core biopsy in the characterisation of suspicious mammographic microcalcifications alone. *Radiol Med* 2015;120:369-76.
 24. Eller A, Janka R, Lux M, Saake M, Schulz-Wendtland R, Uder M, et al. Stereotactic vacuum-assisted breast biopsy (VABB) – A patients' survey. *Anticancer Res* 2014;34:3831-7.
 25. Al-Attar MA, Michell MJ, Ralleigh G, Evans D, Wasan R, Bose S, et al. The impact of image guided needle biopsy on the outcome of mammographically detected indeterminate microcalcification. *Breast* 2006;15:635-9.
 26. American College of Radiology. Breast Imaging Reporting and Data System. 5th ed. Reston: American College of Radiology, 2013.
 27. Zonderland HM, Pope TL Jr., Nieborg AJ. The positive predictive value of the breast imaging reporting and data system (BI-RADS) as a method of quality assessment in breast imaging in a hospital population. *Eur Radiol* 2004;14:1743-50.
 28. Obenaus S, Hermann K, Grabbe E. Applications and literature review of the BI-RADS classification. *Eur Radiol* 2005;15:1027-36.
 29. American College of Radiology. Breast Imaging Reporting and Data System. 4th ed. Reston: American College of Radiology; 2003.
 30. Berg WA, Arnoldus CL, Teferra E, Bhargavan M. Biopsy of amorphous breast calcifications: Pathologic outcome and yield at stereotactic biopsy. *Radiology* 2001;221:495-503.
 31. Burnside ES, Ochsner JE, Fowler KJ, Fine JP, Salkowski LR, Rubin DL, et al. Use of microcalcification descriptors in BI-RADS 4th edition to stratify risk of malignancy. *Radiology* 2007;242:388-95.
 32. Bent CK, Bassett LW, D'Orsi CJ, Sayre JW. The positive predictive value of BI-RADS microcalcification descriptors and final assessment categories. *AJR Am J Roentgenol* 2010;194:1378-83.
 33. Lazarus E, Mainiero MB, Schepps B, Koelliker SL, Livingston LS. BI-RADS lexicon for US and mammography: Interobserver variability and positive predictive value. *Radiology* 2006;239:385-91.