



## Original Article

# Embryological considerations and evaluation of congenital anomalies of craniovertebral junction: A single-center experience

Reddy Ravikanth<sup>a\*</sup>, Pooja Majumdar<sup>b</sup>

<sup>a</sup>Department of Radiology, St. John's Hospital, Kattappana, Kerala, India, <sup>b</sup>Department of Medicine, INHS Kalyani, Visakhapatnam, Andhra Pradesh, India

**ABSTRACT**

**Objectives:** Craniovertebral junction (CVJ) abnormalities constitute a group of treatable neurological disorders, especially in the Indian subcontinent. Thus, it is essential that clinicians should be able to make a precise diagnosis of abnormalities and rule out important mimickers on multidetector computed tomography (MDCT) as this information ultimately helps determine the management, prognosis, and quality of life of patients. CVJ is the most complex part of the cervical region. Congenital malformations of this region can cause serious neurological deficit and require a surgical intervention. The present study was undertaken to know the embryological basis of the CVJ and to identify commonly observed congenital CVJ abnormalities, their frequency, and mode of presentation. **Materials and Methods:** Diagnosed cases of CVJ anomalies on dynamic MDCT head were reviewed at a tertiary care center between January 2014 to December 2019. Type of anomaly, clinical presentation, and associated malformations were recorded. Different types of variations were expressed in terms of percentage. **Results:** Congenital anomalies were seen in 42 cases. Fifteen types of anomalies were detected. Anomalies were either singly or in combination. The CVJ anomalies were more common in young adults (28%), almost equal in both sexes. The most common anomaly was basilar invagination (52.3%), followed by atlanto-occipital assimilation (33.3%), and Arnold–Chiari malformation is the most common soft tissue anomaly. In fourteen cases, additional anomalies of other vertebrae were present. The most common symptoms were weakness of extremities, neck pain, paresthesia, torticollis, and gait disturbances. About 28 patients got improved, 8 patients had residual deficit as that of preoperative status, and 4 patients got deteriorated after surgery, at 1-month follow-up. About 34 patients had improved, 5 remained static, and 3 patients got worsened at the end of 3-month follow-up. About 37 patients had improved, 4 patients remained static, and 2 patients got deteriorated at 6 months of follow-up. The patients with increased atlantodens interval 3–5 mm showed 77% improvement after surgery. **Conclusion:** Congenital CVJ anomalies, though rare, are fatal. CVJ abnormalities constitute an important group of treatable neurological disorders with diagnostic dilemma. The atlantodental interval is the most important preoperative prognostic marker. Dynamic CT imaging can provide additional useful information to the diagnosis of CVJ instability. To prevent long-term neurological problems, early diagnosis and treatment of congenital bony CVJ anomalies is important.

**KEYWORDS:** *Basilar invagination, Craniometric parameters, Craniovertebral junction anomalies, Multidetector computed tomography, Sclerotomes*

Submission : 01-Apr-2020  
Revision : 08-Jun-2020  
Acceptance : 26-Jun-2020  
Web Publication : 15-Oct-2020

**INTRODUCTION**

Craniovertebral junction (CVJ) consists of basilar part of occipital bone, atlas, and axis vertebra. Being the transit zone between cranium and spine, it is the most complex and dynamic area of the cervical region. It has complex bony anatomy and is related with major neurovascular structures. It shows extensive variability in morphology also. Congenital

malformations associated with this region have a potential of causing serious neurological and vascular deficit and

**\*Address for correspondence:**

Dr. Reddy Ravikanth,  
Department of Radiology, St. John's Hospital,  
Kattappana - 685 515, Kerala, India.  
E-mail: [ravikanthreddy06@gmail.com](mailto:ravikanthreddy06@gmail.com)

**Access this article online****Quick Response Code:**Website: [www.tcmjmed.com](http://www.tcmjmed.com)

DOI: 10.4103/tcmj.tcmj\_62\_20

This is an open access journal, and articles are distributed under the terms of the Creative Commons Attribution-NonCommercial-ShareAlike 4.0 License, which allows others to remix, tweak, and build upon the work non-commercially, as long as appropriate credit is given and the new creations are licensed under the identical terms.

For reprints contact: [WKHLRPMedknow\\_reprints@wolterskluwer.com](mailto:WKHLRPMedknow_reprints@wolterskluwer.com)

**How to cite this article:** Ravikanth R, Majumdar P. Embryological considerations and evaluation of congenital anomalies of craniovertebral junction: A single-center experience. Tzu Chi Med J 2021; 32(2): 175-80.

may require surgical intervention. The incidence of different types of CVJ anomalies varies with demographic regions and genetic factors. CVJ anomalies are more frequently found in the Indian subcontinent than anywhere else in the world [1]. These osseous anomalies can manifest with abnormal cerebrospinal fluid dynamics [2]. Multidetector computed tomography (MDCT) is the most commonly used modality to assess the CVJ [3]. To identify different anomalies, it is important to understand the embryology and developmental anatomy of the region. It is important to rule out mimickers on MDCT as this information ultimately helps determine the management, prognosis, and quality of life of patients with CVJ anomalies. Hence, the current study was undertaken to know the embryological basis of the CVJ and to study commonly observed congenital CVJ abnormalities, their frequency, and mode of presentation.

### Epidemiology of craniovertebral junction anomalies

The incidence of different types of CVJ anomalies varies with demographic environment and ill-defined genetic factors. CVJ anomalies are more frequently found in the Indian subcontinent than anywhere else in the world. They are common in all age groups and almost equal in both sex groups. The clinical features are often delayed up to 2<sup>nd</sup> or 3<sup>rd</sup> decades, since they are subtle and often missed. In the current study, we had screened 78 cases with suspected anomalies of CVJ based on clinical features and found 42 congenital anomalies of CVJ, which was rare and fatal.

### MATERIALS AND METHODS

A retrospective, cross-sectional study was conducted at a tertiary care center based on analysis of CT head reports between January 2014 to December 2019. Diagnosed cases of CVJ anomalies on CT head were reviewed. Total 42 patients with bony congenital malformations of age 8 years and above were included in the study. They were divided into six groups according to the age in decade. Side and type of anomaly, clinical presentation, and associated malformations were recorded. Normal CT reports, CT of patients with a history of trauma, tumors, tuberculosis, and rheumatoid arthritis were excluded. Dynamic craniometric measurements on MDCT included Chamberlain's line, McRae's line, McGregor's line, Wackenheim's clivus canal line, and Welcher's basal angle. Magnetic resonance imaging (MRI) was done in suspected cases of neurological involvement. After complete clinical examination, the sensory level, the motor level, and the reflex level were found and the diagnosis of CVJ anomalies was attained. The other associated clinical features such as head tilt, short neck, webbed neck, downbeat nystagmus, cranial nerve deficits, and features of congenital syndromes such as Down syndrome, Morquio syndrome, and Klippel-Feil syndrome were taken into account. Atlantodental interval is the single important and reliable marker to assess the prognostic outcome. Various bony anomalies such as defects in the arches of atlas, assimilation of atlas, block vertebrae, basilar invagination (BI), atlanto-occipital dislocation, and odontoid fracture were studied. Among the congenital bony CVJ anomalies, congenital atlanto-axial subluxation, BI, platybasia, occipitalization of atlas, and defect in the arches of atlas were studied. Among

the congenital soft tissue CVJ anomalies, Arnold-Chiari malformations and syringomyelia were studied. All the reducible CVJ junction anomalies are better treated with surgical modality. For surgical repair under fluoroscopy guidance, lateral mass screw on C1 and pars or pedicle screw on C2 were placed bilaterally. Occipital plate was used for occipitocervical fusion. The irreducible anomalies are immobilized with Philadelphia collar or halo brace and managed conservatively. Different types of variations were expressed in terms of percentage. The study was conducted in accordance with the Declaration of Helsinki and was approved by the Institutional Ethics Committee (IEC), and informed consent was obtained from all patients before their enrollment in this study (IEC, St. John's Hospital; IEC Approval Reference Number: SJH/7/2014; IEC Approval Date: January 12, 2014).

### Statistical analysis

The findings were tabulated using Microsoft Excel 2010 Microsoft Corp., Redmond, WA, USA, and statistical analyses were conducted using SPSS Statistical Package (version 20.0), IBM SPSS Statistics for Windows, V.20.0, IBM Corp., Armonk, New York, USA.

### RESULTS

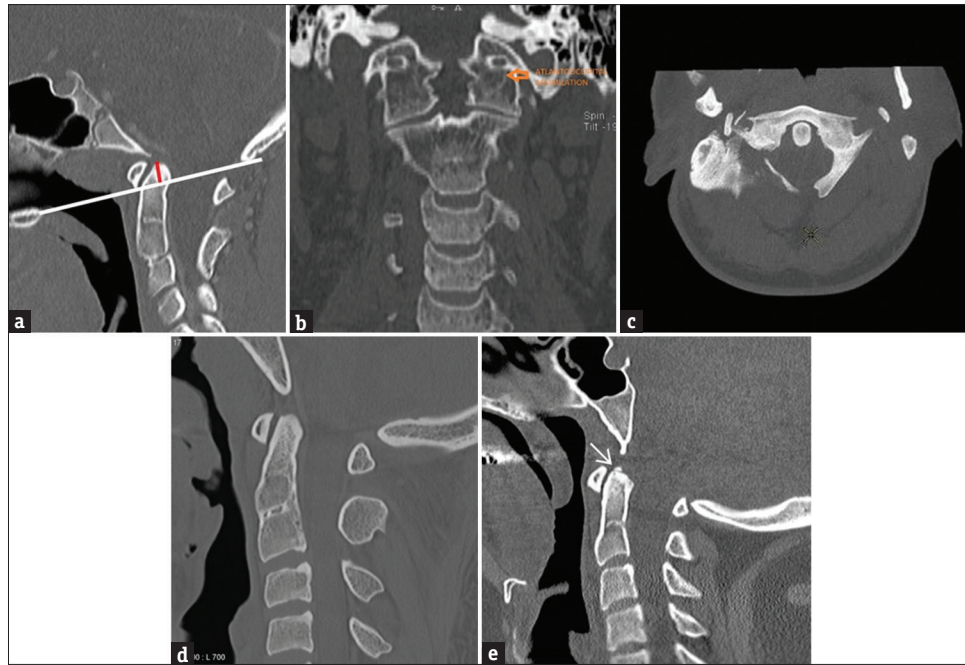
Congenital CVJ anomalies were seen in 42 cases. Fifteen types of anomalies were detected [Table 1]. Anomalies seen were either singly or in combination [Figures 1 and 2]. The most common anomaly was BI seen in 52.3% of cases; BI was seen in combination with atlanto-occipital assimilation, occipital condylar hypoplasia, ponticulus posticus, and atlantoaxial assimilation [Table 2]. In fourteen cases, associated anomalies of other vertebrae were present [Table 2]. Maximum of 12 cases were detected in the age group of 11–20 years. The most common symptoms were weakness of extremities, neck pain, paresthesia, torticollis, and gait disturbances.

In the current study, age distribution was from 8 to 60 years and most of the patients were diagnosed in the

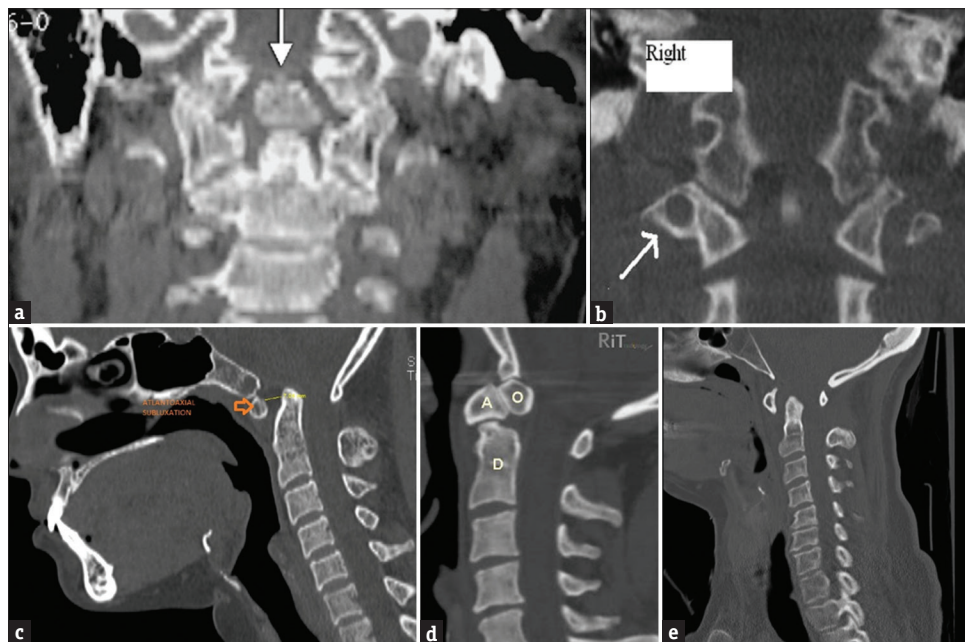
**Table 1: Incidence of craniovertebral junction anomalies in the current study**

Type of CVJ anomaly	n (%)
BI	22
AOA	14
Incomplete posterior arch of atlas	6
C2-C3 fusion	4
Proatlas/condylus tertius	4
Os terminale	4
OCH	2
PP	1
Hypertrophy of anterior arch of atlas	2
CAA	2
Platybasia	2
Hypoplasia of posterior arch of atlas	2
OS odontoideum	2
Absent lateral mass of atlas	1
C1-C2 dislocation	1

CVJ: Craniovertebral junction, BI: Basilar invagination, AOA: Atlanto-occipital assimilation, OCH: Occipital condyle hypoplasia, PP: Ponticulus posticus, CAA: Complete atlantoaxial assimilation



**Figure 1:** (a) Basilar invagination as demonstrated by a sagittal reformatted computed tomography image. Red line indicates the tip of odontoid process above the McGregor line (white). (b) Coronal reformatted computed tomography image demonstrating complete atlanto-occipital assimilation (arrow). (c) Axial computed tomography image demonstrating a defect in the posterior arch of atlas. (d) Sagittal reformatted computed tomography image demonstrating fusion of C2–C3 vertebrae. (e) Sagittal reformatted computed tomography image demonstrating os terminale (arrow)



**Figure 2:** (a) Coronal reformatted computed tomography image demonstrating medial (third) occipital condyle causing atlantoaxial instability. (b) Coronal reformatted computed tomography image demonstrating Ponticulus posticus on the right (arrow). (c) Sagittal reformatted computed tomography image demonstrating increased atlanto-dens interval (7 mm) suggestive of atlantoaxial instability. (d) Sagittal reformatted computed tomography image demonstrating Os terminale-Os odontoideum complex. (e) Sagittal reformatted computed tomography image demonstrating increased atlanto-dens interval causing atlantoaxial subluxation/dislocation

second decade with male predominance. Patients in the current study presented with complaints such as weakness of extremities (52%), neck pain (32%), paresthesia (8%), torticollis (4%), and gait disturbances (4%). In children with unilateral atlas assimilation, torticollis was a presenting symptom.

Skeletal deformities were found in 4 patients (3 had kyphosis and 1 had scoliosis), spastic quadriplegia in 4 patients, sensory disturbances involving the anterolateral spinothalamic tract and posterior column in 38 patients, autonomic disturbances in 28 patients (isolated bladder involvement in 18 patients, combined bladder and bowel involvement in

**Table 2: Combination anomalies and associated anomalies with Basilar invagination**

	n (%)
Combination anomalies	
BI + AOA	7 (31.8)
BI + AOA + OCH	4 (18.1)
BI + AOA + PP	4 (18.1)
BI + CAAP + PP	4 (18.1)
Associated anomalies	
C6-C7 fusion	4 (28.5)
Bilateral cervical ribs	3 (21.4)
T2-T3 fusion	2 (14.2)
Multiple vertebral anomalies	2 (14.2)
C3 hemivertebra	3 (21.4)

BI: Basilar invagination, AOA: Atlanto-occipital assimilation, OCH: Occipital condyle hypoplasia, PP: Ponticulus posticus, CAAP: Complete atlantoaxial assimilation

24 patients), downbeat nystagmus in 4 patients, facial sensory loss in 2 patients, lower cranial nerve deficits in 6 patients, and 6 patients presented with features of vertebrobasilar insufficiency in the form of vertigo.

#### Distribution of surgical outcome

The neurological outcome was assessed in these 42 patients by thorough clinical examination of motor power under MRC Grade. About 28 patients got improved, 8 patients had residual deficit as that of preoperative status, and 4 patients got deteriorated after surgery at 1-month follow-up. About 34 patients had improved, 5 remained static, and 3 patients got worsened at the end of 3 months of follow-up. About 37 patients had improved, 4 patients remained static, and patients got deteriorated at 6 months of follow-up.

The CVJ anomalies are more common in young adults (28%), almost equal in both sexes. BI (52.3%) is the most common congenital bony anomaly, and Arnold–Chiari malformation is the most common soft tissue anomaly. The patients with increased atlantodens interval 3–5 mm showed 77% improvement after surgery.

## DISCUSSION

### Embryology of craniovertebral junction

The vertebral column develops in six separate but overlapping phases. The first phase is gastrulation and the formation of the mesoderm and notochord. In the second phase, somites are formed. During the third phase, somites are reorganized to form dermomyotome and sclerotome. There is resegmentation of the somites to form the definitive vertebrae in the fourth phase. This is followed by vertebral chondrification in the fifth and vertebral ossification in the sixth phase [4]. There are about 42 pairs of somites in the 4<sup>th</sup> week of development [5]. There are 4 occipital somites, 8 cervical, 12 thoracic, 5 lumbar, 5 sacral, and 8–10 coccygeal pairs of somites. The cells of sclerotome migrate ventromedially around notochord to form primitive vertebral bodies [6]. The first and second occipital sclerotomes form the basilar part of occipital bone. Caudal part of the 4<sup>th</sup> occipital somite fuses with cranial half of the 5<sup>th</sup> somite or first cervical to form proatlas sclerotome. The CVJ

abnormalities are caused by abnormalities of resegmentation of the proatlas. The proatlas forms the anterior tubercle of the clivus, tip of the dens, and the apical ligament [7]. The neural arch of the proatlas forms the anterior margin of the foramen magnum, occipital condyle, the lateral atlantal masses, and the superior portion of the posterior arch of the atlas. The axis body is formed by the centrum and the neural arch forms the facets and the posterior arch of the axis vertebra [8]. The tip of the odontoid process is derived from the proatlas [9]. A separate ossification center appears for the tip of the odontoid at 3 years of age and fuses with the rest of the dens by 12 years of age. Resegmentation of sclerotome is under the control of regulatory genes such as Hox and Pax [10]. Both MTHFR 677C→T polymorphism and higher T allele frequency have significant associations with AAD. Genotypes with single base substitutions, deletions, or duplication of part of the COL2A1 gene have been advocated in CVJ anomalies. Cervical spine radiographs in these patients have demonstrated apparent atlantoaxial instability in correlation with odontoid hypoplasia or Os odontoideum [11]. Pax genes are involved in vertebrae formation and contribute to the development of the early nervous system [12].

### Clinical presentation

The most interesting feature is the diversity of clinical feature as a result of compromise of lower brainstem, cervical spinal cord, cranial nerves, cervical roots, and vascular supply. The congenital anomalies are associated with abnormal physical appearance such as head tilt, short neck, low hairline, and limited neck movements (Klippel–Feil syndrome). The most frequent symptom is the suboccipital neck pain, radiating to the cranium. The features of myelopathy may present in the form of monoparesis, hemiparesis, paraparesis, and ascending pattern of quadriparesis. Central cord syndrome is seen in children with BI. Sensory abnormalities are manifested as neurological deficits related to the anterolateral and posterior column dysfunction. Brainstem and cranial nerve deficits can cause abnormalities such as dysphagia, nasal regurgitation, change in voice, loss of facial sensation, and sleep apnea. Downbeat nystagmus is a cardinal sign, more characteristically seen with strictly compressive CVJ lesions. The excessive mobility of an unstable CVJ can cause trauma to the anterior spinal artery and the perforating vessels of the upper cervical cord and medulla oblongata producing features of vertebrobasilar insufficiency such as vertigo, syncopal attacks, and transient loss of consciousness.

Congenital CVJ al anomaly is a rare condition all over the world and most studies have reported few cases seen over a long period [13]. The current study demonstrated anomalies in 42 patients over a period of 6 years. A study reported 189 patients with the same anomalies seen in 10 years [14]. In another study, 23 cases were reported from a hospital in northern India in 5 years [15]. The most common congenital anomaly observed in the present study was BI in 22 cases. The current study reported the most common anomaly as BI (52.3%). As the basilar part of occipital bone and margins of foramen magnum are less developed, the odontoid process and arch of atlas invaginate resulting in BI [16]. In four cases (18.1%), BI was associated with atlanto-occipital

assimilation. Another study also reported the similar combination in 14.5% of cases [17]. The second most common anomaly observed in the current study was atlanto-occipital assimilation in 14 cases (33.3%). Mwang'ombe and Kirongo reported occipitalization of the atlas (28%) [18]. Congenital fusion of the atlas with the occiput is one of the most common anomalies of the CVJ, with a prevalence rate from 0.08%–2.8% in the general population [19]. Sometimes, two or more vertebrae may fuse to giving rise to Klippel–Feil syndrome and occipitalization of atlas [20]. The current study recorded fusion in fourteen cases. Other atlas anomalies included two cases each of hypertrophied anterior arch, hypoplastic posterior arch, atlantoaxial fusion, six cases of incomplete posterior arch, absence of lateral mass in one case, and ponticulus posticus in one case. Defects in posterior arch of atlas are ten times more common than defects of anterior arch. Incomplete posterior arches are commonly seen. The defect never closes with age [21]. Platybasia was noted in two cases. Hypoplasia of occipital condyles was seen in two cases in the present study. Hypoplastic condyles results in flattening of skull base which may lead to BI. According to Menezes and VanGilder, condylus tertius or median occipital condyle is observed due to failure of proatlas integration [22]. Os odontoideum is frequently associated with condylus tertius [23]. In the current study, condylus tertius or proatlas was observed in four cases. Os odontoideum was noted in two cases. In this, odontoid process may remain separate from the body of the axis partially or completely [24]. In four cases, Os terminale was seen.

In a study of 70 patients by Menezes, 85%–90% age of presentation was between the first and second decade of life [25]. Other studies reported the same age distribution with male predominance and third decade presentation [17]. Menezes observed spastic quadriplegia as a presenting symptom in 80% of the patients and lower cranial nerve palsies in 33% of the patients [26]. Other studies reported progressive weakness of the extremities due to syringomyelia as the most common mode of presentation in atlantoaxial instability [27]. The various surgical treatment options for CVJ anomalies are described as follows: (1) foramen magnum decompression, (2) suboccipital craniectomy and removal of posterior arch of atlas, (3) C1–C2 wiring done by sublaminar titanium wires, (4) C1–C2 fixation done by C1 lateral mass and C2 pedicle screw fixation, (5) occipitocervical fusion is done by stainless steel or titanium contoured rod or loop with screw fixation, and (6) transoral odontoidectomy is done by transpalatal, transpharyngeal routes to relieve the ventral compression.

## CONCLUSION

Congenital CVJ anomalies, though rare, are fatal. CVJ abnormalities constitute an important group of treatable neurological disorders with diagnostic dilemma. Craniometrical parameters, as well as the visualization of the facets location, may change significantly according to the neck position. The atlantodental interval is the most important preoperative prognostic marker. Dynamic CT can provide additional useful information to the diagnosis of CVJ instability. Early diagnosis and treatment form the mainstay in preventing

long-term neurological complications. MDCT is the investigation of choice for diagnosis and planning the management. CT complemented with MRI is recommended for associated neurological involvement.

## Financial support and sponsorship

Nil.

## Conflicts of interest

There are no conflicts of interest.

## REFERENCES

- Goel A. Craniovertebral anomalies: Role for craniovertebral realignment. *Neurol India* 2004;52:427-9.
- Goel A, Achawal S. The surgical treatment of Chiari malformation association with atlantoaxial dislocation. *Br J Neurosurg* 1995;9:67-72.
- da Silva OT, Ghizoni E, Tedeschi H, Joaquim AF. Role of dynamic computed tomography scans in patients with congenital craniovertebral junction malformations. *World J Orthop* 2017;8:271-7.
- Dias MS. Normal and abnormal development of the spine. *Neurosurg Clin N Am* 2007;18:415-29.
- Stern CD, Piatkowska AM. Multiple roles of timing in somite formation. *Semin Cell Dev Biol* 2015;42:134-9.
- Pang D, Thompson DN. Embryology and bony malformations of the craniovertebral junction. *Childs Nerv Syst* 2011;27:523-64.
- Offiah CE, Day E. The craniocervical junction: Embryology, anatomy, biomechanics and imaging in blunt trauma. *Insights Imaging* 2017;8:29-47.
- Piatt JH Jr, Grissom LE. Developmental anatomy of the atlas and axis in childhood by computed tomography. *J Neurosurg Pediatr* 2011;8:235-43.
- O'Brien WT Sr, Shen P, Lee P. The Dens: Normal Development, Developmental Variants and Anomalies, and Traumatic Injuries. *J Clin Imaging Sci* 2015;5:38.
- Mallo M, Wellik DM, Deschamps J. Hox genes and regional patterning of the vertebrate body plan. *Dev Biol* 2010;344:7-15.
- Horan GS, Wu K, Wolgemuth DJ, Behringer RR. Homeotic transformation of cervical vertebrae in Hoxa-4 mutant mice. *Proc Natl Acad Sci U S A* 1994;91:12644-8.
- Sivakamasundari V, Kraus P, Sun W, Hu X, Lim SL, Prabhakar S, et al. A developmental transcriptomic analysis of Pax1 and Pax9 in embryonic intervertebral disc development. *Biol Open* 2017;6:187-99.
- Goel A. Craniovertebral Junction Instability: A Review of Facts about Facets. *Asian Spine J* 2015;9:636-44.
- Kale SS, Ailawadhi P, Yerramneni VK, Chandra PS, Kumar R, Sharma BS, et al. Pediatric bony craniovertebral junction abnormalities: Institutional experience of 10 years. *J Pediatr Neurosci* 2011;6:S91-5.
- Kumar R, Nayak SR. Management of pediatric congenital atlantoaxial dislocation: A report of 23 cases from northern India. *Pediatr Neurosurg* 2002;36:197-208.
- Goel A. Instability and basilar invagination. *J Craniocerv Junction Spine* 2012;3:1-2.
- Goel A, Bhatjiwale M, Desai K. Basilar invagination: A study based on 190 surgically treated patients. *J Neurosurg* 1998;88:962-8.
- Mwang'ombe NJ, Kirongo GK. Craniovertebral junction anomalies seen at Kenyatta National Hospital, Nairobi. *East Afr Med J* 2000;77:162-4.
- Goel A. Facetal alignment: Basis of an alternative Goel's classification of basilar invagination. *J Craniocerv Junction Spine* 2014;5:59-64.
- Goel A. Cervical fusion as a protective response to craniovertebral junction instability: A novel concept. *Neurospine* 2018;15:323-8.
- Goel A, Nadkarni T, Shah A, Ramdasi R, Patni N. Bifid anterior and posterior arches of atlas: Surgical implication and analysis of 70 cases. *Neurosurgery* 2015;77:296-305.

22. Van Gilder JC, Menezes MI, Dolan KD. The Craniovertebral junction and its abnormalities. New York, NY: Futura; 1987.
23. Goel A, Patil A, Shah A, Dandpat S, Rai S, Ranjan S. OS odontoideum: Analysis of 190 surgically treated cases. *World Neurosurg* 2020;134:e512-23.
24. Jumah F, Alkhdour S, Mansour S, He P, Hroub A, Adeeb N, et al. Os odontoideum: A comprehensive clinical and surgical review. *Cureus* 2017;9:e1551.
25. Menezes MI, VanGilder JC. Anomalies of the craniovertebral junction. In: Youman JR, editor. *Neurological Surgery*. 3<sup>rd</sup> ed. Philadelphia, PA: Saunders; 1990, pp 1359-420.
26. Menezes AH. Primary craniovertebral anomalies and the hindbrain herniation syndrome (Chiari I): Data base analysis. *Pediatr Neurosurg* 1995;23:260-9.
27. Goel A. Is atlantoaxial instability the cause of Chiari malformation? Outcome analysis of 65 patients treated by atlantoaxial fixation. *J Neurosurg Spine* 2015;22:116-27.