



Case Report

Resection of a cavernous hemangioma of the posterior mediastinum by sclerotherapy and uniport thoracoscopic surgery

Jin-You Jhan^{a,b}, Yi-Tso Cheng^{a,b}, Jui-Chih Chang^{a,b}, Bing-Ru Chung^{a,b}, Nai-Wei Huang^{a,b}, Bee-Song Chang^{b,c*}

^aDepartment of Cardiovascular Surgery, Hualien Tzu Chi Hospital, Buddhist Tzu Chi Medical Foundation, Hualien, Taiwan, ^bSchool of Medicine, Tzu Chi University, Hualien, Taiwan, ^cDepartment of Thoracic Surgery, Hualien Tzu Chi Hospital, Buddhist Tzu Chi Medical Foundation, Hualien, Taiwan

Submission : 04-Aug-2019
Revision : 12-Sep-2019
Acceptance : 24-Sep-2019
Web Publication : 21-Oct-2019

ABSTRACT

A 44-year-old female presented with cavernous hemangioma of the posterior mediastinum. Imaging revealed that it was approximately 2 cm in size and without an arterial supply from either the thoracic aorta or intercostal artery. The patient was treated with intraoperative sclerotherapy and hemangioma resection by uniport thoracoscopic surgery via a small 3-cm surgical wound. The surgical outcome and follow-up were good.

KEYWORDS: *Adult, Chest wall, Mediastinal tumor, Thoracoscopy/video-assisted thoracoscopic surgery, Venous disease*

INTRODUCTION

Cavernous hemangioma of the posterior mediastinum is a benign vascular tumor that accounts for approximately 1% of all tumors. Most occur in the skull, central neural system, vertebrae, or liver and rarely in the posterior mediastinum [1]. A few cases involving the posterior mediastinum have been reported near the heads of the ribs [2,3]. The hemangioma in this patient was found near the heads of the left third and fourth ribs.

CASE REPORT

The patient was a 44-year-old female without any underlying condition. A cavernous hemangioma was accidentally discovered by computed tomography (CT) during a routine health examination. A paravertebral CT scan found a 24 mm × 22 mm × 12 mm mass located in the posterior mediastinum near the heads of the left third and fourth ribs [Figure 1]. The patient was asymptomatic. Uniport thoracoscopic resection of a suspected neurogenic tumor was initiated via a 3-cm surgical wound, but was stopped upon detection of the hemangioma [Figure 2a]. A subsequent angiogram did not find an arterial supply from the aorta [Figure 3a-c]. After consulting a radiologist, a second uniport thoracoscopic procedure was performed with intraoperative angiography and sclerotherapy with access through the existing 3-cm wound. Angiography performed with direct contrast injected into the tumor showed no contrast extending to the spinal cord or aorta [Figure 3d]. Sclerotherapy was performed with histoacryl tissue coagulant in lipiodol (1:2 ratio) [Figure 2b]. The tumor was resected completely using a harmonic energy device [Figure 2c]. Little

blood loss occurred. A chest tube was inserted for drainage in the small 3-cm surgical wound [Figure 2d]. The pathological evaluation of the resected tissue confirmed the diagnosis of cavernous hemangioma [Figure 4]. The patient was discharged on day 3 after the second procedure, and outpatient follow-up confirmed that the patient remains free of symptoms.

DISCUSSION

Cavernous hemangioma is a rare benign lesion that is difficult to diagnose preoperatively. It seldom occurs in the posterior mediastinum [4]. Treatment options include sclerotherapy, embolization, and surgical resection [1-3,5]. Most previous cases have been treated by open surgery that included relatively large surgical wounds and long recovery times [3,4]. In this patient, resection was achieved by uniport thoracoscopy. Imaging confirmed that there was no blood supply from the aorta, and intraoperative angiography found that no contrast media extended to the spinal cord or aorta. Histoacryl tissue coagulant mixed with lipiodol was used for sclerotherapy. The hemangioma was successfully resected via a small surgical wound and easy to stop bleeding. No previous reports of a cavernous hemangioma of posterior mediastinum treated


*Address for correspondence:

Dr. Bee-Song Chang,
Department of Thoracic Surgery, Hualien Tzu Chi Hospital,
Buddhist Tzu Chi Medical Foundation, 707, Section 3, Chung-Yang Road,
Hualien, Taiwan.
E-mail: rr122336@gmail.com

This is an open access journal, and articles are distributed under the terms of the Creative Commons Attribution-NonCommercial-ShareAlike 4.0 License, which allows others to remix, tweak, and build upon the work non-commercially, as long as appropriate credit is given and the new creations are licensed under the identical terms.

For reprints contact: WKHLRPMedknow_reprints@wolterskluwer.com

How to cite this article: Jhan JY, Cheng YT, Chang JC, Chung BR, Huang NW, Chang BS. Resection of a cavernous hemangioma of the posterior mediastinum by sclerotherapy and uniport thoracoscopic surgery. *Tzu Chi Med J* 2020; 32(3): 301-2.

Access this article online	
Quick Response Code:	Website: www.tcmjmed.com
	DOI: 10.4103/tcmj.tcmj_168_19

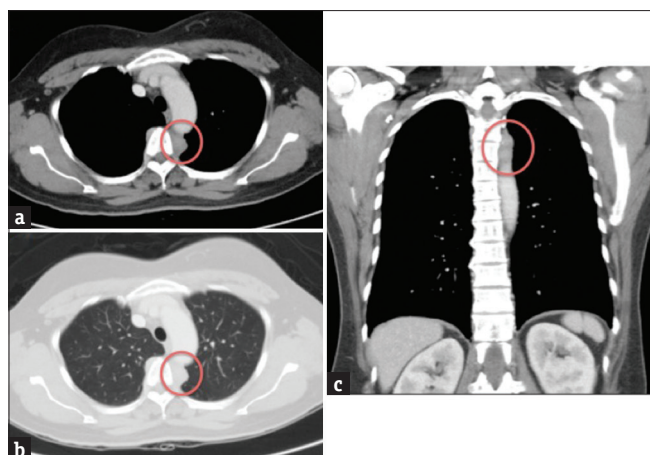


Figure 1: (a) Mild contrast-enhanced at venous phase. (b) No adhesion to lung under lung window.; (c) Coronal section showed tumor around T3~T4 region

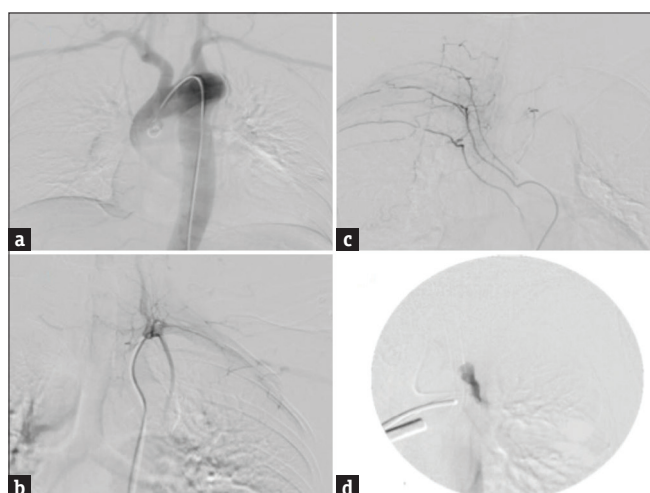


Figure 3: (a) Aortography showed no obvious feeding vessels to tumor. (b) Left internal mammary artery angiography showed no obvious feeding vessels to tumor. (c) Spine artery angiography showed no obvious feeding vessels to tumor. (d) Intraoperative angiography showed contrast only in tumor

by intraoperative sclerotherapy and uniport thoracoscopic resection were found in PubMed. In conclusion, cavernous hemangioma of the posterior mediastinum is rare, and surgical resection is an accepted treatment option. Successful resection of cavernous hemangioma with a good surgical outcome was achieved by uniport thoracoscopy with intraoperative sclerotherapy.

Institutional Review Board approval

The report had been approved by the Research Ethics Committee of Hualien Tzu Chi Hospital, Buddhist Tzu Chi Medical Foundation, for case report publication. The Institutional Review Board (CR 108-02) agrees to waive the patient consent.

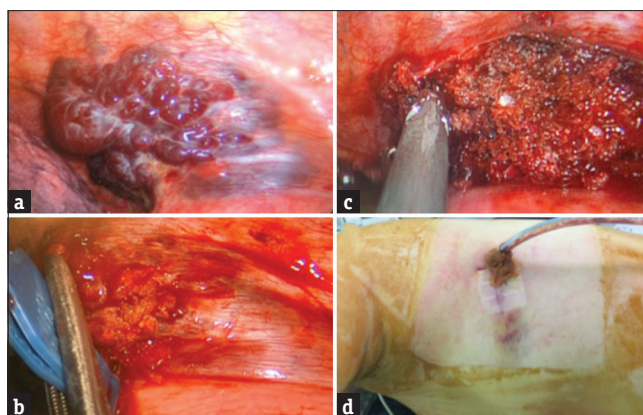


Figure 2: (a) Vascular tumor was detected under thoracoscopy. The tumor was irregular shape with visible blood vessels. (b) Histoacryl tissue coagulant mixed with lipiodol 1:2 was injected into tumor. (c) Tumor was resected via harmonic energy device. (d) One chest tube and small surgical wound about 3 cm

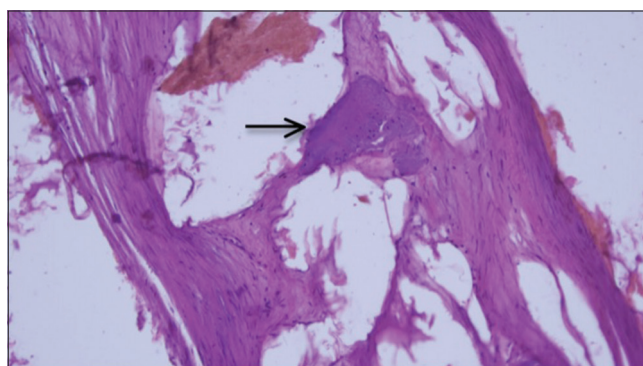


Figure 4: Cavernous hemangioma is diagnosed with blood vessels and thrombus formation (arrow site) (H and E, ×400)

Financial support and sponsorship

Nil.

Conflicts of interest

There are no conflicts of interest.

REFERENCES

1. Yun T, Suzuki H, Tagawa T, Iwata T, Mizobuchi T, Yoshida S, et al. Cavernous hemangioma of the posterior mediastinum with bony invasion. *Gen Thorac Cardiovasc Surg* 2016;64:43-6.
2. Thakare ND, Sajid S, Shende SP. Giant cavernous hemangioma of rib: A rare presentation. *Asian Cardiovasc Thorac Ann* 2017;25:70-1.
3. Shimizu K, Yamashita Y, Hihara J, Seto Y, Toge T. Cavernous hemangioma of the rib. *Ann Thorac Surg* 2002;74:932-4.
4. Ampollini L, Carbognani P, Cattalani L, Bilancia R, Rusca M. Cavernous hemangioma of the posterior mediastinum. *Ann Thorac Surg* 2010;90:e96.
5. Liu XJ, Qin ZP, Tai MZ. Angiographic classification and sclerotic therapy of maxillofacial cavernous haemangiomas: A report of 204 cases. *J Int Med Res* 2009;37:1285-92.