



## Case Report

# A rare complication of ipsilateral femoral neck fracture after removal of the long Gamma nail in a healed intertrochanteric fracture

Chin-Kai Huang<sup>a</sup>, Chih-Kai Hong<sup>a</sup>, Wei-Ren Su<sup>a</sup>, Yi-Hung Huang<sup>b</sup>, Lin-Yu Chao<sup>b\*</sup>

<sup>a</sup>Department of Orthopaedic Surgery, National Cheng Kung University Hospital, College of Medicine, National Cheng Kung University, Tainan, Taiwan,

<sup>b</sup>Department of Orthopaedic Surgery, Ditmanson Medical Foundation Chia-Yi Christian Hospital, Chiayi, Taiwan

**Submission** : 19-Oct-2018  
**Revision** : 19-Nov-2018  
**Acceptance** : 29-Nov-2018  
**Web Publication** : 15-Jan-2019

### ABSTRACT

Ipsilateral femoral neck fracture after hardware removal in healed trochanteric fracture is a rare complication. We reported a case of a 79-year-old woman who had undergone open reduction and internal fixation for her left intertrochanteric fracture with a long Gamma nail about 1 year ago. She asked for implants removal due to local irritation. However, 5 days after implants removal, left subcapital femoral neck fracture occurred. Removal of implants under elective indications could lead to high complication rate. Orthopedic surgeons should perform the removal of hardware in healed intertrochanteric fracture for very selected cases.

**KEYWORDS:** Femoral neck fracture, Hardware removal, Internal fixation, Spontaneous fracture, Trochanteric fracture

## INTRODUCTION

Hip fractures, including femoral neck and trochanteric fractures, commonly occur in the elderly with low-energy falls and often cause mortality and morbidity [1]. Trochanteric fractures, accounting for more than half of the hip fractures [2], are usually treated with internal fixation surgeries, either with intramedullary nailing or with screw-plate fixation [3].

Although hardware removal after bone healing is not a routine procedure for senile hip fractures, it would sometimes be performed for the patients due to implants irritation or patients' demand in clinical practice. However, complications would possibly occur. Kovar *et al.* evaluated the complications after implant removal in patients with proximal femur fractures; their results showed a higher complication rate for patients with nonmedical indication for the removal of implant, and proximal femur fracture was one of them [4].

Ipsilateral femoral neck fracture after implants removal in healed trochanteric fractures is rare, with only 45 cases reported around the world before 2017 [5], which would cause much impact on the patients. Here, we report a case with ipsilateral femoral neck fracture after implants removal in a healed trochanteric fracture. We aimed to remind the clinicians to be aware of this possible complication during decision-making with the patients.

## CASE REPORT

The patient was a 79-year-old female with hypertension. She incurred a left intertrochanteric fracture after a falling

accident [Figure 1a]. A few hours later, the patient underwent the surgery of open reduction and internal fixation with a long Gamma3™ nail (Stryker, Mahwah, NJ, USA) [Figure 1b]. Four years after the surgery, the patient asked for removal of the implants due to persistent left hip foreign body sensation after union of the fracture [Figure 2a]. The patient underwent the surgery of implants removal with smooth course [Figure 2b]. After the surgery, the patient recovered smoothly, and she was discharged on postoperative day 1. We have asked her to use a crutch for assistance for 6 weeks. Five days after the surgery, however, the patient hurt her left hip again after a twist movement. She denied direct force impaction at left hip from a falling down injury. X-ray showed left subcapital femoral neck fracture [Figure 3a]. Finally, the patient underwent cemented bipolar hemiarthroplasty [Figure 3b]. The patient's postoperative course was smooth, and she was discharged on postoperative day 6.

## DISCUSSION

Ipsilateral femoral neck fractures after removal implant from healed trochanteric fractures are rare. Some risk factors have been proposed, including pre-existing systemic osteoporosis, local osteoporosis caused by fixation device,

\*Address for correspondence:

Dr. Lin-Yu Chao,  
Department of Orthopaedic Surgery, Ditmanson Medical Foundation  
Chia-Yi Christian Hospital, 539, Zhongxiao Road,  
East District, Chiayi, Taiwan.  
E-mail: hbrk55@gmail.com

### Access this article online

Quick Response Code:



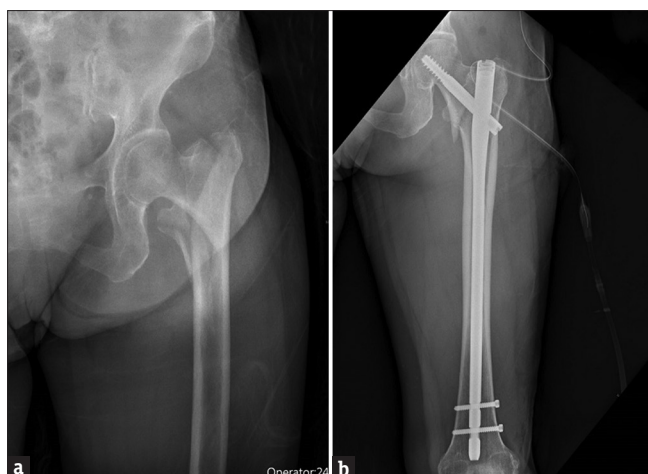
Website: [www.tcmjmed.com](http://www.tcmjmed.com)

DOI: 10.4103/tcmj.tcmj\_188\_18

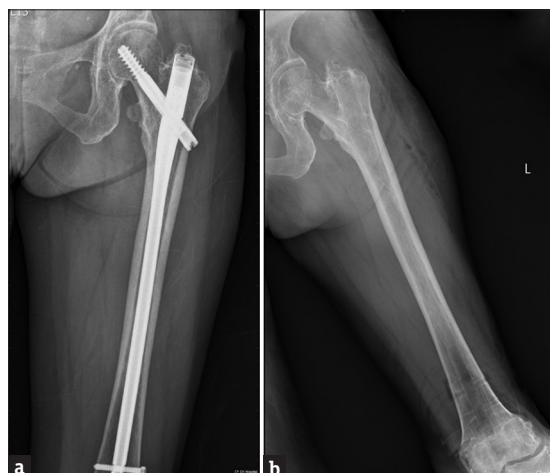This is an open access journal, and articles are distributed under the terms of the Creative Commons Attribution-NonCommercial-ShareAlike 4.0 License, which allows others to remix, tweak, and build upon the work non-commercially, as long as appropriate credit is given and the new creations are licensed under the identical terms.

For reprints contact: [reprints@medknow.com](mailto:reprints@medknow.com)

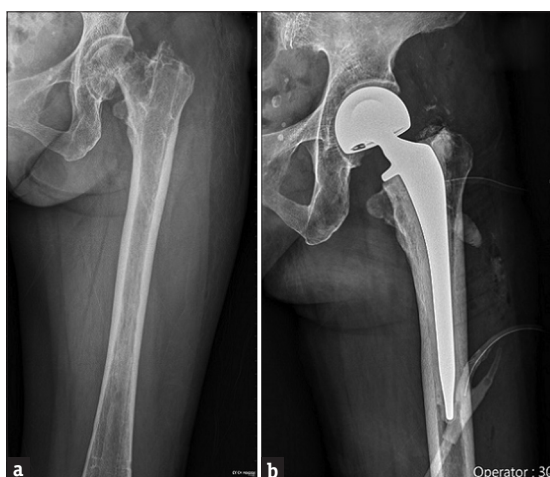**How to cite this article:** Huang CK, Hong CK, Su WR, Huang YH, Chao LY. A rare complication of ipsilateral femoral neck fracture after removal of the long Gamma nail in a healed intertrochanteric fracture. Tzu Chi Med J 2020;32(1):88-90.



**Figure 1:** Left intertrochanteric fracture before (a) and after (b) the operation. Open reduction and internal fixation with a long Gamma3™ nail (Stryker, Mahwah, NJ, USA) was done for the fracture



**Figure 2:** (a) Left femur union before the removal of implants. (b) Left femur after the removal of implants



**Figure 3:** Left femoral fracture before (a) and after (b) the operation. Left ipsilateral subcapital femoral neck fracture was found (a) 5 days after implants removal, and cemented bipolar hemiarthroplasty was done (b) afterward

and decreased failure strength of the neck after implant removal [5]. Among these fractures, subcapital femoral neck

fracture was the most common type, accounting for 95% [5]. In addition, the time from implant removal to fracture ranged from 2 days to 4 months [5]. Most of the fractures seemed to be spontaneous, which was found by pain without a falling or trauma episode [5]. Similar to the characteristics from previous reports, our patient had femoral neck fracture 3 days after removing the implant with only a twist movement rather than falling down.

A previous biomechanical study on cadaveric femur has shown that removal of implant used for trochanteric fracture would significantly lower the fracture force and lead to femoral neck or trochanteric fracture [6]. To prevent these complications, the authors suggested avoiding weight bearing until bone consolidation and implanting bone substitution materials after implants removal [6]. In the literature review, however, no strong evidence on preventing these fractures has been proposed. Further studies on prevention strategies will be needed in the future.

The effects between intramedullary and extramedullary implants on the risk of femoral neck fracture after the removal of implants are still controversial. Kukla *et al.* proposed that the different sizes of cervical components of the implants, 8 mm for dynamic hip screw (DHS) and 12 mm for gamma nail, may play a role in femoral neck fracture after removal in their biomechanical study [6]. However, Yang *et al.* indicated that there were no statistical differences on ultimate load and stiffness between the intramedullary and extramedullary groups [7].

Removal of the implant from proximal femoral fracture under elective indications would lead to high complication rate [4]. Kovar *et al.* reported that 28% of complications occurred after implant removal for nonmedically indicated patients, and fractures accounted for about 20% of them [4]. These complications included wound infection, hematoma formation, leg length discrepancy, delayed wound healing, and nerve damage [4]. Due to the high complication rate, the importance of proper indications and well-informed possible risks before implant removal surgeries cannot be overemphasized. Realistic expectations of removal implant should be made to minimized unnecessary costs and complications [8].

We reported a rare case of ipsilateral femoral neck fracture after removal of implants from healed intertrochanteric fracture. Orthopedic surgeons and patients should be aware of the relatively high incidence of re-fractures, and the removal of implants in healed trochanteric fracture should be only performed for very selected cases.

**Declaration of patient consent**

The authors certify that the patient has obtained the patient inform consent form. In the form, the patient has given her consent for her images and other clinical information to be reported in the journal. The patient understands that her name and initial will not be published and due efforts will be made to conceal her identity, but anonymity cannot be guaranteed.

**Financial support and sponsorship**

Nil.

### Conflicts of interest

There are no conflicts of interest.

### REFERENCES

1. Florschütz AV, Langford JR, Haidukewych GJ, Koval KJ. Femoral neck fractures: Current management. *J Orthop Trauma* 2015;29:121-9.
2. Sambandam SN, Chandrasekharan J, Mounasamy V, Mauffrey C. Intertrochanteric fractures: A review of fixation methods. *Eur J Orthop Surg Traumatol* 2016;26:339-53.
3. Adam P. Treatment of recent trochanteric fracture in adults. *Orthop Traumatol Surg Res* 2014;100:S75-83.
4. Kovar FM, Strasser E, Jaendl M, Endler G, Oberleitner G. Complications following implant removal in patients with proximal femur fractures – An observational study over 16 years. *Orthop Traumatol Surg Res* 2015;101:785-9.
5. Barquet A, Giannoudis PV, Gelink A. Femoral neck fractures after removal of hardware in healed trochanteric fractures. *Injury* 2017;48:2619-24.
6. Kukla C, Pichl W, Prokesch R, Jacyniak W, Heinze G, Gatterer R, et al. Femoral neck fracture after removal of the standard gamma interlocking nail: A cadaveric study to determine factors influencing the biomechanical properties of the proximal femur. *J Biomech* 2001;34:1519-26.
7. Yang JH, Jung TG, Honnurappa AR, Cha JM, Ham CH, Kim TY, et al. The analysis of biomechanical properties of proximal femur after implant removal. *Appl Bionics Biomech* 2016;2016:4987831.
8. Busam ML, Esther RJ, Obrebsky WT. Hardware removal: Indications and expectations. *J Am Acad Orthop Surg* 2006;14:113-20.