



Images in Clinical Medicine

Seizure and left side weakness in a young female: Cerebral venous sinus thrombosis

Wei-An Lai[†], Pei-Wen Chuang[‡], Ming-Jen Tsai^{*}

Department of Emergency Medicine, Ditmanson Medical Foundation Chia-Yi Christian Hospital, Chiayi, Taiwan

[†]Both authors contributed equally to this work.

Received : 07-Dec-2018

Revised : 03-Jan-2019

Accepted : 04-Jan-2019

A 25-year-old female, gravida 1, para 0, abortus 1, without underlying disease presented with severe headache, upward gaze, limbs rigidity, and loss of consciousness for 10 min. She just received dilation and curettage 2 days ago because of fetal death at the 9th week of pregnancy. On arrival, she was conscious. Physical examination revealed decreased muscle power over her left extremities. Laboratory study and electrocardiogram revealed no abnormality. Emergency non-enhanced computed tomography (CT) of the head showed no evidence of intracranial hemorrhage, but increased attenuation in superior sagittal sinus was found [Figure 1, arrows]. She was admitted and confirmed the diagnosis of cerebral venous sinus thrombosis (CVST) by the magnetic resonance imaging (MRI) with venography [Figure 2]. During hospitalization, the awake electroencephalography revealed neither epileptiform discharges nor cortical dysfunction. The anti-nuclear, anticardiolipin, antiphospholipid, and anti-beta 2 glycoprotein antibodies were all negative. The levels of complement 3 and 4 were normal. After the treatment of low-molecular-weight heparin followed by oral anticoagulant, she was discharged without any sequelae 17 days later.

CVST is a rare form of cerebrovascular disease. Distinct from the common cerebral vascular accident, CVST most affects young adults without vascular risk factors [1,2]. Its clinical presentations are highly variable including headache (the most frequent), focal motor weakness, seizure, consciousness disturbance, cognitive dysfunction, behavior symptoms (e.g. delirium, amnesia, and mutism), and even coma [1-3]. Hence, early diagnosis is challenging.

The major risk factors for CVST are prothrombotic states including thrombophilia, pregnancy, the puerperium period, oral contraceptives use, malignancy, infection and head injury [1,2]. Nonenhanced CT a useful way to rule out other etiology including acute hemorrhage and recent ischemic stroke. The primary sign of CVST on nonenhanced CT is hyperdensity of a cortical vein or dural sinus, called the cord sign. However, only approximately one-third of CVST demonstrates this sign [1,4]. MRI with venography is more sensitive examination [1,4].

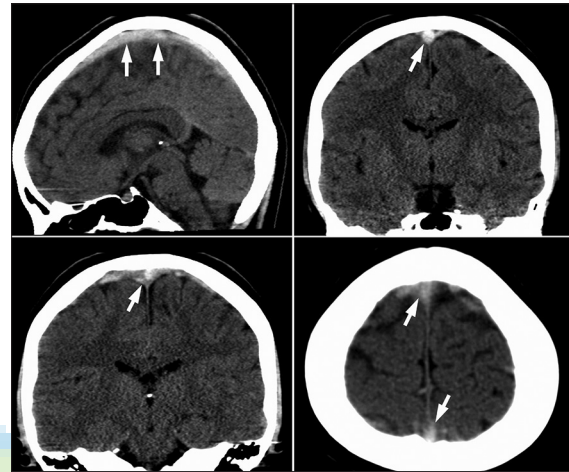


Figure 1: Nonenhanced computed tomography of head showed increased attenuation in superior sagittal sinus (arrows) which indicates the cord sign

However, it is not always available in the emergency department. CT venography showing a filling defect in cerebral sinus or vein can be a faster way of detecting CVST [1,2]. The principal treatment of CVST is anticoagulation and correction of underlying prothrombotic states. Surgical intervention, such as endovascular therapy or decompressive hemicraniectomy may be needed if neurologic deterioration [1,2]. A careful history taking, correct image reading, and highly suspicion in young-aged patients with unusual headache, stroke-like symptoms and without the usual vascular risk factors are the key to diagnosis this disease.

Declaration of patient consent

The authors certify that the patient has obtained appropriate patient consent form. In the form, the patient has given her

*Address for correspondence:

Dr. Ming-Jen Tsai,
Department of Emergency Medicine, Ditmanson Medical Foundation
Chia-Yi Christian Hospital, 539, Zhongxiao Road, East District,
Chiayi, Taiwan.
E-mail: tshi33@gmail.com

Access this article online	
Quick Response Code: 	Website: www.tcmjmed.com
	DOI: 10.4103/tcmj.tcmj_6_19

This is an open access journal, and articles are distributed under the terms of the Creative Commons Attribution-NonCommercial-ShareAlike 4.0 License, which allows others to remix, tweak, and build upon the work non-commercially, as long as appropriate credit is given and the new creations are licensed under the identical terms.

For reprints contact: reprints@medknow.com

How to cite this article: Lai WA, Chuang PW, Tsai MJ. Seizure and left side weakness in a young female: Cerebral venous sinus thrombosis. Tzu Chi Med J 2019;31(3):198-9.

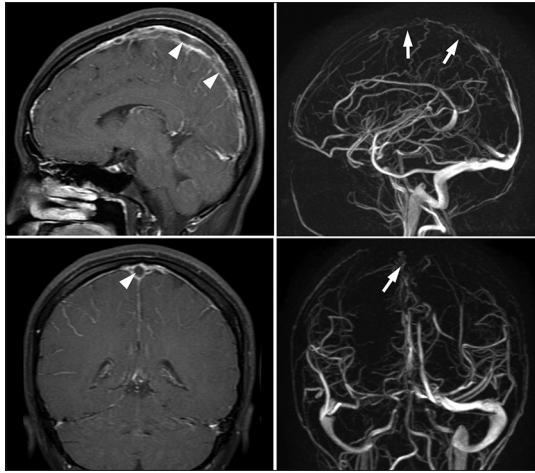


Figure 2: Magnetic resonance imaging T1-weighted fast spin echo with contrast showed high signal subacute clot in superior sagittal sinus (arrowheads in the left upper and lower figures). Magnetic resonance imaging venography showed decreased venous flow in superior sagittal sinus (arrows in right upper and lower figures)

consent for her images and other clinical information to be reported in the journal. The patient understands that her name

and initial will not be published and due efforts will be made to conceal her identity, but anonymity cannot be guaranteed.

Financial support and sponsorship

Nil.

Conflicts of interest

There are no conflicts of interest.

REFERENCES

1. Saposnik G, Barinagarrementeria F, Brown RD Jr., Bushnell CD, Cucchiara B, Cushman M, et al. Diagnosis and management of cerebral venous thrombosis: A statement for healthcare professionals from the American Heart Association/American Stroke Association. *Stroke* 2011;42:1158-92.
2. Stam J. Thrombosis of the cerebral veins and sinuses. *N Engl J Med* 2005;352:1791-8.
3. Gunes HN, Cokal BG, Guler SK, Yoldas TK, Malkan UY, Demircan CS, et al. Clinical associations, biological risk factors and outcomes of cerebral venous sinus thrombosis. *J Int Med Res* 2016;44:1454-61.
4. Linn J, Pfefferkorn T, Ivanicova K, Müller-Schunk S, Hartz S, Wiesmann M, et al. Noncontrast CT in deep cerebral venous thrombosis and sinus thrombosis: Comparison of its diagnostic value for both entities. *AJNR Am J Neuroradiol* 2009;30:728-35.

