



Case Report

Anaplastic sarcoma of the kidney: Case report and literature review

Chien-Chin Chen^{a,b}, Kai-Sheng Liao^{a,c*}

^aDepartment of Pathology, Ditmanson Medical Foundation, Chiayi Christian Hospital, Chiayi, Taiwan, ^bDepartment of Cosmetic Science, Chia Nan University of Pharmacy and Science, Tainan, Taiwan, ^cDepartment of Nursing, Chung-Jen College of Nursing, Health Sciences and Management, Chiayi, Taiwan

Received : 01-Aug-2018
Revised : 03-Sep-2018
Accepted : 02-Oct-2018

ABSTRACT

We present a case of a 22-year-old female with gross hematuria for 1 month. A 9.5-cm tumor was found at her left kidney. On suspicion of a renal cancer, she received left nephrectomy. Histologically, it was a hypercellular tumor with undifferentiated anaplastic neoplastic cells in fascicular sheets intermixed with chondroid nodules. The differential diagnoses included anaplastic sarcoma of the kidney (ASK), anaplastic Wilms tumor, mesenchymal chondrosarcoma, sarcomatoid renal cell carcinoma, clear cell sarcoma of the kidney, rhabdoid tumor of the kidney, congenital mesoblastic nephroma, and synovial sarcoma. Based on the results of the work-up and literature review, ASK was diagnosed. The postoperative recovery was uneventful, and the patient began adjuvant chemotherapy (Ifosfamide [1800 mg/m²] and Epirubicin [60 mg/m²]) 5 weeks after the operation. Herein, we present this case to share the experience on an extremely rare entity.

KEYWORDS: *Anaplastic sarcoma, Mesenchymal chondrosarcoma, Renal tumor, Sarcomatoid carcinoma, Wilms tumor*

INTRODUCTION

Anaplastic sarcoma of the kidney (ASK) is one of the rarest renal tumors. It is a hypercellular spindle cell tumor with widespread anaplastic changes plus chondroid differentiation in most cases. Only seven reports comprising 25 cases of ASK have been published in the English literature since Vujančić *et al.* first coined this term in 2007 [1-7]. The histopathological differential diagnosis includes anaplastic Wilms tumor, mesenchymal chondrosarcoma, and sarcomatoid renal cell carcinoma. With no standardized treatment protocol, nephrectomy combined with adjuvant chemotherapy is the treatment modality applied to most of the patients. The prognosis is variable and appears to correlate with tumor staging.

CASE REPORT

A 22-year-old woman with a history of asthma presented with gross hematuria for 1 month. She had visited local clinics where microcytic anemia was suspected. She visited our urology outpatient department for a second opinion. On physical examination, mild knocking pain was noted in her left flank. Urinalysis showed hematuria and mild pyuria. Abdominal ultrasonography showed a 9 cm iso- and hypo-echogenic renal mass, at the lower pole of her left kidney. A left renal malignancy with a perirenal hematoma was seen on computed tomography of the abdomen [Figure 1a]. She received a left radical nephrectomy.

The resected kidney measured 16 cm × 15 cm × 5 cm. The kidney and perinephric tissue showed multiple foci of

hemorrhage with a large hematoma. After cutting, there was one 9.5 cm × 7 cm × 4.5 cm tumorous mass at the lower pole of the kidney consisting of solid white components and hemorrhagic soft components [Figure 1b]. The tumor invaded the renal parenchyma, renal pelvis, and perinephric soft tissue.

Microscopically, the tumor was composed mainly of sheets of spindle or oval undifferentiated cells admixed with foci of abrupt differentiation of cartilaginous nodules [Figure 2a]. The undifferentiated cells had ovoid to elongated hyperchromatic nuclei, indistinct cell borders and brisk mitoses (up to 20 mitoses per 10 high power fields) [Figure 2b]. Intermixed were some hemangiopericytoma-like vascular channels. Anaplastic cells with atypical mitoses or multinucleation were readily identified. Small areas of primitive blastema-like small blue round cells could also be observed within the undifferentiated component. For the cartilaginous nodules, the neoplastic chondroid cells also displayed atypical, enlarged and hyperchromatic nuclei, suggestive of a malignant morphology [Figure 2c]. No neoplastic epithelial elements, such as abortive tubules and glomeruli formation, were found in the tumor.

Immunohistochemically, the undifferentiated component showed immunoreactivity for desmin, myogenin [Figure 2d], vimentin, and neuron-specific enolase (focal), but were

*Address for correspondence:

Dr. Kai-Sheng Liao,
Department of Pathology, Ditmanson Medical Foundation, Chiayi Christian Hospital, No. 539, Zhongxiao Road, East District, Chiayi, Taiwan.
E-mail: carl.liao@gmail.com

Access this article online

Quick Response Code:



Website: www.tcmjmed.com

DOI: 10.4103/tcmj.tcmj_194_18

This is an open access journal, and articles are distributed under the terms of the Creative Commons Attribution-NonCommercial-ShareAlike 4.0 License, which allows others to remix, tweak, and build upon the work non-commercially, as long as appropriate credit is given and the new creations are licensed under the identical terms.

For reprints contact: reprints@medknow.com

How to cite this article: Chen CC, Liao KS. Anaplastic sarcoma of the kidney: Case report and literature review. Tzu Chi Med J 2019;31(2):129-32.

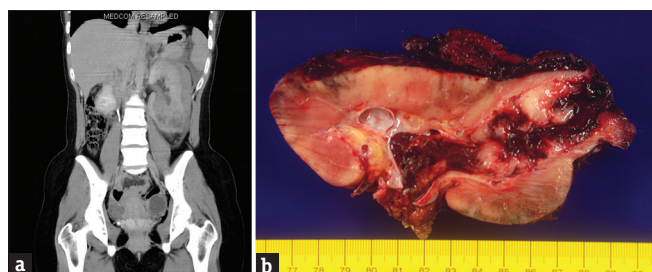


Figure 1: (a) Noncontrast computed tomography scan shows a tumorous mass at the left lower pole of the left kidney with a perirenal hematoma. (b) A 9.5-cm fragile solid hemorrhagic renal tumor is seen protruding into the renal pelvis and invading perinephric soft tissue

non-reactive for cytokeratin, smooth muscle actin, leukocyte common antigen, CD99, melan-A, inhibin-A, and HMB-45. The Ki-67 proliferation index was approximately 85%. The cartilaginous component was immunoreactive for S-100. The results of the WT1 stain were negative for both components. In summary, this was a sarcomatous tumor with focal myxoid and chondroid differentiation. ASK was diagnosed after a literature review. The patient's postoperative recovery was uneventful, and she began adjuvant chemotherapy (ifosfamide [1800 mg/m²] and epirubicin [60 mg/m²]) 5 weeks after the operation. The patient remained disease-free for 3 months after the operation.

DISCUSSION

ASK is a newly recognized neoplasm of the kidney, first described by Vujančić *et al.* in 2007 [1]. They reviewed 13,000 cases of Wilms tumor and found 20 cases originally diagnosed as "unusual" anaplastic Wilms tumors with unique clinical and pathological characteristics. This led to the discovery of a new entity called "ASK." Similar to our case, the majority of these tumors presented as a large renal mass affecting females. The right kidney is the preferred site, which differs from the present case. The age distribution of patients ranges from 10 months to 41 years [1]. The gross findings of ASK in the literature were mostly solid with an occasional cystic component (up to one-third of the cases). The tumors ranged from 4 to 22 cm in diameter.⁴ Protrusion into the renal sinus could be seen in some of the cases, including our case. Table 1 summarizes the clinical characteristics, macroscopic, and microscopic features, treatment, and outcomes of the 25 cases patients with ASK in the literature, including the present one.

Histologically, ASK is composed of sheets of undifferentiated spindle cells with marked anaplasia and atypical mitotic figures. Rhabdoid differentiation is occasionally seen. Although morphologically rhabdoid cells cannot be found in this tumor, the rhabdoid phenotype can be clearly demonstrated by desmin and myogenin positivity in the anaplastic cells. There may also be foci of undifferentiated small round primitive mesenchymal cells (blastema-like cells). Chondroid differentiation with both benign and malignant morphology is readily seen. A myxoid matrix may be seen focally. The main pathological differential diagnosis includes anaplastic Wilms tumor, mesenchymal chondrosarcoma, sarcomatoid carcinoma, clear cell sarcoma of the kidney, rhabdoid tumor of the kidney, congenital mesoblastic nephroma, rhabdomyosarcoma, and synovial sarcoma.

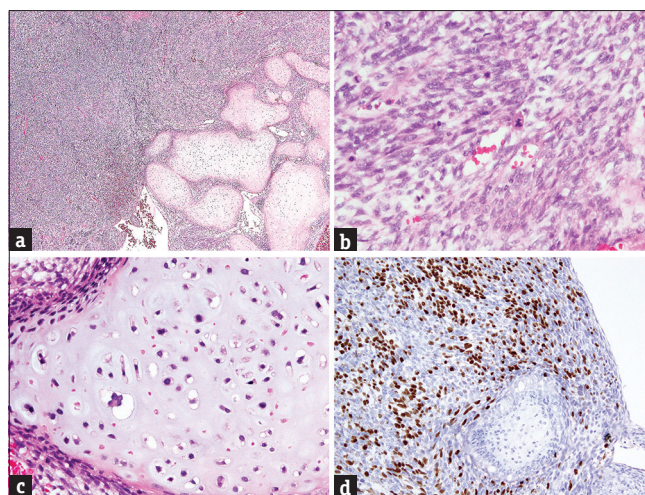


Figure 2: (a) Histopathologically, the tumor is composed of sheets of undifferentiated components and abrupt differentiation of cartilaginous nodules (H and E, ×40). (b) The undifferentiated cells have elongated hyperchromatic nuclei, indistinct cell borders, and atypical mitoses (H and E, ×400). (c) The neoplastic chondroid cells have atypical enlarged and hyperchromatic nuclei, suggestive of a malignant morphology (H and E, ×400). (d) The undifferentiated component is immunoreactive for myogenin while the neoplastic chondroid cells are not (×200) (Clone EP162, Bio SB)

Heterologous chondroid differentiation may be observed in ASK, anaplastic Wilms tumor, sarcomatoid carcinoma, and mesenchymal chondrosarcoma, but is rarely seen in clear cell sarcoma of the kidney, rhabdoid tumor of the kidney, congenital mesoblastic nephroma, rhabdomyosarcoma, and synovial sarcoma.

According to Arabi *et al.* [6], the most important entity to differentiate is anaplastic Wilms tumor. In contrast to anaplastic Wilms tumor, large areas of anaplastic cells and cartilage, absence of large areas of blastema-like cells, and WT1 negativity may favor a diagnosis of ASK.

In our case, based on the patient's age, mesenchymal chondrosarcoma was also a possible diagnosis. However, large areas of undifferentiated cells with myogenin positivity along with CD99 negativity argued against such a diagnosis.

For the remaining entities in the differential diagnosis, sarcomatoid carcinoma, rhabdoid tumor, and synovial sarcoma would typically show at least focal positivity of EMA and CK stains, but the results of these two stains were negative in this tumor.

Clear cell sarcoma of the kidney would display diffuse and strong cyclin D1 immunoreactivity [5], while the result of this stain was only focally positive for this tumor. Cellular congenital mesoblastic nephroma could be excluded by the negative stain for smooth muscle actin and the extensive presence of chondroid differentiation.

In addition, given that at least biphenotypic differentiation (rhabdoid and chondroid) were observed within the tumor, a malignant mesenchymoma might be considered. However, this term has been discouraged since the publication of the WHO classification of tumors of bone and soft tissue in 2013 [8].

Table 1: Clinical characteristics, macroscopic, and microscopic features treatment and outcomes of 25 patients with anaplastic sarcoma of kidney in the English literature

Case	Age	Sex	Side	Stage	Gross findings	Tumor size (cm)
1*	7 months	Female	L	I	Not visible on gross examination	Microscopic foci
2	10 months	Female	R	N/A	Exophytic tumor	15
3	11 months	Male	R	N/A	Multimodular solid/cystic tumor	7.5
4	1.5 years	Male	R	I	Solid/cystic mass protruding into the renal pelvis	10
5	3 years	Female	L	I	N/A	15
6**	3 years	Female	R	III	Multiloculated cystic mass with focal solid areas	19
7	3.3 years	Female	R	II	N/A	16
8	4 years	Female	L	I	N/A	N/A
9	4 years	Male	L	II	N/A	N/A
10	4.3 years	Male	N/A	III	Exophytic tumor	21
11	4.8 years	Male	R	II	N/A	11
12	5 years	Male	R	III	N/A	13
13	8 years	Female	R	I	N/A	4
14	10 years	Male	L	I	Nodular mass protruding into the renal pelvis	17
15****	12 years	Female	R	IV	Frangible/cystic tumor with necrosis and focal invasion in the renal pelvis	17
16	13 years	Female	N/A	II	N/A	N/A
17	13 years	Male	N/A	III	Lobular mass	17
18****	13 years	Male	R	III	Friable solid tumor	16
19	15 years	Female	R	I	Solid mass encroaching the sinus	10.5
20	17 years	Female	R	IV	N/A	N/A
21*****	24 years	Female	R	II	Solid/cystic mass	22
22	29 years	Female	R	N/A	Solid/cystic mass	10
23	30 years	Female	R	N/A	Necrotic tumor in the renal pelvis	15
24	35 years	Female	R	N/A	Nodular tumor with cystic areas	7.5
25	41 years	Female	L	I	Polypoid tumor projecting into the dilated renal pelvis	14
26 (present)	22 years	Female	L	III	Frangible solid tumor protruding into the renal pelvis and invading the perirenal soft tissue	9.5

Anaplastic spindle cells	Chondroid differentiation	Initial diagnosis	Treatment	Outcome
+++	-	CPDN	N	NED 1 years
++	++	MM or RMS	C+N	Unknown
+++	+++	AWT or MM	N+C	Unknown
+++	-	AWT	N+C	NED 13 years
+++	+++	AWT	N+C	NED 14 years
+++	+++	ASK	N+C	Unknown
+++	-	AWT	C+N+C	NED 9 years
+++	+++	AWT	N+C	NED 9 years
+++	+	AWT	C+N+C	NED 6 years
+++	++	AWT or MM	N+C	Unknown
+++	-	AWT	C+N+C	NED 7 years
+++	+++	AWT	R+N+C	DOD 1.5 years +R

Contid...

Table 1: Contd...

Anaplastic spindle cells	Chondroid differentiation	Initial diagnosis	Treatment	Outcome
+++	++	AWT	C+N+C	NED 8 years
+++	++	sarcomatoid RCC	N+C	NED 8 years
+++	++	Unclassified anaplastic sarcoma with rhabdomyomatous and cartilaginous differentiation	N+C+R	NED 2.3 years
+++	++	Anaplastic mesenchymoma	C+N	Unknown
++	+	AWT	C+N+C	NED 2 years
+++	++	AWT (soon revised to ASK)	N+C+R	DOD 1.5 years
+++	+	AWT	N	Unknown
+++	++	MM	Resection	DOD 1.2 years
+++	++	AWT	N+C+R	NED 2.5 years
+	++	MM	N	Unknown
++	-	Malignant mesenchymal tumor of kidney	N+C	NED 3 years
++	++	AWT or MM	N	Unknown
+++	++	AWT or fibrosarcoma with cartilaginous differentiation	N+C	DOD 2 years
+++	++	Malignant mesenchymal tumor of the kidney	N+C	Unknown

Citation: *Reference 7; **Reference 3; ***Reference 4; ****Reference 2; the remaining cases were cited from reference 1. ASK: Anaplastic sarcoma of kidney, AWT: Anaplastic Wilms tumor, C: Chemotherapy, CPDN: Cystic partially differentiated nephroblastoma; DOD: Died of disease, L: Left, MM: Malignant mesenchymoma, N: Nephrectomy, N/A: Not available, NED: No evidence of disease, R: Right, RCC: Renal cell carcinoma, RMS: Rhabdomyosarcoma, For anaplastic spindle cells - +: Focally present; +++: Extensively present; ++: Between+and +++: Focally present; ++: Extensively present; +: Between+and +++

After a literature review, ASK best fit the picture in the present case, although this entity was not included in the latest edition of the WHO classification of tumors of the urinary system and male genital organs [9].

Most reported cases were treated by surgery with combined chemotherapy using the Wilms tumor or Ewing sarcoma protocol. The reported outcomes seem to correlate with tumor staging, ranging from death in 1.2 years in a Stage-IV case to free of disease after 14 years in a Stage-I case [4]. The present case was Stage III, which has had variable reported outcomes from death in 1.5 years to free of disease in 2 years [4]. Long-term follow-up is necessary.

Acknowledgments

We would like to thank Dr. Pan, Chin-Chen, a pathologist specializing in renal and urinary pathology at Taipei Veterans General Hospital, Taipei, Taiwan, for consulting on this case.

Declaration of patient consent

The authors certify that the patient has obtained an appropriate patient consent form. In the form, the patient has given her consent for her images and other clinical information to be reported in the journal. The patient understands that her name and initials will not be published and due efforts will be made to conceal her identity, but anonymity cannot be guaranteed.

Financial support and sponsorship

Nil.

Conflicts of interest

There are no conflicts of interest.

REFERENCES

- Vujančić GM, Kelsey A, Perlman EJ, Sandstedt B, Beckwith JB. Anaplastic sarcoma of the kidney: A clinicopathologic study of 20 cases of a new entity with polyphenotypic features. *Am J Surg Pathol* 2007;31:1459-68.
- Labanaris A, Zugor V, Smiszek R, Nützel R, Kühn R. Anaplastic sarcoma of the kidney. *ScientificWorldJournal* 2009;9:97-101.
- Gomi K, Hamanoue S, Tanaka M, Matsumoto M, Kitagawa N, Niwa T, et al. Anaplastic sarcoma of the kidney with chromosomal abnormality: First report on cytogenetic findings. *Hum Pathol* 2010;41:1495-9.
- Watanabe N, Omagari D, Yamada T, Nemoto N, Furuya T, Sugito K, et al. Anaplastic sarcoma of the kidney: Case report and literature review. *Pediatr Int* 2013;55:e129-32.
- Mirkovic J, Calicchio M, Fletcher CD, Perez-Atayde AR. Diffuse and strong cyclin D1 immunoreactivity in clear cell sarcoma of the kidney. *Histopathology* 2015;67:306-12.
- Arabi H, Al-Maghraby H, Yamani A, Yousef Y, Huwait H. Anaplastic sarcoma of the kidney: A rare unique renal neoplasm. *Int J Surg Pathol* 2016;24:556-61.
- Wu MK, Cotter MB, Pears J, McDermott MB, Fabian MR, Foulkes WD, et al. Tumor progression in DICER1-mutated cystic nephroma-witnessing the genesis of anaplastic sarcoma of the kidney. *Hum Pathol* 2016;53:114-20.
- Fletcher CD, Bridge JA, Hogendoorn CW, Mertens F. WHO Classification of tumors of bone and soft tissue. 4th ed. International Agency for Research on Cancer (IARC); 2013. p. 193-238.
- Moch H, Humphrey PA, Ulbright TM, Reuter VE. WHO classification of tumors of urinary system and male genital organs. 4th ed. IARC; 2016. p. 11-76.