



## Case Report

# A rare case of cefepime-induced cholestatic liver injury

Pei-Fei Liao<sup>a</sup>, Yao-Kuang Wu<sup>b,c</sup>, Kuo-Liang Huang<sup>b</sup>, Hsin-Yi Chen<sup>b\*</sup>

<sup>a</sup>Department of Pharmacy, Taipei Tzu Chi Hospital, Buddhist Tzu Chi Medical Foundation, New Taipei, Taiwan, <sup>b</sup>Division of Pulmonary Medicine, Department of Internal Medicine, Taipei Tzu Chi Hospital, Buddhist Tzu Chi Medical Foundation, New Taipei, Taiwan, <sup>c</sup>School of Medicine, Tzu Chi University, Hualien, Taiwan

Received : 05-Jan-2018  
Revised : 02-Apr-2018  
Accepted : 02-Aug-2018

### ABSTRACT

Cefepime is widely used in the hospital setting, and only a few studies have reported neurotoxicity and nephrotoxicity as side effects of this drug. Herein, we present a 93-year-old man who exhibited features of cholestatic hepatitis including elevated blood transaminases and direct-form predominant bilirubin levels after administration of cefepime. Blood liver tests showed total recovery after discontinuing the offending agent. Cefepime was probable to cause drug-induced cholestatic hepatitis in our patient since the Roussel Uclaf Causality Assessment Method score for cefepime was 7. No drug interactions were likely according to the Drug Interaction Probability Scale for this patient. No similar cases of cholestatic drug-induced liver injury related to cefepime have been reported previously. Hence, this rare condition requires a high degree of clinical suspicion for prompt diagnosis and treatment.

**KEYWORDS:** *Cefepime, Cholestasis, Drug-induced liver injury*

### INTRODUCTION

Drug-induced liver injury (DILI) is important in the differential diagnosis in patients with abnormal liver tests and normal hepatobiliary imaging. A diagnosis of DILI is a challenge for health-care providers and probably one of the most difficult to establish among liver diseases [1]. Antibiotics are the most common type of offending drugs reported in major studies of DILI. The incidence of DILI caused by antibiotics in some large prospective and retrospective studies ranged from 3 to 6 per 100,000 individuals [2-5]. Cephalosporins are widely used antibiotics and well tolerated. Most reports of cephalosporin-induced liver injury are case reports [6-11], and these antibiotics account for about 1% of DILI in prospective studies [3-5]. Cefepime is a parenteral fourth-generation cephalosporin with an extended spectrum of antimicrobial activity and is prescribed for a variety of hospital-acquired infections. It is considered well-tolerated and is associated with few adverse reactions [12]. Although cefepime-induced neurotoxicity and nephrotoxicity have been reported in recent years, there are currently no formal reports of hepatic injury caused by this drug. In this report, we describe an elderly man with no history of the liver disease who developed cholestatic hepatitis after administration of cefepime. The Roussel Uclaf Causality Assessment Method (RUCAM) [13] was used to quantitatively assess causality in the medication-induced liver injury in our patient.

### CASE REPORT

A 93-year-old man presented to the emergency room of a teaching hospital with a 4-day history of progressive dyspnea

and general fatigue. He complained of dizziness, exertional dyspnea, and productive cough. The patient denied other constitutional and abdominal symptoms except for poor appetite. His medical history included dementia, chronic obstructive pulmonary disease (COPD), diabetes mellitus, congestive heart failure New York Heart Association functional classification III, and macrocytic anemia without a definite diagnosis for 6 years. He refused medical control for heart failure and COPD and took some over-the-counter iron and vitamin supplements. In the past 2 years, he had developed frequent dyspnea even at rest, and general malaise resulting from severe anemia with hemoglobin (Hb) levels down to 3–4 g/dL and acute exacerbation of COPD. He had been receiving blood transfusions, initially once every 2 months, but this had increased to every 2 weeks over the past 2 months. He was an ex-smoker and had smoked 1 pack per day for 40 years but had quit 30 years previously. He had no history of liver disease, excessive alcohol consumption, recent travel, infectious symptoms, intravenous drug use or environmental exposure history. He had been admitted twice for pneumonia, once 2 years ago and again 3 months ago. Cefuroxime was given during his first admission, and amoxicillin 875 mg/clavulanic acid 125 mg intravenously was used in the second admission. Other medications including ipratropium bromide and

\*Address for correspondence:

Dr. Hsin-Yi Chen,  
Division of Pulmonary Medicine, Department of Internal Medicine,  
Taipei Tzu Chi Hospital, Buddhist Tzu Chi Medical Foundation,  
289, Jianguo Road, Xindian District, New Taipei, Taiwan.  
E-mail: dtmed196@hotmail.com

#### Access this article online

##### Quick Response Code:



Website: [www.tcmjmed.com](http://www.tcmjmed.com)

DOI: 10.4103/tcmj.tcmj\_151\_18

This is an open access journal, and articles are distributed under the terms of the Creative Commons Attribution-NonCommercial-ShareAlike 4.0 License, which allows others to remix, tweak, and build upon the work non-commercially, as long as appropriate credit is given and the new creations are licensed under the identical terms.

For reprints contact: [reprints@medknow.com](mailto:reprints@medknow.com)

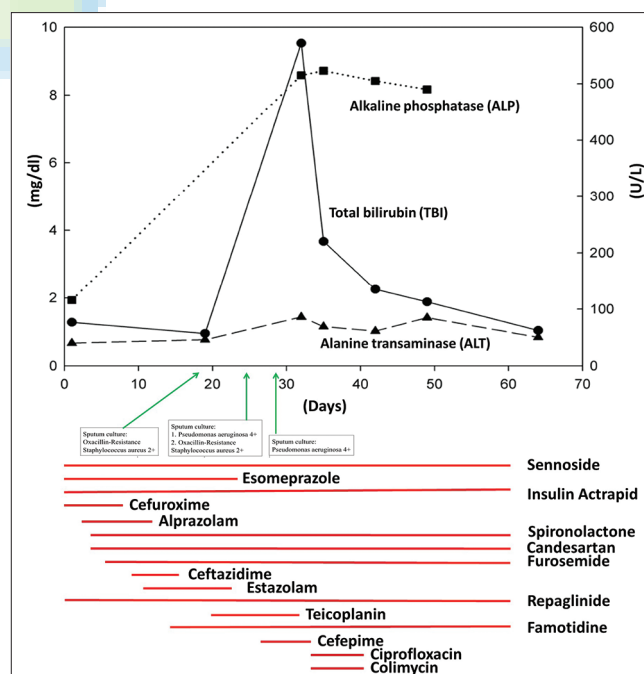
How to cite this article: Liao PF, Wu YK, Huang KL, Chen HY. A rare case of cefepime-induced cholestatic liver injury. *Tzu Chi Med J* 2019;31(2):124-8.

terbutaline sulfate solutions by nebulizer, methylprednisolone, and furosemide intravenous injection were given each time he came to the emergency department for red-blood-cell transfusions and concurrent acute exacerbation of COPD over the past 2 years. The physical examination in the emergency department revealed he was afebrile with a clear consciousness, regular heartbeat at 92 beats/min, pale conjunctivae, and mild wheezing. The jugular vein was not engorged. There was no lymphadenopathy, abdominal tenderness, hepatosplenomegaly, or stigmata of chronic liver disease. Laboratory results showed severe normocytic anemia with an Hb level of 4.5 g/dL. The white blood cell (WBC) and platelet counts were normal. The serum total bilirubin was mildly elevated (1.28 mg/dL), but the hepatic enzymes and renal profile were normal. There were elevated levels of C-reactive protein (CRP) 1.38 mg/dL and N-terminal pro-brain natriuretic peptide 2905 pg/mL. A plain chest radiograph showed some reticular interstitial infiltration over the subpleural and bilateral lower lung fields. There was no interval change compared with 2 months previously. The initial peripheral oxygen saturation (SpO<sub>2</sub>) was 98% under ambient air, but he experienced diffuse wheezing with SpO<sub>2</sub> 88% under nasal cannula 3 L/min 1 h after arrival. Despite use of a non-rebreathing mask with O<sub>2</sub> 15 L/min, ipratropium bromide and terbutaline sulfate inhalation, the patient became stuporous and arterial blood gases showed respiratory acidosis and hypoxemia (pH 7.276, PaCO<sub>2</sub> 63.3 mmHg, PaO<sub>2</sub> 46.2 mmHg). He was intubated and transferred to the Intensive Care Unit (ICU) 3 hours after arrival.

On admission to the ICU, the patient had sinus tachycardia of 124/min but no shock, and a fever with a body temperature 38.5°C. Although chest radiography after intubation showed no new lung lesions or pulmonary edema, empiric cefuroxime intravenous injection was given for purulent sputum from endotracheal suction, which suggested a secondary lower airway infection. Ipratropium bromide, terbutaline sulfate, and mechanical ventilation were used for acute exacerbation of COPD with hypercapnic respiratory failure. Furosemide and candesartan cilexetil were given for heart failure. On the 3<sup>rd</sup> hospital day, his respiratory distress had improved and the bronchodilators were shifted to salmeterol 25 mcg/fluticasone 125 mg (Seretide Evohaler 125). The initial cultures from the blood, urine, and sputum were negative, and cefuroxime was stopped 1 week after admission. Investigation of anemia showed no active bleeding on physical examination and a negative stool occult blood test. The reticulocyte production index was 0.1. A blood smear and autoimmune profile showed no evidence of intravascular or extravascular hemolysis. Serum Vitamin B12, folate and iron levels were higher than normal (Vitamin B12 3876 pg/mL, normal range: 211–911 pg/mL; folate 44 ng/mL, normal range: >5.31 ng/mL; iron 196 µg/mL, normal range 65–175 µg/mL). The blood ferritin level was 6237.7 ng/mL (normal range 22–322 ng/mL), and total iron binding capacity was 204 µg/mL (normal range 250–450 µg/mL). The transferrin saturation (TSAT) was 96%. The blood lactate dehydrogenase level was 222 IU/mL. The patient refused a bone marrow biopsy. He had mildly elevated levels of serum aspartate transaminase (AST) 43 U/L, alkaline phosphatase (ALP) 163 IU/L and

gamma-glutamyltransferase (γGT) 326 IU/mL. The blood albumin level was 3 g/dL, and alanine transaminase (ALT) and direct-bilirubin levels were normal (40 U/L and 0.68 mg/dL, respectively). The B-and C-viral hepatitis profiles were negative. There was no evidence of occult malignancy with normal blood tumor marker levels. Abdominal sonography showed a tiny polyp o 3.4 mm in the gallbladder, but otherwise negative findings over the hepatobiliary system. No splenomegaly or portal vein congestion was found. To avoid further iron overload, a blood transfusion was given once on admission to keep the hemoglobin 7–8 g/dL.

In the following 3 weeks, the patient was treated for recurrent ventilator-associated pneumonia [Figure 1]. From day 8 to day 14, ceftazidime was given. Teicoplanin was given from day 20 to day 30 for pneumonia associated with oxacillin-resistant *Staphylococcus aureus* and a second red-blood-cell transfusion was given on day 21 for persistent fresh bloody sputum. On day 25, cefepime was given for a new fever (38.2°C) due to *Pseudomonas aeruginosa* pneumonia. On day 32, jaundice and tea-color urine were observed. There was no anorexia, vomiting, abdominal pain, or sore throat and the stool was dark brown. A physical examination showed the patient had a clear consciousness with icteric sclerae and pale conjunctivae. His blood pressure was 131/74 mmHg, t heart rhythm was regular at 80/min, and respiratory rate was 18/min under a mechanical ventilator fraction of inhaled oxygen of 35% and SpO<sub>2</sub> 96%. There were no signs of pharyngitis, neck lymphadenopathy, hepatosplenomegaly, skin rash, or petechiae. The laboratory study showed a normal hemogram (WBCs 8950/µL, segmented forms 60.5%, lymphocytes 28.3%,



**Figure 1:** Scheme of pharmacotherapy and bacterial culture results with liver enzyme abnormalities. The figure depicted all the medication used and dynamic change of blood liver tests. The duration, day of start and end of each medication was shown in X-axis. The value of serum total bilirubin was shown on the left Y-axis. The values of serum alkaline phosphatase and alanine transaminase shown on the right Y-axis

monocytes 9.6%, eosinophils 1.6%, Hb 7.9 g/dL, and platelets  $317 \times 10^3/\mu\text{L}$ ) and normal renal function. Liver biochemistry and function tests showed direct-type hyperbilirubinemia with a total bilirubin of 9.53 mg/dL, ALT 86 U/L, AST 104 U/L, ALP 515 U/L, and  $\gamma\text{GT}$  707 IU/L. Serum albumin, prothrombin time, and thyroid function tests were within the normal ranges. A second abdominal sonography still showed no abnormal findings in the hepatobiliary structures. DILI with cholestatic hepatitis was impressed. RUCAM scores for suspect drugs were 7 for cefepime, 6 for ceftazidime and 4 for teicoplanin [Supplement Table 1]. Cefepime was the most likely offending agent. It was discontinued on day 32 and ciprofloxacin 400 mg every 12 h intravenously and inhaled colistin 133.6 mg every 8 h were used according to drug susceptibility tests for *P. aeruginosa* pneumonia. Four days after discontinuing cefepime, the serum total- and direct-bilirubin levels decreased to 3.67 and 2.29 mg/dL, respectively. The total-bilirubin and ALT levels returned to the normal ranges on day 64 (1.04 mg/dL and 50 U/L, respectively). AST decreased to 56 U/L on day 64. The ALP level peaked at 523 IU/L 4 days after cefepime was discontinued and decreased to 490 IU/L on day 49. There was no further follow-up of ALP and  $\gamma\text{GT}$  after day 49. Treatment after day 32, including red-blood-cell transfusion and medications, did not cause liver biochemistry deterioration. Figure 1 shows the dynamic changes in liver blood tests including total-bilirubin, ALT, and ALP with all medications used during hospitalization. On day 43, the patient was successfully weaned off the ventilator and was discharged 1 month after extubation to a nursing home for further care.

## DISCUSSION

According to the manufacturer, cefepime-related hepatic side effects include increased serum ALT (3%), abnormal partial thromboplastin time (2%), increased serum AST (2%) and abnormal prothrombin time (1%) [12]. Hyperbilirubinemia and elevated serum ALP and  $\gamma\text{GT}$  due to cefepime have never been reported. The U. S. DILI network (DILIN) prospectively reviewed 1212 patients between 2004 and 2012. Nineteen of the 1019 DILI cases (2%), were attributed to cefazolin, which was the 6<sup>th</sup> most common agent identified in the study [14]. The characteristic presentation was a delayed cholestatic or mixed hepatocellular-cholestatic liver injury onset 1–3 weeks after a single intravenous injection of the antibiotics. Pruritis (100%) and jaundice (95%) were the most prominent symptoms or signs, and the course was self-limiting [14]. Fourteen cases of DILI were attributed to non-cefazolin cephalosporins in the study including one of cefepime. That patient had mixed hepatocellular and cholestatic liver injury 20 days after a 7-day course of cefepime. The serum total bilirubin was prominently elevated (11.3 mg/dl) with eventual complete recovery. The liver blood tests returned to baseline 90 days after the intravenous cefazolin injection [14]. Our patient was classified as having cholestatic DILI [13] with acute increasing serum total bilirubin levels which decreased 4 days after discontinuing cefepime, and returned to normal 32 days after, stopping the drug. Ceftazidime was another possible offending agent for DILI in our patient since its RUCAM score was only 1 point less than the score for cefepime and both drugs were

in the “probable” category in the DILI causality assessment. The main difference was that the observed liver insult occurred during cefepime use when ceftazidime had not been used for over 2 weeks. Although hyperbilirubinemia and increased liver enzymes were reported in ceftazidime postmarketing surveys, the elevations were transient and mild, and no clear incidence was ever reported [15]. Cephalosporin-induced liver injury resembles that associated with amoxicillin/clavulanic acid. The presentation included a delayed cholestatic or mixed liver injury with recovery after stopping the drugs [14,16]. An immunoallergic reaction to a structural component of the beta-lactam 4-ring molecule shared by both kinds of antibiotics was speculated to be the cause [14]. Our patient had taken amoxicillin/clavulanic acid and cefuroxime previously without liver injury. We were not sure if the cause was sensitization to beta-lactam antibiotics after repeated exposure or an idiosyncratic reaction to cefepime.

ALP and  $\gamma\text{GT}$  were slightly elevated in our patient on admission and did not return to normal during the whole hospitalization course. These, along with the elevated conjugated bilirubin level usually hint that the patient has hepatobiliary or infiltrative liver disease. The former was excluded by negative abdominal sonography. Some comorbidities in our patient which could result in chronic liver disease had to be considered before a diagnosis of DILI. These included congestive heart failure, chronic anemia of unknown etiology and iron overload related to chronic transfusion. The most common liver biochemistry abnormality in congestive hepatopathy is a mild elevation in the serum bilirubin level (usually <3 mg/dL) with predominant unconjugated forms. Striking hyperbilirubinemia may be found in patients with severe acute right-side heart failure [17]. Our patient did not have symptoms and signs of decompensated congestive heart failure when he developed conjugated form predominant hyperbilirubinemia. There was also no worsening of the lung condition such as hypoxia or acute exacerbation of COPD that might have resulted in right heart failure. Abdominal sonography showed that the inferior vena cava and hepatic veins were not dilated. The laboratory studies did not support findings of acute or chronic hemolysis in our patient. The former two diseases were not likely responsible for the patient’s acute liver injury. We suspected our patient had transfusional iron overload based on a history of blood transfusion >20 units, a high serum ferritin level and a TSAT >45% (96% in our patient). Confirmatory diagnosis of iron overload with liver involvement mandates a liver biopsy or liver magnetic resonance imaging, which were not done in our patient due to his critical status. Chronic or acute inflammation, chronic liver disease, and alcohol use may confound ferritin and TSAT measurements, but a low CRP level, initial normal liver enzymes, and clinical findings excluded these states. Iron overload probably caused the slightly increased ALP and  $\gamma\text{GT}$  levels in our patient, and this made the patient prone to acute liver injury.

Acute viral hepatitis is important in the differential diagnosis of DILI. Serology studies for hepatitis A, B, C, E virus, cytomegalovirus, Epstein-Barr virus, herpes simplex virus, and varicella zoster virus are required in RUCAM when assessing DILI [13]. In our patient, we only excluded hepatitis

B and C viral infection by serology test. We did not complete the study because the clinical presentations in our patient were not compatible with acute viral hepatitis. The patient had no symptomatic illness, which begins with an abrupt onset of nausea, vomiting, anorexia, fever, malaise, and abdominal pain. Laboratory findings in acute viral hepatitis usually include significant elevations of serum aminotransferases (often >1000 international units/dL) and mild to moderate degree of elevation in serum bilirubin (typically  $\leq 10$  mg/dL) and ALP (up to 400U/L) [18]. This is in contrast to the findings in our patient. Full clinical and biochemical recovery in acute viral hepatitis usually is observed within 2–6 months but our patient's serum bilirubin level declined in 1 week and was completely normal in 1 month, which was more compatible with a previous study of cefazolin-induced DILI [14]. Our patient also had no cervical lymphadenopathy, splenomegaly, absolute lymphocytosis, or atypical lymphocytes, which are suggestive of CMV and EBV infections [19]. Thus, an extensive viral hepatitis study seemed unnecessary.

Cholestatic DILI occurs in 20%–40% cases [5,20]. Mortality from DILI with jaundice due to antibiotics was reported in approximately 10% of patients and/or they needed liver transplantation [21,22]. Björnsson reviewed antibiotic-induced liver injury and some risk factors for the development of cholestatic DILI were identified [2]. These included old age, dose-dependent effect with administration of medications in dosages greater than 50 mg a day, drugs with 50% or greater hepatic metabolism, certain genetic traits (mainly polymorphism in human leukocyte antigen [HLA] class II) and chemical properties of the drugs (e.g., high lipophilicity associated with cholestatic liver injury) [2,20]. The clinical patterns from DILI patients include vanishing bile duct syndrome (VBDS), secondary sclerosing cholangitis, and acute and chronic cholestasis [20]. In a recent DILIN cohort, 26 of the 363 patients (7%) with drug, herbal or dietary supplement-associated liver injury had VBDS and were more likely to have chronic liver injury compared with those who did not have VBDS (94% vs. 47%;  $P < 0.001$ ) [23]. High liver-related mortality (26%) was found [23] compared with 6.2% mortality in the 899 DILI patients in the entire DILIN cohort. The need for liver transplantation was 8% in VBDS patients and 4% in the overall cohort [22].

Of note, the risks of cholestatic DILI and hepatic toxicity are higher in patients taking multiple medications because of their potential to cause DILI. We excluded the possibility of drug-drug interactions according to the Drug Interaction Probability Scale [24]. The patient was not rechallenged with cefepime, but his bilirubin level gradually recovered after stopping the drug. Thus, cefepime was considered the cause of cholestatic liver injury in our patient.

## CONCLUSION

Cholestatic DILI is a rare side effect of cefepime. However, clinicians should be aware of this adverse effect as this antibiotic is frequently prescribed. We suggest that clinicians carefully monitor hepatic parameters in patients treated with

high-dose cefepime or in those likely to receive a prolonged course of this antibiotic.

## Declaration of patient consent

The authors certify that the patient has obtained an appropriate patient consent form. In the form, the patient has given his consent for his images and other clinical information to be reported in the journal. The patient understands that his name and initials will not be published and due efforts will be made to conceal his identity, but anonymity cannot be guaranteed.

## Financial support and sponsorship

Nil.

## Conflicts of interest

There are no conflicts of interest.

## REFERENCES

1. Watkins PB. How to diagnose and exclude drug-induced liver injury. *Dig Dis* 2015;33:472-6.
2. Björnsson ES. Drug-induced liver injury due to antibiotics. *Scand J Gastroenterol* 2017;52:617-23.
3. Andrade RJ, Lucena MI, Fernández MC, Pelaez G, Pachkoria K, Garcia-Ruiz E, et al. Drug-induced liver injury: An analysis of 461 incidences submitted to the Spanish registry over a 10-year period. *Gastroenterology* 2005;129:512-21.
4. De Valle MB, Av Klinteberg V, Alem N, Olsson R, Björnsson E. Drug-induced liver injury in a Swedish university hospital out-patient hepatology clinic. *Aliment Pharmacol Ther* 2006;24:1187-95.
5. Björnsson ES, Bergmann OM, Björnsson HK, Kvaran RB, Olafsson S. Incidence, presentation, and outcomes in patients with drug-induced liver injury in the general population of Iceland. *Gastroenterology* 2013;144:1419-25, 1425.e1-3.
6. Ammann R, Neftel K, Hardmeier T, Reinhardt M. Cephalosporin-induced cholestatic jaundice. *Lancet* 1982;2:336-7.
7. Bilici A, Karaduman M, Cankir Z. A rare case of hepatitis associated with cefprozil therapy. *Scand J Infect Dis* 2007;39:190-2.
8. Longo F, Hastier P, Buckley MJ, Chichmanian RM, Delmont JP. Acute hepatitis, autoimmune hemolytic anemia, and erythroblastocytopenia induced by ceftriaxone. *Am J Gastroenterol* 1998;93:836-7.
9. Skoog SM, Smyrk TC, Talwalkar JA. Cephalixin-induced cholestatic hepatitis. *J Clin Gastroenterol* 2004;38:833.
10. Peker E, Cagan E, Dogan M. Ceftriaxone-induced toxic hepatitis. *World J Gastroenterol* 2009;15:2669-71.
11. Agrawal A, Rao M, Jasdawala S, Mathur A, Eng M. Cephalixin induced cholestatic jaundice. *Case Rep Gastrointest Med* 2014;2014:260743.
12. Product Information: MAXIPIME(R) IV, IM Injection, Cefepime HCl IV, IM Injection. Princeton, NJ: Bristol-Myers Squibb Company; 2009. Available from: <http://www.micromedexsolutions.com/>. [Last accessed on 2018 Jun].
13. Danan G, Teschke R. RUCAM in drug and herb induced liver injury: The update. *Int J Mol Sci* 2015;17. pii: E14.
14. Alqahtani SA, Kleiner DE, Ghabril M, Gu J, Hoofnagle JH, Rockey DC, et al. Identification and characterization of cefazolin-induced liver injury. *Clin Gastroenterol Hepatol* 2015;13:1328-3600.
15. Product Information: FORTAZ(R) Intravenous Intramuscular Injection, Cefazidime Intravenous Intramuscular Injection. (per FDA). Cary, NC: Covis Pharmaceuticals, Inc.; 2014. Available from: <http://www.micromedexsolutions.com/>. [Last accessed on 2018 Jun].
16. Lucena MI, Andrade RJ, Fernández MC, Pachkoria K, Pelaez G, Durán JA, et al. Determinants of the clinical expression of amoxicillin-clavulanate hepatotoxicity: A prospective series from Spain. *Hepatology* 2006;44:850-6.

17. Dunn GD, Hayes P, Breen KJ, Schenker S. The liver in congestive heart failure: A review. *Am J Med Sci* 1973;265:174-89.
18. Tong MJ, el-Farra NS, Grew MI. Clinical manifestations of hepatitis A: Recent experience in a community teaching hospital. *J Infect Dis* 1995;171 Suppl 1:S15-8.
19. Evans AS. Infectious mononucleosis and related syndromes. *Am J Med Sci* 1978;276:325-39.
20. Sundaram V, Björnsson ES. Drug-induced cholestasis. *Hepatol Commun* 2017;1:726-35.
21. Björnsson E, Olsson R. Outcome and prognostic markers in severe drug-induced liver disease. *Hepatology* 2005;42:481-9.
22. Chalasani N, Bonkovsky HL, Fontana R, Lee W, Stolz A, Talwalkar J, et al. Features and outcomes of 899 patients with drug-induced liver injury: The DILIN prospective study. *Gastroenterology* 2015;148:1340-52.e7.
23. Bonkovsky HL, Kleiner DE, Gu J, Odin JA, Russo MW, Navarro VM, et al. Clinical presentations and outcomes of bile duct loss caused by drugs and herbal and dietary supplements. *Hepatology* 2017;65:1267-77.
24. Horn JR, Hansten PD, Chan LN. Proposal for a new tool to evaluate drug interaction cases. *Ann Pharmacother* 2007;41:674-80.

