



## Case Report

# Early renal arterial rupture and arterial pseudoaneurysm in graft kidneys from the same deceased donor

Yu-Hua Lin<sup>a,b</sup>, Chun-Hou Liao<sup>a,c</sup>, Bing-Jun Jiang<sup>a</sup>, Tzu-Hung Chen<sup>d\*</sup>

<sup>a</sup>Division of Urology, Department of Surgery, Cardinal Tien Hospital, New Taipei, Taiwan, <sup>b</sup>Department of Urology, National Taiwan University Hospital, Taipei, Taiwan, <sup>c</sup>School of Medicine, Fu Jen Catholic University, New Taipei, Taiwan, <sup>d</sup>Department of General Surgery, Cardinal Tien Hospital, New Taipei, Taiwan

### ABSTRACT

Vascular complications are serious problems after kidney transplantation. An aneurysm or rupture in a graft artery is a rare but potentially devastating complication, which may lead to renal function impairment, graft loss, or even death. In this paper, we present two rare vascular complications in the early postoperative course after renal transplantation from the same deceased donor. In the first case, a 49-year-old woman who had spontaneous graft arterial rupture 13 days after kidney transplantation presented with sudden distension in the right lower abdomen. In the second case, a 56-year-old woman recipient with a graft renal arterial pseudoaneurysm presented with decreased urine output and deteriorating renal function 32 days after transplantation. Immediate surgical repair was performed, and fibrin sealant was applied to strengthen the fragile renal arterial wall. Although the function of both graft kidneys recovered well after surgery, the first graft kidney was removed 2 months later because of repeated fungal and bacterial infections. Aggressive surgical reconstruction may preserve graft kidneys in patients with vascular complications after kidney transplantation, but recovery of the graft condition remains a demanding challenge in renal transplantation.

**KEYWORDS:** Arterial repair, Arterial rupture, Graft nephrectomy, Pseudoaneurysm, Renal transplantation

Received : 15-Nov-2017  
Revised : 30-Nov-2017  
Accepted : 01-Dec-2017

## INTRODUCTION

Transplantation is a renal replacement therapy in patients with end-stage renal disease (ESRD). Arterial pseudoaneurysm or arterial rupture of the transplanted renal artery is an extremely rare but potentially devastating complication which occurs in fewer than 1% of patients [1]. They may cause functional impairment or death. We describe two patients who underwent renal transplantation from the same deceased multi-organ donor and both developed early vascular complications.

## CASE REPORTS

### Case 1

A 49-year-old woman with ESRD underwent a cadaveric renal transplant in our department. The kidney was transplanted with an end-to-side anastomosis of the transplant renal artery to the right external iliac artery. Her postoperative condition was uneventful, and the drainage tube was removed on postoperative day 10. However, sudden onset of the right lower abdominal pain occurred 14 days after the operation. Physical examination revealed a distended right lower abdomen without tenderness. There was no significant decrease in the hematocrit. Emergency abdominal computed tomography revealed a

large extraperitoneal perinephric renal hematoma. An emergency exploratory laparotomy showed a large number of fresh blood clots and a ruptured graft renal artery; a major 1 cm wide rupture was found at the middle part of the graft artery next to four more tiny leakage points. The arterial rupture was closed primarily with a 5-0 prolene suture, and fibrin sealant (TISSEEL®, Baxter AG, Vienna, Austria) was applied to strengthen the vascular wall after vessel repair.

Culture of the central venous catheter tip showed *Candida albicans*, and antifungal medication applied. A Doppler ultrasound revealed the graft renal vessels were patent with adequate perfusion of the graft kidney after surgical reconstruction. Renal function gradually recovered with adequate daily urine output 1 month after the operation. However, another episode of septic shock with right lower quadrant abdominal pain occurred 1 month later. An emergency exploratory


\*Address for correspondence:

Dr. Tzu-Hung Chen,  
Department of General Surgery, Cardinal Tien Hospital,  
362, Zhongzheng Road, New Taipei, Taiwan.  
E-mail: chentzuhung@gmail.com

This is an open access journal, and articles are distributed under the terms of the Creative Commons Attribution-NonCommercial-ShareAlike 4.0 License, which allows others to remix, tweak, and build upon the work non-commercially, as long as appropriate credit is given and the new creations are licensed under the identical terms.

For reprints contact: reprints@medknow.com

**How to cite this article:** Lin YH, Liao CH, Jiang BJ, Chen TH. Early renal arterial rupture and arterial pseudoaneurysm in graft kidneys from the same deceased donor. Tzu Chi Med J 2018;30(4):250-4.

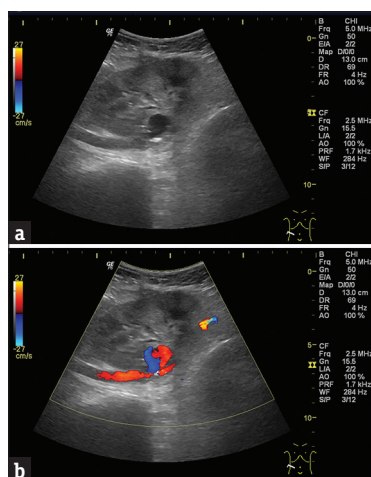
Access this article online	
<b>Quick Response Code:</b> 	<b>Website:</b> <a href="http://www.tcmjmed.com">www.tcmjmed.com</a>
	<b>DOI:</b> 10.4103/tcmj.tcmj_180_17

laparotomy showed massive pus-like fluid around the graft kidney with fungal and bacterial infection confirmed by culture. Necrotic tissue around the graft artery and external iliac artery was observed. A graft nephrectomy was done and the external iliac artery was repaired with a graft patch.

## Case 2

The second recipient was a 56-year-old woman with hypertension. The patient had a history of ESRD and had undergone hemodialysis for years. She also received renal transplantation on the same day as Case 1 with similar procedures. She had good graft function and was discharged early. However, decreased urine output and bilateral lower leg edema were noted 32 days after the operation. Compromised renal function was observed. Renal ultrasonography showed a 3 cm hypoechoic mass with a centrally anechoic lesion around the graft renal artery [Figure 1a]. Color-coded Doppler sonography revealed pulsatile flow within the central anechoic part of the lesion [Figure 1b]. The possible diagnosis was a pseudoaneurysm, which partially thrombosed the true lumen of the graft renal artery. Subsequent noncontrast magnetic resonance imaging confirmed a 3 cm × 3 cm false aneurysm near the anastomosis of the transplanted renal artery [Figure 2]. Surgical exploration showed an aneurysmal mass along the anastomosis site near the external iliac artery. Scrupulous dissection isolated the false aneurysm from the transplanted kidney. Vascular control was obtained, and resection of the false aneurysm was then performed. Vascular repair was performed with a primary anastomosis at the external iliac artery and transplanted renal artery using a continuous 5-0 nonabsorbable suture (polypropylene). Fibrin sealant was also applied to the reanastomosis site to prevent vascular leakage.

Histopathology of the resected pseudoaneurysm wall showed consistent marked fibrosis and fragmentation of elastic fibers. *C. albicans* was cultured from the drainage fluid. The patient was continued on immunosuppressive therapy and antifungal medication and was discharged home under stationary condition.

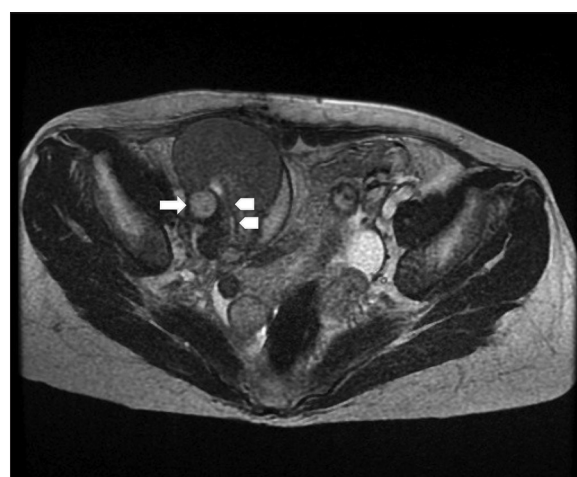

**Figure 1:** (a and b) Demonstrate a hypoechoic lesion with a central anechoic lesion near the transplanted renal artery. A pulsatile flow pattern was seen on color-coded Doppler sonography within the central anechoic part of the lesion

## DISCUSSION

Vascular complications are rare in renal transplantation patients but are significant causes of allograft loss. We conducted a comprehensive search to identify all relevant studies of extrarenal vascular pseudoaneurysm or arterial rupture in the MEDLINE (1950 – November 4, 2016) and EMBASE (1970 – November 4, 2016) databases. A total of 45 case reports or case series that met the inclusion criteria were reviewed [Table 1]. According to our literature review, the mortality rate was 13.8%. A major proportion (56.3%) of reported cases lost the graft kidney without mortality. Among the 87 patients, 73 (83.9%) experienced vascular complications at the anastomosis site. The majority of included patients (79.3%) were diagnosed with pseudoaneurysm, and 18 out of 87 patients (20.7%) had an arterial rupture. Only 33 patients (37.9%) had no infective pathogens. *C. albicans* (24 cases) was the leading pathogen in cases with infection. In our 2 cases, pseudoaneurysm occurred around the anastomosis site, while the ruptured site was at the middle portion of the graft artery in case 1, which is less common arterial than at other sites [Table 1].

Patients with pseudoaneurysms after renal transplant are often asymptomatic and diagnosed incidentally [20,23]. Detecting infective pseudoaneurysm in the early course and starting immediate surgical treatment with antifungal medications are essential. *Candida* arteritis-related pseudoaneurysm or ruptures may progress rapidly in the early stage after transplantation [11,35,37,40]. This finding is different from that of those with chronic rejection-related transplant arterial pseudoaneurysm, which may be associated with a delayed course and relatively slow progression [40]. One report suggested that 2-week preemptive prophylaxis with antifungal agents can effectively prevent delayed vascular complications in patients with donation-after-cardiac-death kidney transplantation complicated by fungal infection-related hemorrhage [46]. Elimination of *C. albicans* is required to prevent possible arterial complications.



**Figure 2:** Noncontrast T2-weighted magnetic resonance imaging reveals a pseudoaneurysm (white arrow) with compression of the true lumen of the transplanted renal artery (white arrowhead), causing poor flow in the transplanted kidney

**Table 1: Extrarenal vascular pseudoaneurysm and arterial rupture following renal transplantation in the literature**

Number	Author	Year	Aneurysm site	Infection	Interval after transplant	Number/intervention	Outcome
1	Kyriakides <i>et al.</i> [2]	1976	5/AS 3/AS (ruptured)	4/ <i>E. coli</i> 2/ <i>C. albicans</i> 2/ <i>Pseudomonas</i> spp.	1.5-6 months	8/Tx 1/SR	2/death 6/graft loss
2	Renigers and Spigos[3]	1978	1/AS	1/none	28 days	1/Tx	1/graft loss
3	Benoit <i>et al.</i> [4]	1988	1/AS	1/none	6 months	1/Tx	1/graft loss
4	Koo <i>et al.</i> [5]	1999	3/AS	1/ <i>S. aureus</i> (MRSA) 2/none	2-3 months	1/endovascular coil embolization 1/Tx 1/OBS	1/graft loss 2/graft preserved
5	Battaglia <i>et al.</i> [6]	2000	1/AS (ruptured) 1/AS	2/ <i>C. albicans</i>	17 days-3 months	2/Tx	2/graft loss
6	Reus <i>et al.</i> [7]	2002	1/AS	1/none	2 months	1/thrombin injection	1/graft loss (before procedure)
7	Garrido <i>et al.</i> [8]	2003	1/AS 1/EIA	2/ <i>Aspergillus</i> spp.	1.5-4 months	2/Tx	1/Sudden death 1/graft loss
8	Peel <i>et al.</i> [9]	2003	1/EIA	1/ <i>C. albicans</i>	1 month	1/SR + EVS	1/graft preserved
9	Taghavi <i>et al.</i> [10]	2005	1/AS	1/none	72 months	1/SR	1/graft preserved
10	Laouad <i>et al.</i> [11]	2005	4/AS	4/ <i>C. albicans</i>	9 days-3 months	4/Tx	3/graft loss 1/Sudden death
11	Zavos <i>et al.</i> [12]	2005	1/AS 1/AS (ruptured)	2/none	5 months	2/EVS	2/graft loss
12	Fujikata <i>et al.</i> [13]	2006	1/AS	1/ <i>S. aureus</i> (MRSA)	1.3 months	1/OBS	1/graft preserved
13	Fujita <i>et al.</i> [14]	2006	1/AS (ruptured)	1/none	5 months	1/EVS	1/graft preserved
14	Nguan and Luke[15]	2006	1/AS	1/ <i>S. aureus</i>	-	1/Tx	1/graft loss
15	Siu <i>et al.</i> [16]	2006	1/AS	1/none	3 months	1/EVS + thrombin injection	1/graft preserved
16	Fornaro <i>et al.</i> [17]	2007	1/IA	1/none	15 months	1/thrombin injection	1/graft preserved
17	Poels and Riley[18]	2007	1/IA	1/ <i>Pseudomonas</i> spp.	1.7 months	1/EVS + thrombin injection	1/graft preserved
18	Gravante <i>et al.</i> [19]	2008	1/AS	1/none	6 months	1/SR	1/graft preserved
19	Orlić <i>et al.</i> [20]	2008	1/AS	1/none	2.5 months	1/Tx	1/graft loss
20	Bracale <i>et al.</i> [21,22]	2009	5/AS 1/AS (ruptured) 6/EIA	2/ <i>C. albicans</i> 1/ <i>E. coli</i> 9/none	13 days-49 months	8/Tx 3/EVS + Tx 1/SR + replantation	8/graft loss 3/death after OP 1/graft preserved
21	Liu <i>et al.</i> [23]	2009	1/AS	1/ <i>Aspergillus</i> spp.	12 months	1/Tx	1/graft loss
22	Orlando <i>et al.</i> [24]	2009	2/AS (ruptured)	2/ <i>Pseudomonas</i> spp.	11 days-21 days	2/Tx	2/death
23	Osmán <i>et al.</i> [25]	2009	1/AS	1/ <i>C. albicans</i>	1.2 months	1/EVS + Tx	1/graft loss
24	Sharron <i>et al.</i> [26]	2009	1/AS	1/none	3 months	1/thrombin injection + SR	1/graft preserved
25	Wang <i>et al.</i> [27]	2009	2/AS (ruptured) 2/AS	4/ <i>Aspergillus</i> spp.	10 days-1.5 months	4/Tx	4/graft loss
26	Al-Wahaibi <i>et al.</i> [28]	2010	1/AS	1/none	4 months	1/SR	1/graft preserved
27	Akgul <i>et al.</i> [29]	2011	1/AS	1/none	14 years	1/endovascular treatment with coil	1/graft preserved
28	Lee <i>et al.</i> [30]	2011	1/AS	1/ <i>C. albicans</i>	2 months	1/Tx	1/graft loss
29	Minz <i>et al.</i> [31]	2011	2/AS	2/ <i>Aspergillus</i> spp.	1-5 months	2/Tx	1/death 1/graft loss
30	Buimer <i>et al.</i> [32]	2012	1/AS	1/ <i>E. coli</i>	14 months	1/SR	1/graft preserved
31	Favelier <i>et al.</i> [33]	2012	1/AS	1/none	36 months	1/endovascular coil insertion and stenting	1/graft preserved
32	Kountidou <i>et al.</i> [34]	2012	1/AS	1/ <i>C. albicans</i>	3 months	1/SR	1/graft preserved
33	Leonardou <i>et al.</i> [35]	2012	2/TRA 2/AS	2/ <i>Pseudomonas</i> spp. 1/ <i>K. pneumonia</i> 1/ <i>C. albicans</i>	3-15 months	4/EVS + Tx	4/graft loss
34	Smeds <i>et al.</i> [36]	2013	1/AS	1/none	72 months	1/EVS	1/graft preserved

Contd...

**Table 1: Contd...**

Number	Author	Year	Aneurysm site	Infection	Interval after transplant	Number/intervention	Outcome
35	Santangelo <i>et al.</i> [37]	2013	6/AS	2/ <i>C. albicans</i> 4/none	1.5-10 months	1/SR + replantation 4/Tx 1/EVS +Tx	1/graft preserved 5/graft loss
36	Chandak <i>et al.</i> [38]	2014	1/ TRA (ruptured)	1/ <i>Pseudomonas</i> spp.	10 days	1/SR	1/graft preserved
37	Che <i>et al.</i> [39]	2014	1/EIA	1/ <i>E. coli</i>	4 months	1/EVS	1/graft preserved
38	Dębska-Ślizień <i>et al.</i> [40]	2015	2/AS (ruptured)	2/ <i>C. albicans</i>	10 days-1 month	2/Tx	2/death after OP
39	Madhav <i>et al.</i> [41]	2015	1/AS	1/ <i>C. albicans</i>	25 days	1/SR	1/graft preserved
40	Patil <i>et al.</i> [42]	2015	1/AS	1/ <i>E. coli</i>	21 days	1/EVS	1/graft preserved
41	Patrono <i>et al.</i> [43]	2015	2/AS (ruptured) 1/AS	2/ <i>C. albicans</i> 1/ <i>Pseudomonas</i> spp.	12 days-25 days	2/Tx 1/SR	2/graft loss 1/graft preserved
42	Tshomba <i>et al.</i> [44]	2015	1/AS	1/none	9 months	1/EVS	1/graft preserved
43	Ardita <i>et al.</i> [45]	2015	1/AS	1/none	20 days	1/SR	1/graft preserved
44	Zhao <i>et al.</i> [46]	2016	2/AS (ruptured)	2/ <i>C. albicans</i>	14-21 days	2/EVS + Tx	2/graft loss
	Summary		AS: 73 (17 ruptured) EIA: 9 (0 ruptured) IA: 2 (0 ruptured) TRA: 3 (1 ruptured)	None: 33 <i>C. albicans</i> : 24 <i>Aspergillus</i> spp.: 9 <i>Pseudomonas</i> spp.: 9 <i>E. coli</i> : 8 <i>S. aureus</i> : 3 (with 2 MRSA) <i>K. pneumoniae</i> : 1			Graft preserved: 26 Graft loss: 49 Death: 12

AS: Anastomosis site, EIA: External iliac artery, TRA: Transplant renal artery, IA: Iliac artery, Tx: Transplantectomy, SR: Surgical repair, EVS: Endovascular stenting; OBS: Observation, *E. coli*: *Escherichia coli*, *C. albicans*: *Candida albicans*, *S. aureus*: *Staphylococcus aureus*, MRSA: Methicillin-resistant *S. aureus*, *K. pneumoniae*: *Klebsiella pneumoniae*

Surgical repair to preserve a transplanted kidney is not usually successful in vascular complications [37]. We applied fibrin sealant for anastomosis, which seemed sufficient for control after surgical suturing for realignment of the vascular wall. No evident leakage was observed through daily drainage monitoring in both case 1 and case 2. This study is also the first to report successful use of fibrin sealant in securing injured transplant vessels.

## CONCLUSION

The development of an extrarenal pseudoaneurysm or arterial rupture in a transplant renal artery is extremely rare. It can cause a potentially devastating allograft loss and may require allograft nephrectomy. For those with suspected vascular complications, early clinical diagnosis and aggressive surgical intervention are necessary to achieve better allograft outcome and patient survival.

## Declaration of patient consent

The authors certify that all patients have obtained appropriate patient consent forms. In the form, the patients have given their consent for their images and other clinical information to be reported in the journal. The patients understand that their names will not be published and due efforts will be made to conceal their identity, but anonymity cannot be guaranteed.

## Financial support and sponsorship

Nil.

## Conflicts of interest

There are no conflicts of interest.

## REFERENCES

- Dimitroulis D, Bokos J, Zavos G, Nikiteas N, Karidis NP, Katsaronis P, et al. Vascular complications in renal transplantation: A single-center experience in 1367 renal transplantations and review of the literature. *Transplant Proc* 2009;41:1609-14.
- Kyriakides GK, Simmons RL, Najarian JS. Mycotic aneurysms in transplant patients. *Arch Surg* 1976;111:472-6.
- Renigers SA, Spigos DG. Pseudoaneurysm of the arterial anastomosis in a renal transplant. *AJR Am J Roentgenol* 1978;131:525-6.
- Benoit G, Icard P, Lebaleur A, Charpentier B, Jardin A, Friesg D. Mycotic aneurysm and renal transplantation. *Urology* 1988;31:63-5.
- Koo CK, Rodger S, Baxter GM. Extra-renal pseudoaneurysm: An uncommon complication following renal transplantation. *Clin Radiol* 1999;54:755-8.
- Battaglia M, Dittono P, Fiore T, De Ceglie G, Regina G, Selvaggi FP, et al. True mycotic arteritis by *Candida albicans* in 2 kidney transplant recipients from the same donor. *J Urol* 2000;163:1236-7.
- Reus M, Morales D, Vázquez V, Llorente S, Alonso J. Ultrasound-guided percutaneous thrombin injection for treatment of extrarenal pseudoaneurysm after renal transplantation. *Transplantation* 2002;74:882-4.
- Garrido J, Lerma JL, Heras M, Labrador PJ, Garcia P, Bondía A, et al. Pseudoaneurysm of the iliac artery secondary to *Aspergillus* infection in two recipients of kidney transplants from the same donor. *Am J Kidney Dis* 2003;41:488-92.
- Peel RK, Patel J, Woodrow G. Iliac artery false aneurysm following renal allograft: Presentation with non-specific inflammatory response and treatment by endovascular stent graft. *Nephrol Dial Transplant* 2003;18:1939-40.
- Taghavi M, Shojae Fard A, Mehrai R, Shadman M. Late onset anastomotic pseudoaneurysm of renal allograft artery: Case report, diagnosis, and treatment. *Transplant Proc* 2005;37:4297-9.



11. Laouad I, Buchler M, Noel C, Sadek T, Maazouz H, Westeel PF, et al. Renal artery aneurysm secondary to *Candida albicans* in four kidney allograft recipients. *Transplant Proc* 2005;37:2834-6.
12. Zavos G, Pappas P, Kakisis JD, Leonardou P, Manoli E, Bokos J, et al. Endovascular repair as first-choice treatment of iliac pseudoaneurysms following renal transplantation. *Transplant Proc* 2005;37:4300-2.
13. Fujikata S, Tanji N, Iseda T, Ohoka H, Yokoyama M. Mycotic aneurysm of the renal transplant artery. *Int J Urol* 2006;13:820-3.
14. Fujita S, Fujikawa T, Mekeel KL, Foley DP, Kim RD, Howard RJ, et al. Successful endovascular treatment of a leaking pseudoaneurysm without graft loss after simultaneous pancreas and kidney transplantation. *Transplantation* 2006;82:717-8.
15. Nguan CY, Luke PP. Renal artery pseudoaneurysm of infectious etiology: A life-threatening complication after renal transplantation. *Urology* 2006;68:668-9.
16. Siu YP, Tong MK, Leung KT, Kwan TH, Au TC, Cheung YK, et al. Renal artery pseudoaneurysm following renal transplantation and treatment by percutaneous thrombin injection. *Hong Kong Med J* 2006;12:80-1.
17. Fornaro J, Marinček B, Jungius KP. Pseudoaneurysm in the iliac fossa after renal transplantation – treatment with ultrasound-guided thrombin injection. *Abdom Imaging* 2007;32:50-2.
18. Poels JA, Riley PL. Extrarenal transplant artery pseudoaneurysm: A combined therapeutic approach. *Cardiovasc Intervent Radiol* 2008;31:404-6.
19. Gravante G, Pisani F, D'Angelo M, Iaria G, Orlando G. Renal artery aneurysms in kidney grafts. *Am J Surg* 2008;196:e46-7.
20. Orlić P, Vukas D, Curuvija D, Markić D, Merlak-Prodan Z, Maleta I, et al. Pseudoaneurysm after renal transplantation. *Acta Med Croatica* 2008;62(Suppl 1):86-9.
21. Bracale UM, Carbone F, del Guercio L, Viola D, D'Armiento FP, Maurea S, et al. External iliac artery pseudoaneurysm complicating renal transplantation. *Interact Cardiovasc Thorac Surg* 2009;8:654-60.
22. Bracale UM, Santangelo M, Carbone F, Del Guercio L, Maurea S, Porcellini M, et al. Anastomotic pseudoaneurysm complicating renal transplantation: Treatment options. *Eur J Vasc Endovasc Surg* 2010;39:565-8.
23. Liu KY, Tsai PJ, King KL, Chen TH, Shyr YM, Su CH, et al. Pseudoaneurysm of the iliac artery secondary to *Aspergillus* infection after kidney transplantation. *J Chin Med Assoc* 2009;72:654-6.
24. Orlando G, Di Cocco P, Gravante G, D'Angelo M, Famulari A, Pisani F, et al. Fatal hemorrhage in two renal graft recipients with multi-drug resistant *Pseudomonas aeruginosa* infection. *Transpl Infect Dis* 2009;11:442-7.
25. Osmán I, Barrero R, León E, Medina R, Torrubia F. Mycotic pseudoaneurysm following a kidney transplant: A case report and review of the literature. *Pediatr Transplant* 2009;13:615-9.
26. Sharron JA, Esterl RM, Washburn WK, Abrahamian GA. Surgical treatment of an extrarenal pseudoaneurysm after kidney transplantation. *Vasc Endovascular Surg* 2009;43:317-21.
27. Wang R, Wu J, Wang Y, Huang H, He Q, Chen J, et al. *Aspergillus* infection limited to the anastomosed artery following renal transplantation: A report of 4 cases. *Transpl Infect Dis* 2009;11:363-6.
28. Al-Wahaibi KN, Aquil S, Al-Sukaiti R, Al-Riyami D, Al-Busaidi Q. Transplant renal artery false aneurysm: Case report and literature review. *Oman Med J* 2010;25:306-10.
29. Akgul E, Binokay F, Aikimbaev K, Aksungur EH. Extrarenal pseudoaneurysm of the arterial anastomosis in a renal transplant: Endovascular coil embolization with balloon remodeling technique. *Ren Fail* 2011;33:452-5.
30. Lee CH, Kao YC, Chan WP. Pseudoaneurysm with candidal infection after renal transplantation. *Intern Med* 2011;50:2679-80.
31. Minz M, Sharma A, Kumar S, Singh S, Shivaprakash MR, Bag S, et al. Use of autogenous internal iliac artery for bridging the external iliac artery after excision of *Aspergillus* mycotic aneurysm in renal transplant recipients. *J Vasc Surg* 2011;53:802-4.
32. Buimer MG, van Hamersvelt HW, Adam van der Vliet J. Anastomotic pseudoaneurysm after renal transplantation; a new hybrid approach with graft salvage. *Transpl Int* 2012;25:e86-8.
33. Favelier S, Kretz B, Tanter Y, Loffroy R. Stent-assisted detachable coil embolization of a late-onset wide-necked anastomotic renal allograft artery pseudoaneurysm. *J Vasc Surg* 2012;56:1131.
34. Kountidou CS, Stier K, Niehues SM, Lingnau A, Schostak M, Fuller TF, et al. Successful repair of post-transplant mycotic aneurysm of iliac artery with renal graft preservation: A case report. *Urology* 2012;80:1151-3.
35. Leonardou P, Gioldasi S, Zavos G, Pappas P. Mycotic pseudoaneurysms complicating renal transplantation: A case series and review of literature. *J Med Case Rep* 2012;6:59.
36. Smeds MR, Ofstein R, Peterson GJ, Peterson BG, Jacobs DL. Endovascular repair of a para-anastomotic pseudoaneurysm after renal autotransplantation: An alternative to open reconstruction. *Ann Vasc Surg* 2013;27:110.e5-8.
37. Santangelo ML, Bracale UM, Carlomagno N, De Rosa D, Spiezia S, Scotti A, et al. Kidney transplantation and large anastomotic pseudoaneurysm. Transplant management considerations. *Ann Ital Chir* 2013;84:275-9.
38. Chandak P, Kessar N, Uwechue RU, Abboudi H, Hossain M, Harris F, et al. Successful excision of a suspected mycotic transplant renal artery patch aneurysm with renal allograft autotransplantation. *Transplantation* 2014;97:e25-6.
39. Che H, Men C, Yang M, Zhang J, Chen P, Yong J, et al. Endovascular repair of a transplant renal artery anastomotic pseudoaneurysm using the snorkel technique. *J Vasc Surg* 2014;60:1052-5.
40. Dębska-Ślizięń A, Chrobak Ł, Bzoma B, Perkowska A, Zadrozny D, Chamienia A, et al. *Candida* arteritis in kidney transplant recipients: Case report and review of the literature. *Transpl Infect Dis* 2015;17:449-55.
41. Madhav D, Kumar P, Mohan C, Vijay, Mahesh U, Anusha. et al. *Candida*-associated pseudo-aneurysm of the transplant renal artery presenting as malignant hypertension and managed successfully without nephrectomy. *Saudi J Kidney Dis Transpl* 2015;26:1000-5.
42. Patil VV, Roytman M, Ames S, Beckerman W, Lookstein RA. Endovascular repair of renal artery anastomotic pseudoaneurysm following living donor kidney transplant. *Cardiovasc Intervent Radiol* 2015;38:1640-4.
43. Patrono D, Verhelst R, Buemi A, Darius T, Godefroid N, Mourad M, et al. Presentation and management of mycotic pseudoaneurysm after kidney transplantation. *Transpl Infect Dis* 2015;17:129-36.
44. Tshomba Y, Apruzzi L, Kahlberg A, Baccellieri D, Vitale R, Chiesa R, et al. Endovascular repair of delayed giant iliac pseudoaneurysm following simultaneous pancreas-kidney transplantation with preserved allografts function. *J Cardiovasc Surg (Torino)*. 2015. pii: R37Y9999N00A150083.
45. Ardita V, Veroux M, Zerbo D, D'Arrigo G, Caglià P, Veroux P, et al. Non-mycotic anastomotic pseudoaneurysm of renal allograft artery. Case report. *Ann Ital Chir* 2016;87. pii: S2239253X16025081.
46. Zhao DD, Huang ZY, Hong LQ, Liao T, Tang YE, Na N, et al. Massive hemorrhage caused by fungal infections after donation-after-cardiac-death kidney transplantation: Clinical features, prevention and treatment experience. *Zhonghua Yi Xue Za Zhi* 2016;96:1570-2.