



## Original Article

# Superficial temporal artery-middle cerebral artery bypass for the treatment of complex middle cerebral artery aneurysms

Chien-Hui Lee, Sheng-Tzung Tsai, Tsung-Lang Chiu\*

Department of Neurosurgery,  
Buddhist Tzu Chi General  
Hospital and Tzu Chi University,  
Hualien, Taiwan

### ABSTRACT

**Objectives:** Direct microsurgical clipping for complex middle cerebral artery (MCA) aneurysms may require a long ischemic time. Sacrifice of the parent artery with trapping or endovascular coiling also may lead to ischemic stroke. We described our institutional experience with the treatment of complex MCA aneurysms using extracranial-intracranial (EC-IC) (superficial temporal artery [STA]-MCA) bypass. **Materials and Methods:** We retrospectively reviewed patients who had treatment of IC aneurysms with the assistance of STA-MCA bypass from July 2002 to December 2016. Six patients with complex MCA aneurysms were identified, and we reviewed their clinical characteristics. **Results:** There were three men and three women with age ranging from 27 to 59 (mean 49) years old. Image studies showed subarachnoid hemorrhage in three cases. All patients underwent STA-MCA anastomosis, and the follow-up period ranged from 2 to 116 months (mean 51.5 months). Two of the six MCA aneurysms were fusiform, two aneurysms had bizarre configurations, one was a dissecting saccular aneurysm, and one had a blister configuration. Three patients received direct vessel trapping, two patients received aneurysm clipping, and one received aneurysm coiling. The postoperative bypass patency rate was 100%. The modified Rankin scale showed good outcomes in the six patients. **Conclusions:** EC-IC bypass plays an important role as a salvage procedure in the treatment of complex MCA aneurysms which have a fusiform, bizarre, or blister configuration.

**KEYWORDS:** *Aneurysm, Bypass, Extracranial-intracranial, Middle cerebral artery, Superficial temporal artery-middle cerebral artery*

Received : 10-Jul-2017  
Revised : 22-Sep-2017  
Accepted : 02-Oct-2017

## INTRODUCTION

Complex middle cerebral artery (MCA) aneurysms include fusiform morphology (no identified aneurysmal neck), intraluminal thrombi, atherosclerotic tissue in the neck, major arterial branches incorporated into the aneurysm base, or a broad neck [1,2]. These features may pose a great challenge in standard microscopic clipping or endovascular coil embolization.

The MCA is the largest cerebral artery and it supplies most of eloquent brain cortex, nearly all the basal ganglia, and the posterior and anterior internal capsules. Direct vessel trapping or endovascular occlusion of the parent MCA to obliterate an aneurysm carries a high risk of ischemic stroke, which can lead to diverse neurological damage [3]. Direct microscopic aneurysm clipping of a complex aneurysm sometimes has a high complication rate of postoperative infarction because the procedure requires a prolonged ischemic time. Therefore, preventing postoperative infarction is a big challenge.

Extracranial-intracranial (EC-IC) bypass is a revascularization procedure in the cerebral arteries through the EC arteries.

The bypass procedure was initially designed to prevent recurrent cerebral ischemic stroke, and a superficial temporal artery (STA)-MCA bypass is one of the most commonly used types. Our series showed that an STA-MCA bypass can reduce the risk of MCA ischemic stroke through blood flow replacement and augmentation [4].

When conventional surgical clipping or endovascular coiling for MCA and internal carotid artery (ICA) aneurysms is not feasible, aneurysm treatment may be achieved by sacrifice of the parent cerebral artery with a bypass. Cerebral revascularization includes high flow and low flow methods, and one study showed that low flow bypass leads to a lower risk of intraoperative ischemic stroke [5]. Whether low flow bypass provides adequate cerebral perfusion after MCA parent artery


### \*Address for correspondence:

Dr. Tsung-Lang Chiu,  
Department of Neurosurgery, Buddhist Tzu Chi General Hospital, 707,  
Section 3, Chung-Yang Road, Hualien, Taiwan.  
E-mail: poluschou@gmail.com

This is an open access journal, and articles are distributed under the terms of the Creative Commons Attribution-NonCommercial-ShareAlike 4.0 License, which allows others to remix, tweak, and build upon the work non-commercially, as long as appropriate credit is given and the new creations are licensed under the identical terms.

For reprints contact: [reprints@medknow.com](mailto:reprints@medknow.com)

**How to cite this article:** Lee CH, Tsai ST, Chiu TL. Superficial temporal artery-middle cerebral artery bypass for the treatment of complex middle cerebral artery aneurysms. *Tzu Chi Med J* 2018;30(2):110-5.

Access this article online	
Quick Response Code: 	Website: <a href="http://www.tcmjmed.com">www.tcmjmed.com</a>
	DOI: 10.4103/tcmj.tcmj_193_17

trapping or occlusion is still debated. We present experience at a single institution in using bypass techniques for patients with complex MCA aneurysms and discuss the characteristics of complex MCA aneurysms and the efficacy of the STA-MCA bypass for these patients.

## MATERIALS AND METHODS

We retrospectively reviewed our medical records and imaging from July 2002 to December 2016. Among 369 patients with aneurysms treated with microsurgical clipping or endovascular coiling, six complex MCA aneurysm cases were treated with aneurysm clipping or coiling with assistance of a STA-MCA (EC-IC) bypass. The study was conducted in accordance with the Declaration of Helsinki. Informed written consent was waived because the study was a retrospective data analysis. This study has been approved by the research ethics committee of Hualien Tzu Chi Hospital, Buddhist Tzu Chi Medical Foundation (IRB107-27-B).

### Preoperative survey

Cerebral computed tomographic (CT) angiography and cerebral digital subtraction angiography (DSA) were done routinely when brain CT revealed spontaneous subarachnoid hemorrhage (SAH). One of the three ruptured aneurysms was Hunt and Hess (H&H) Grade 4, one was Grade 3, and one was Grade 1. The Fisher grades of these cases are shown in Table 1. One aneurysm was located at the MCA bifurcation and five in the M2 segment. The aneurysms ranged from 3 to 20.2 mm.

### Bypass surgery strategy for aneurysms

Initially, a balloon occlusion test was performed before bypass surgery in our hospital. This test took 30 min. If transient ischemic symptoms such as limb weakness or consciousness deterioration were noted, the test was positive. When the test was negative, cerebral artery sacrifice without

bypass was indicated. Currently, EC-IC bypass is performed before a balloon occlusion test to decrease the false-negative rate when a cerebral aneurysm with complex anatomy is noted. Following bypass, a balloon occlusion test was done to simulate cerebral artery sacrifice. If the patient did not pass the test, another bypass surgery and revascularization were done before complex aneurysm surgery. If the patient passed the test, aneurysm surgery was done immediately.

### Postoperative evaluation

Cerebral DSA was routinely done after the operation to check bypass patency and obliteration status. Modified Rankin scales were used to demonstrate the clinical outcome evaluation [Table 2] in our study patients. In addition, the Hirai system for the type of reestablished vasculature was used to evaluate patency and function [6].

### Surgical procedures

All bypasses were done by end-to-side anastomosis of the STA to the MCA (frontal and temporal M3 branches of the MCA). The details of the surgical procedures have been described previously [7]. A 5-cm length of the frontal branch of the STA was dissected. We used 1% diluted heparin solution to irrigate the endovascular lumen to prevent thrombus formation. Then, a 3 cm × 2 cm craniotomy was created, and the Sylvian fissure was exposed to identify the M3 branch of the MCA for anastomosis. The recipient vessel was trapped with two temporary clips placed 1 cm apart. A 6-mm longitudinal incision was made in the recipient vessel, and the incision was also irrigated with 1% diluted heparin solution. The stump of the donor vessel was shaved obliquely to 6 mm in length to accommodate the opening in the recipient side. An anastomosis was created using 10-0 nylon sutures originating at the proximal and distal ends of the orifices. Eight interrupted sutures were made on each side for a total of 16 sutures. The patency of the anastomosis was validated during surgery

**Table 1: Clinical characteristics of patients and aneurysms**

Cases	Age (years)/sex	Preoperative GCS	Presenting symptoms	Location	Aneurysm morphology	Size (mm)	Fisher grade	H&H grade	Preaneurysm treatment
1	27/male	E3V2M5	Sudden aphasia	Left MCA M2	Bizarre	6.8	3	3	EVD
2	58/female	E4V5M6	TIA-like symptoms	Left MCA M2	Saccular	15.7	No SAH	1	None
3	51/female	E1VTM1	Deep coma	Left MCA bifurcation	Bizarre	3.5	3	4	EVD
4	57/male	E4V5M6	Incidental finding	Right MCA M2	Fusiform	20.2	No SAH	1	None
5	42/female	E4V5M6	Headache	Left MCA M2	Fusiform	6.3	No SAH	1	None
6	59/male	E4V5M6	Headache	Right MCA M2	Blister	3	1	1	None

GCS: Glasgow coma scale, H&H: Hunt and Hess, MCA: Middle carotid artery, EVD: External ventricular drainage, TIA: Transient ischemic attack, SAH: Subarachnoid hemorrhage

**Table 2: Treatment outcomes of aneurysm surgery**

Case	Aneurysm treatment	Bypass type	Ischemic time	Bypass patent	Postoperative GCS	Preoperative mRS	Postoperative mRS	Hirai type
1	Trapping	STA-MCA	None	+	E4V3M6	4	1	Mild
2	GDC	STA-MCA	None	+	E4V5M6	1	0	Moderate
3	Clipping	STA-MCA*2	160 s	+	E4V5M6	5	1	Mild
4	Trapping	STA-MCA*2	None	+	E4V5M6	0	0	Mild
5	Trapping	STA-MCA*2	None	+	E4V5M6	1	1	Moderate
6	Clipping	STA-MCA*2	60 s	+	E4V5M6	1	1	Mild

STA-MCA\*2: Two bypass anastomosis of STA-MCA, +: Patent anastomosis confirmed by angiography, STA-MCA: Superficial temporal artery-middle cerebral artery, GCS: Glasgow Coma Scale, GDC: Guglielmi detachable coiling, mRS: Modified Rankin scale, Hirai type: Extent of reestablished vasculature

by a transcranial Doppler test (DWL Multi Dop X4; Singen, Baden-Württemberg, Germany) using a 16 MHz transducer. In addition, fluorescent dye indocyanine green (ICG) was used to visualize blood flow through the cerebral arteries and confirm that successful aneurysm clipping had been performed [8].

When surgical clipping or trapping was feasible, we performed a standard pterional craniotomy with a transsylvian approach, including removal of the anterior clinoid process. The inside-to-outside approach increased the success rate of proximal control of the ICA or MCA when aneurysm ruptures during clipping surgery. Then, we traced the MCA to find the distal aneurysm neck and dissect it for temporary clipping. Then, aneurysm clipping or trapping was performed.

## RESULTS

There were three men and three women and their ages ranged from 27 to 59 years. The follow-up period ranged from 2 to 116 months (mean 51.5 months). Four patients received two anastomoses via the frontal and parietal branches of the STA to the MCA branches. Ten EC-IC surgery procedures were performed for these six patients with complex cerebral aneurysms [Table 2]. Three of these patients had unruptured aneurysms and three had ruptured aneurysms. One unruptured aneurysm was an incidental finding on a regular physical examination. The second patient suffered from transient ischemic attacks, and the third case was detected during evaluation for frequent headaches. The initial symptoms of the three patients with ruptured aneurysms were sudden aphasia, severe headache, and consciousness change. One of the three patients (Case 1) with a ruptured aneurysm had sudden aphasia and became drowsy (Glasgow coma scale [GCS]: E3V2M5). Direct aneurysm clipping was performed in two cases, trapping of parent arteries in three cases, and endovascular proximal occlusion with Guglielmi detachable coiling in one case. Postoperative DSA showed 100% bypass patency and good aneurysm obliteration in all patients. There were no wound infections, meningitis, or subdural hematomas from anastomotic leakage. Mean Rankin scale scores ranged from 2 preoperatively to 0.67 postoperatively [Table 2]. Case 1 suffered from sudden aphasia (H&H Grade 3), and DSA revealed an MCA bizarre configuration aneurysm. Postoperatively, his consciousness was clear and no new neurological deficit except aphasia was noted.

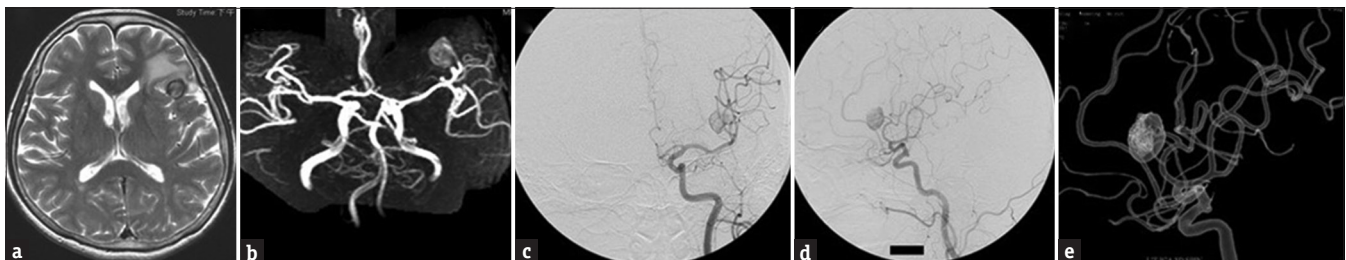
## Illustrative cases

### Case 2

A 58-year-old woman suffered from several episodes of transient aphasia. Brain magnetic resonance imaging (MRI) revealed focal edema in the left frontal lobe adjacent to Broca's speech area and a large lobulated partially thrombosed aneurysm [Figure 1a and b]. Cerebral DSA revealed a large aneurysm (about 15.7 mm × 10 mm) in the left MCA M2 segment of the left orbitofrontal artery [Figure 1c and d], suggestive of a dissecting aneurysm with partial thrombosis [Figure 1e]. The treatment principle was parent artery trapping via surgical trapping or transarterial embolization (TAE). However, trapping of the MCA branch carried a high risk of postoperative stroke. We performed an STA-MCA bypass (left STA to MCA M3 segment) to decrease the rate of postoperative stroke. Before TAE, she passed a balloon occlusion test. A pre-TAE angiogram of the left external carotid artery (ECA) revealed patency of the STA-MCA bypass and the moderate Hirai type of reestablished vasculature [Figure 2a]. In addition, there was only minimal flow in one M3 branch [Figure 2b]. TAE of the aneurysm was performed and a post-TAE angiogram of left ICA showed complete occlusion of the aneurysm and the proximal part of the parent artery [Figure 2c]. After TAE, the left ECA angiogram revealed remarkably increased blood flow [Figure 2d and e]. The effect of left STA flow may have been affected by the original MCA flow. After the aneurysm and proximal artery occlusion, resistance in the STA decreased and remarkably increased blood flow was noted. No obvious postoperative neurological deficit was noted.

### Case 3

A 51-year-old woman suffered from severe headaches and became deeply comatose (GCS: E1V2M1). Brain CT revealed a diffuse SAH and acute hydrocephalus [Figure 3a]. Emergency external ventricular drainage was performed for acute SAH-related hydrocephalus. Then, cerebral DSA revealed a left MCA bifurcation aneurysm [Figure 3b]. However, a bizarre configuration was noted. We dissected the frontal and parietal branches of the STA, and two STA-MCA bypasses (left STA to MCA M3 segment) were performed because of demand for a long ischemic time because of bizarre aneurysm [Figure 3b]. A standard left frontotemporal craniotomy with transsylvian approach was performed for direct aneurysm clipping. Then, we applied a temporal clip at the proximal MCA trunk for



**Figure 1:** Case 2: Preoperative survey (a) brain magnetic resonance T2 weighted image reveals focal edema in the left frontal lobe. (b) Brain magnetic resonance angiogram reveals a large lobulated partially thrombosed aneurysm. (c and d) Digital subtraction angiography of the left internal carotid artery anteroposterior and lateral views demonstrates a large aneurysm (about 15.7 mm × 10 mm) in the left middle cerebral artery M2 segment of the left orbitofrontal artery. (e) Three-dimensional rotation angiogram reveals an obvious partial thrombus

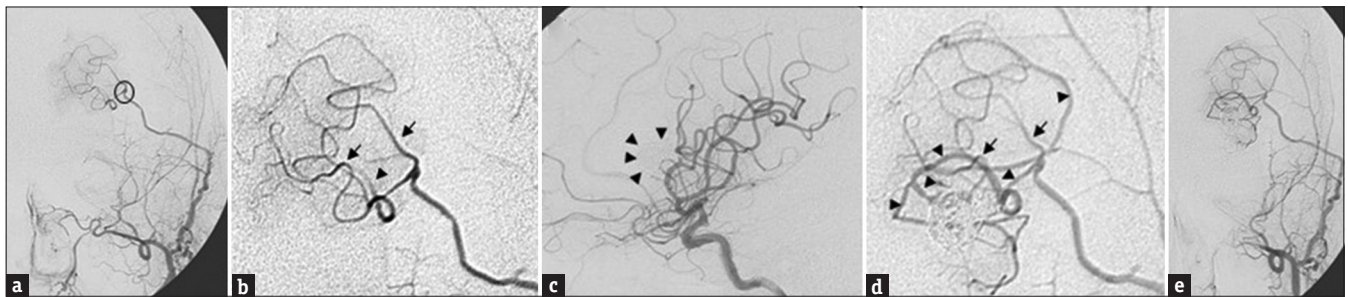


proximal control. A straight clip was applied in the prebifurcation region, and a right-angle clip was applied in bifurcation aneurysm [Figure 3c]. The temporal clip was removed. The total ischemic time during clipping was 160 s; postoperative cerebral DSA revealed good patency from the STA to the MCA [Figure 3d]. After surgery, her consciousness was clear, but right limb weakness (muscle power: 4) was noted.

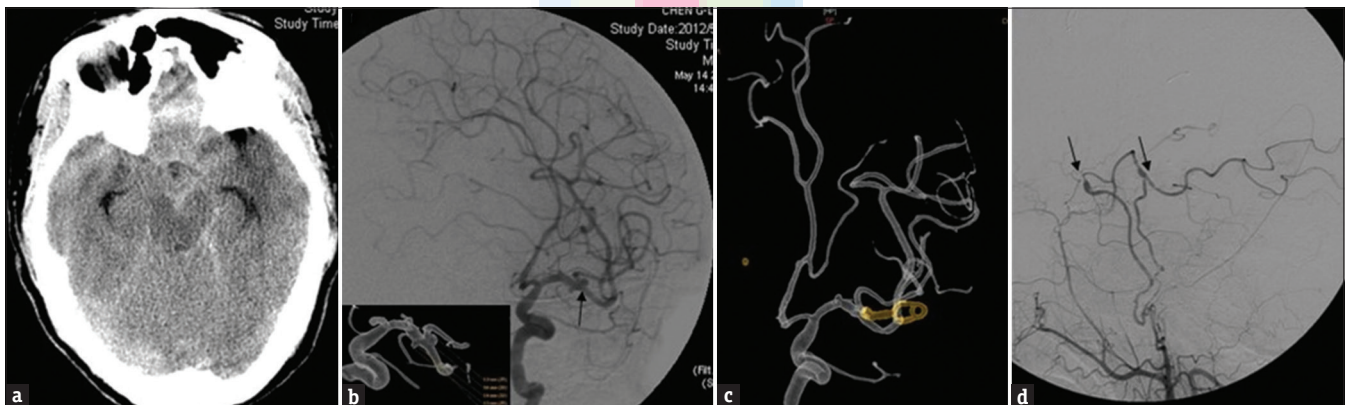
**Case 4**

A 57-year-old man received a regular physical examination and brain MRI revealed a fusiform aneurysm [Figure 4a]. Brain MRI performed about 7 years previously did not reveal this abnormal finding. Cerebral DSA revealed a large fusiform 20.2 cm aneurysm in the superior division of the right MCA M2

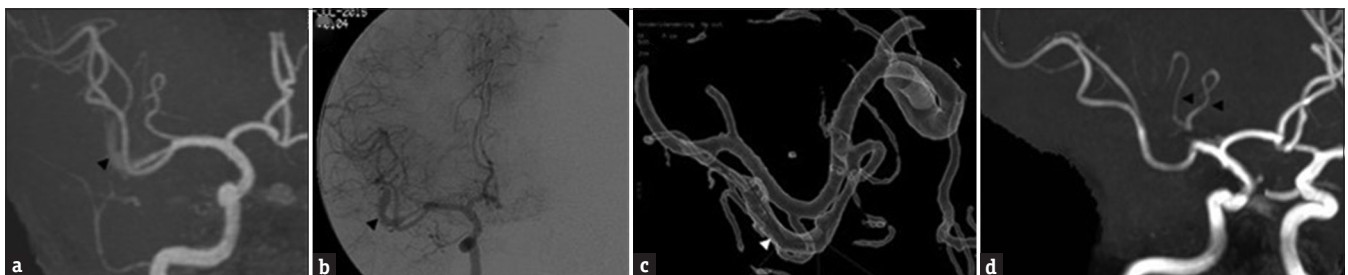
segment [Figure 4b and c], suggestive of a dissecting aneurysm. The treatment principle was parent artery occlusion via surgical trapping or TAE. However, sacrifice of the MCA branch carried a high risk of postoperative stroke. We performed two STA-MCA bypasses (frontal and parietal branches of the right STA to MCA M3 segment) to decrease the chance of postoperative stroke. A standard right frontotemporal craniotomy with a transsylvian approach was performed for trapping of the superior division of the right MCA M2. Then, two straight clips were applied for trapping of the superior division of the right MCA M2. Postoperative cerebral MRI angiography revealed patency from the STA to the MCA [Figure 4d]. The patient's postoperative consciousness was clear, and no neurological deficit was noted.



**Figure 2:** Case 2: Bypass and transarterial embolization (a and b) before transarterial embolization, a left external carotid artery angiogram reveals the anastomosis site of the bypass (circle) and the moderate Hirai type of reestablished vasculature (arrows); there is only minimal flow in one M3 branch (arrow head). (c) Complete obliteration (arrowheads) of the aneurysm after transarterial embolization. (d and e) After transarterial embolization, a left external carotid artery angiogram demonstrates the original two patent arteries (arrow) and remarkably increased blood flow (arrowheads)



**Figure 3:** Case 3: (a) Brain computed tomographic reveals a diffuse subarachnoid hemorrhage over the basal cistern. (b) Digital subtraction angiography of the left internal carotid artery reveals a bilobulated aneurysm at the middle cerebral artery bifurcation (arrow). (c) Digital subtraction angiography of the left internal carotid artery demonstrates complete obliteration of the aneurysm after clipping and patency of the middle cerebral artery branch. (d) Digital subtraction angiography of the left external carotid artery shows good patency of the low-flow bypass (arrows)



**Figure 4:** Case 4: Preoperative survey: (a) Brain magnetic resonance imaging reveals a fusiform aneurysm (arrow head). (b and c) Digital subtraction angiography of the right internal carotid artery reveals a fusiform aneurysm, suspected to be a dissecting aneurysm in the superior division of the middle cerebral artery M2 (arrow head). Postoperative survey: (d) Brain magnetic resonance imaging demonstrates complete obliteration of the aneurysm after trapping and patency of the bypass (arrow head)

## DISCUSSION

With clinicians well-trained in bypass techniques, STA-MCA bypass has long-term efficacy in the treatment of complex aneurysms and skull base tumors with major vessel invasion [9]. Our series of six complex MCA aneurysms treated with bypass surgery were derived from surgeries in 110 patients with MCA aneurysms. These bypass cases represented 5.4% of aneurysm surgeries done in our institution, which is close to the range in previously published results [2,10,11]. This experience highlights that bypass for complex MCA aneurysms is still essential even if advances in surgical clipping and endovascular treatment achieve great obliteration and clinical outcomes for most MCA aneurysms.

High flow EC-IC bypass can offer more blood flow in the distal circulation than low flow, but STA-MCA bypass, a low flow bypass, may also offer adequate perfusion with fewer surgical morbidities [2]. In addition, high flow and low flow bypasses have the same patency rate [12]. High flow bypass is technically demanding and may increase perioperative ischemic stroke, especially in areas with less collateral cerebral circulation, such as the MCA territory. A low-flow bypass has a lower risk of perioperative ischemic stroke [5]. Some reports suggested IC-IC bypass might reduce EC donor-related complications, such as shortened interposition grafts or differences in caliber between donor and recipient arteries. However, IC-IC bypass might not be feasible for the proximal MCA, given the widely spread perforating arteries. Furthermore, a lower patency rate has been noted in IC-IC bypass for complex aneurysms at specific anatomical segments [6]. Therefore, the choice of bypass surgery method must be individualized [6].

Direct surgical clipping can bring a remission rate of over 90% for patients with MCA aneurysms. This results not only in obliteration of the aneurysm but also in relief of mass effect from the aneurysm sac. Rupture of MCA aneurysms is also closely related to concomitant IC hematomas and regional mass effect and requires immediate surgical evacuation or a poor prognosis ensues [13]. On the other side, a low complete obliteration rate after endovascular therapy and a high recurrence rate have been reported [14]. Endovascular coiling provides less relief from mass effect [15]. These suggest that microsurgical clipping of complex aneurysms remains superior to that of endovascular embolization, and it should remain the first treatment choice [16,17].

Cerebral revascularization with good preparation can reduce the ischemic rate after bypass surgery [4,18]. However, without good preparation, the benefits of emergency bypass may be offset [5]. In our previous series, direct trapping for complex aneurysms was performed without the assistance of a bypass, but a possibility of a false negative on the balloon occlusion test was noted. Tearing of the aneurysm neck during direct clipping without assistance of bypass was noted. Poor recovery rates have been noted after emergency bypass in patients with complex ICA aneurysms [7]. Good preparation for STA-MCA bypass before aneurysm treatment can prevent ischemic stroke when major vessel sacrifice or prolonged ischemic time during surgery is inevitable [19]. If we note two MCA M3 branches of >1 mm during bypass surgery, two

bypasses are done. Feindel *et al.* first introduced intraoperative fluorescence angiography with the fluorescent dye ICG to visualize blood flow through the cerebral arteries and confirm successful aneurysm clipping [8]. Intraoperative angiography including transcranial Doppler and ICG angiography provides real-time information on the patency of the cerebral artery, and this may increase the success rate of early bypass grafts. Recently, we used a transcranial Doppler test and ICG angiography to check bypass patency and reduce the failure rate. This could explain the reasons for our high revascularization patency rate and lower modified Rankin scores compared with the previous results [1,2,10,11]. Bypass has been shown to rescue ischemic time during complex or giant aneurysm clipping [14]. Case 3 had a ruptured MCA aneurysm over the bifurcation with an initial H&H grade of 4. Even with longer temporary clipping of the parent artery, this patient recovered from a deep coma to full consciousness even though cerebral DSA showed the mild type of vasculature. Prognostic factors for clinical outcomes should not only include the surgical outcome of the bypass but also include the premorbid condition, collateral blood supply, and aneurysm treatment [20]. Park *et al.* showed that for large and giant aneurysms, aneurysm clipping was the most common treatment method, followed by clipping or trapping with bypass surgery and endovascular treatment. However, acute cerebral infarction was the most common complication (16.0%), and poor outcomes (modified Rankin scale score, 3–6) developed in 12.3% of aneurysms after treatment [21]. Although the initial condition and complications during treatment are independent risk factors, we hope that low flow bypass can help reduce the rate of postoperative stroke due to these conditions.

The balloon occlusion test is designed to simulate cerebral artery sacrifice. This procedure is usually performed over the ICA to make sure that collateral cerebral blood flow can offer adequate perfusion to prevent postoperative ischemic sequelae [22]. When neurological deficit is noted during test, the result is positive and a bypass should be performed for blood flow replacement and adequate cerebral perfusion. A superselective balloon occlusion test for major cerebral arteries located distal to the ICA has been adopted further to assist the surgical strategy for complex anterior cerebral artery or MCA aneurysms [23–25]. However, this test has a high false-negative rate of up to 20%–25% [26]. False-negative results can lead to symptomatic infarctions after parent artery trapping in aneurysm surgery without bypass. In our hospital, STA-MCA bypass for atherosclerotic cerebrovascular disease resulted in stable surgical outcomes, including low complication rate and high patency rate [18]. Therefore, we changed our treatment policy for patients with complex or large aneurysms. We performed the STA-MCA bypass first, followed by a balloon occlusion test. We anticipated this might decrease false-negative result-related morbidity. Aneurysm surgery is done after a negative balloon occlusion test. If the test result is still positive, another bypass is done. In our series of bypasses for complex MCA or ICA aneurysms, the false-negative rate was 6.7% (unpublished analysis), which is lower than the previous data [27]. In addition, some positive symptoms on the balloon occlusion test were hard to detect. For example,

headache was considered negative, but it has the potential to result in a false negative [22].

## CONCLUSIONS

STA-MCA (EC-IC) bypass provides additional blood flow to earn more ischemic time for aneurysm clipping and prevent ischemic stroke after sacrifice of parent arteries for complex MCA aneurysms. A balloon occlusion test of the MCA provides better planning for surgery and avoids neurological deficits. There is a risk of aneurysm neck tear with blister aneurysms and good preparation for bypass before aneurysm surgery might increase the safety and benefits of aneurysm surgery. Factors associated with the prognosis include not only the surgical result of the bypass but also the premorbid condition, collateral blood supply, and aneurysm treatment.

## Financial support and sponsorship

Nil.

## Conflicts of interest

There are no conflicts of interest.

## REFERENCES

- Kivipelto L, Niemelä M, Meling T, Lehecka M, Lehto H, Hernesniemi J, et al. Bypass surgery for complex middle cerebral artery aneurysms: Impact of the exact location in the MCA tree. *J Neurosurg* 2014;120:398-408.
- Seo BR, Kim TS, Joo SP, Lee JM, Jang JW, Lee JK, et al. Surgical strategies using cerebral revascularization in complex middle cerebral artery aneurysms. *Clin Neurol Neurosurg* 2009;111:670-5.
- Diaz OM, Rangel-Castilla L, Barber S, Mayo RC, Klucznik R, Zhang YJ, et al. Middle cerebral artery aneurysms: A single-center series comparing endovascular and surgical treatment. *World Neurosurg* 2014;81:322-9.
- Tsai ST, Yen PS, Wang YJ, Chiu TL. Superficial temporal artery-middle cerebral artery bypass for ischemic atherosclerotic middle cerebral artery disease. *J Clin Neurosci* 2009;16:1013-7.
- Cantore G, Santoro A, Guidetti G, Delfinis CP, Colonnese C, Passacantilli E, et al. Surgical treatment of giant intracranial aneurysms: Current viewpoint. *Neurosurgery* 2008;63:279-89.
- Abla AA, Lawton MT. Anterior cerebral artery bypass for complex aneurysms: An experience with intracranial-intracranial reconstruction and review of bypass options. *J Neurosurg* 2014;120:1364-77.
- Lee CH, Chiu TL, Tsai ST, Kuo WC. Extracranial-intracranial bypass in the treatment of complex or giant internal carotid artery aneurysms. *Tzu Chi Med J* 2015;27:113-9.
- Feindel W, Yamamoto YL, Hodge CP. Intracarotid fluorescein angiography: A new method for examination of the epicerebral circulation in man. *Can Med Assoc J* 1967;96:1-7.
- Schaller B. Extracranial-intracranial bypass to reduce the risk of ischemic stroke in intracranial aneurysms of the anterior cerebral circulation: A systematic review. *J Stroke Cerebrovasc Dis* 2008;17:287-98.
- Tayebi Meybodi A, Huang W, Benet A, Kola O, Lawton MT. Bypass surgery for complex middle cerebral artery aneurysms: An algorithmic approach to revascularization. *J Neurosurg* 2017;127:463-79.
- van Doormaal TP, van der Zwan A, Verweij BH, Han KS, Langer DJ, Tulleken CA, et al. Treatment of giant middle cerebral artery aneurysms with a flow replacement bypass using the excimer laser-assisted nonocclusive anastomosis technique. *Neurosurgery* 2008;63:12-20.
- Sia SF, Morgan MK. High flow extracranial-to-intracranial brain bypass surgery. *J Clin Neurosci* 2013;20:1-5.
- Stapleton CJ, Walcott BP, Fusco MR, Butler WE, Thomas AJ, Ogilvy CS, et al. Surgical management of ruptured middle cerebral artery aneurysms with large intraparenchymal or sylvian fissure hematomas. *Neurosurgery* 2015;76:258-64.
- Naggara ON, White PM, Guilbert F, Roy D, Weill A, Raymond J, et al. Endovascular treatment of intracranial unruptured aneurysms: Systematic review and meta-analysis of the literature on safety and efficacy. *Radiology* 2010;256:887-97.
- Heran NS, Song JK, Kupersmith MJ, Niimi Y, Namba K, Langer DJ, et al. Large ophthalmic segment aneurysms with anterior optic pathway compression: Assessment of anatomical and visual outcomes after endosaccular coil therapy. *J Neurosurg* 2007;106:968-75.
- Wang JT, Yang HC, Lin CF, Guo WY, Luo CB, Chen MH, et al. Bilobulated paraclinoid aneurysm mimics double aneurysms: A comparison of endovascular coiling and surgical clipping treatments. *J Chin Med Assoc* 2014;77:544-7.
- Steklacova A, Bradac O, Charvat F, De Lacy P, Benes V. "Clip first" policy in management of intracranial MCA aneurysms: Single-centre experience with a systematic review of literature. *Acta Neurochir (Wien)* 2016;158:533-46.
- Chiu TL, Tsai ST, Chiu CH. Prediction of flow augmentation and complications of extracranial-intracranial bypass in symptomatic cerebrovascular diseases. *J Clin Neurosci* 2012;19:814-9.
- Gazyakan E, Lee CY, Wu CT, Tsao CK, Craft R, Henry SL, et al. Indications and outcomes of prophylactic and therapeutic extracranial-to-intracranial arterial bypass for cerebral revascularization. *Plast Reconstr Surg Glob Open* 2015;3:e372.
- De Marchis GM, Lantigua H, Schmidt JM, Lord AS, Velander AJ, Fernandez A, et al. Impact of premorbid hypertension on haemorrhage severity and aneurysm rebleeding risk after subarachnoid haemorrhage. *J Neurol Neurosurg Psychiatry* 2014;85:56-9.
- Park W, Chung J, Ahn JS, Park JC, Kwun BD. Treatment of large and giant middle cerebral artery aneurysms: Risk factors for unfavorable outcomes. *World Neurosurg* 2017;102:301-12.
- Chaudhary N, Gemmete JJ, Thompson BG, Pandey AS. Intracranial endovascular balloon test occlusion-indications, methods, and predictive value. *Neurosurg Clin N Am* 2009;20:369-75.
- Isozaki M, Arai H, Neishi H, Kitai R, Kikuta KI. Super-selective balloon test occlusion of the posterior communicating artery in the treatment of a posterior cerebral artery fusiform aneurysm: A Case report. *NMC Case Rep J* 2016;3:129-31.
- Jeong YH, Kim JY, Koo YM, Choi JW, Whang K, Hu C, et al. Endovascular treatment of giant serpentine aneurysm of the middle cerebral artery. *J Cerebrovasc Endovasc Neurosurg* 2016;18:264-70.
- Pabaney AH, Mazaris PA, Kole MK, Reinard KA. Endovascular management of fusiform aneurysm of anterior temporal artery: Technical report. *Surg Neurol Int* 2015;6:119.
- Lesley WS, Bieneman BK, Dalsania HJ. Selective use of the paraophthalmic balloon test occlusion (BTO) to identify a false-negative subset of the cervical carotid BTO. *Minim Invasive Neurosurg* 2006;49:34-6.
- Linskey ME, Jungreis CA, Yonas H, Hirsch WL Jr., Sekhar LN, Horton JA, et al. Stroke risk after abrupt internal carotid artery sacrifice: Accuracy of preoperative assessment with balloon test occlusion and stable xenon-enhanced CT. *AJNR Am J Neuroradiol* 1994;15:829-43.