



## Images in Clinical Medicine

# Glomus tumor with rare clinical presentation as chronic shoulder pain

Reddy Ravikanth<sup>a\*</sup>, Anush Nagotu<sup>b</sup>

<sup>a</sup>Department of Radiology, St. John's Medical College, Bengaluru, Karnataka, India, <sup>b</sup>Department of General Surgery, St. John's Medical College, Bengaluru, Karnataka, India

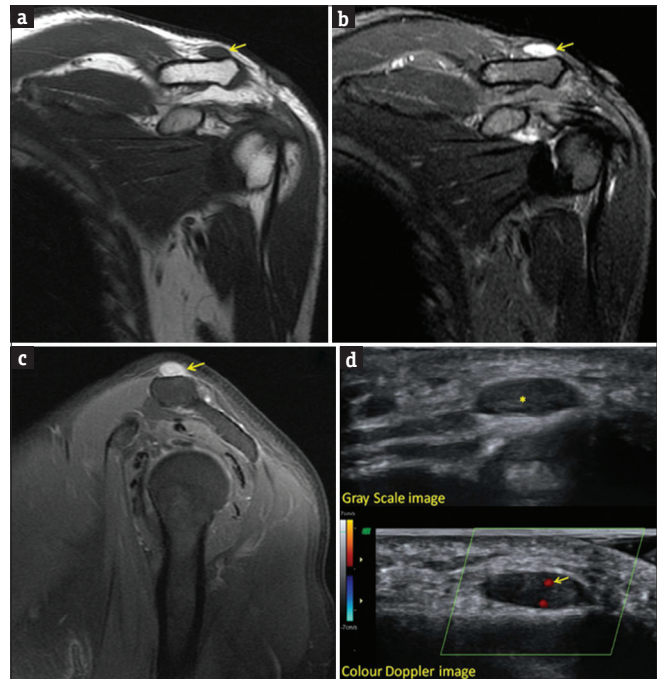
Received : 03-Aug-2017

Revised : 21-Aug-2017

Accepted : 13-Sep-2017

A 56-year-old man presented to the orthopedics department with chronic shoulder pain for 4 years not relieved by medication or physiotherapy. On physical examination, there was no restriction of movement, and there was focal tenderness over the lateral aspect of the clavicle. Magnetic resonance (MR) imaging, showed a well-defined T1 hypointense lesion [Figure 1a, arrow], which was hyperintense on short T<sub>1</sub> inversion recovery images [Figure 1b, arrow]. The lesion was smaller than 1 cm, showed homogeneous enhancement in postcontrast T1-weighted images [Figure 1c, arrow] and was superior to the distal end of the clavicle in the subcutaneous plane. There was no obvious communication of the lesion with either the acromioclavicular or glenohumeral joint. There was no erosion, remodeling, or sclerosis of the superior clavicular surface. The fat planes with all 14 surrounding structures were maintained. Correlative ultrasound revealed a well-defined, homogeneously hypoechoic lesion [Figure 1d, asterisk] with minimal intralesional vascularity [Figure 1d, arrow]. Surgical excision of the lesion resulted in complete disappearance of symptoms and follow-up imaging showed no recurrence.

Glomus tumors are true benign neoplasms originating from the glomus bodies and have been reported to account for 1%–6% of all soft-tissue tumors [1]. Glomus tumor was first described by Wood in 1912, but the correct origin was clarified as hyperplasia of a normal glomus body by Masson in 1924 [2]. Classic glomus tumors are typically solitary. They are most commonly smaller than 1 cm and located in the upper extremities, especially the hands and subungual regions [3]. Glomus tumor is a hamartoma that develops from a neuromyoarterial glomus body and consists of dilated vascular channels surrounded by proliferating glomus and nerve cells. There is no sex predilection and the most common age at presentation is 20–40 years [4]. It is rare in certain locations such as the extremities, trunk, and viscera. The forearm is the most common extradigital location, with the shoulder and back the least common. Clinical manifestations include paroxysms of pain, cold sensitivity, and point tenderness with signs of hyperesthesia, muscle atrophy, or osteoporosis in the affected area. We presented imaging findings in a rare case of glomus tumor with chronic shoulder pain. Malignant transformation



**Figure 1:** (a) T1-weighted Magnetic resonance image showing a well-defined hypointense lesion (arrow) superior to the distal end of the clavicle. (b) Well-defined lesion (arrow) showing short T<sub>1</sub> inversion recovery hyperintensity. (c) Lesion (arrow) showing homogenous enhancement on postcontrast T1-weighted image. (d) Ultrasound grey scale and color Doppler images showing a well-defined, homogeneously hypoechoic lesion (asterisk) with minimal intralesional vascularity (arrow)

is rare. Hemangiomas are a close imaging differential for glomus tumors [5]. Ultrasound findings include a cystic/solid hypoechoic mass and rarely, erosion of the underlying bone. Intratumoral vascular shunts are noted in color Doppler imaging. MR imaging shows an intermediate or low-signal intensity on T1-weighted images, marked hyperintensity on T2-weighted images, and strong postcontrast imaging. MR

*\*Address for correspondence:*

Dr. Reddy Ravikanth,  
Department of Radiology, St. John's Medical College,  
Bengaluru - 560 034, Karnataka, India.  
E-mail: ravikanthreddy06@gmail.com

### Access this article online

#### Quick Response Code:



Website: [www.tcmjmed.com](http://www.tcmjmed.com)

DOI: 10.4103/tcmj.tcmj\_99\_17

This is an open access journal, and articles are distributed under the terms of the Creative Commons Attribution-NonCommercial-ShareAlike 4.0 License, which allows others to remix, tweak, and build upon the work non-commercially, as long as appropriate credit is given and the new creations are licensed under the identical terms.

For reprints contact: [reprints@medknow.com](mailto:reprints@medknow.com)

**How to cite this article:** Ravikanth R, Nagotu A. Glomus tumor with rare clinical presentation as chronic shoulder pain. Tzu Chi Med J 2018;30(1):51-2.

angiography shows a focus of strong enhancement in the arterial phase and tumor blush, which progressively increases in size in the delayed phase. The treatment of choice for glomus tumors is complete excision, and even in cases of malignant transformation, no chemotherapy or radiation is needed [6].

Glomus tumors are neoplasms that arise from modified smooth muscle cells of the glomus body, which is a specialized form of an arteriovenous anastomosis that plays a significant role in the regulation of skin circulation. The present study reports a case of a glomus tumor in a man with chronic shoulder pain for 4 years. A correct clinical diagnosis was obtained from imaging modalities (ultrasound and MR imaging).

#### **Declaration of patient consent**

The authors certify that the patient consent form has been obtained. In the form, the patient has given his consent for his images and other clinical information to be reported in the journal. The patient understands that his name and initial will not be published and due efforts will be made to conceal their identity, but anonymity cannot be guaranteed.

#### **Financial support and sponsorship**

Nil.

#### **Conflicts of interest**

There are no conflicts of interest.

#### **REFERENCES**

1. Proietti A, Ali G, Quilici F, Bertoglio P, Mussi A, Fontanini G, et al. Glomus tumor of the shoulder: A case report and review of the literature. *Oncol Lett* 2013;6:1021-4.
2. Ghaly RF, Ring AM. Supraclavicular glomus tumor, 20 year history of undiagnosed shoulder pain: A case report. *Pain* 1999;83:379-82.
3. Boretto JG, Lazerges C, Coulet B, Baldet P, Chammas M. Calcified glomus tumor of the shoulder. A case report. *Chir Main* 2008;27:183-6.
4. Gautam VK, Agarwal PK, Maini L, Prakash A. Intraosseous glomus tumor in acromion process of scapula. *Orthopedics* 2008;31:406.
5. Roberts SN, Carter C, Brown JN, Hayes MG, Saies A. Enormous glomus tumor of the shoulder. *J Shoulder Elbow Surg* 1999;8:365-6.
6. Heiney JP, Leeson MC. Unique size and location of a glomus tumor with a review of the literature. *J Shoulder Elbow Surg* 2009;18:e1-3.