



Original Article

Modified conjunctival flap as a primary procedure for nontraumatic acute corneal perforation

Yi-Chen Sun^{a,b*}, Jason P. Kam^b, Tueng T. Shen^b

^aDepartment of Ophthalmology,
Taipei Tzu Chi Hospital,
Buddhist Tzu Chi Medical
Foundation, New Taipei, Taiwan,
^bDepartment of Ophthalmology,
University of Washington,
Seattle, WA, USA

ABSTRACT

Objective: Appropriate management of nontraumatic acute corneal perforation is always a challenge even with the many advances in surgical materials and techniques. We reported the outcomes of a case series of acute corneal perforation repair using a newly modified conjunctival flap with amniotic membrane transplant (AMT), fibrin glue, and a bandage soft contact lens (BCL). **Materials and Methods:** A total of 13 consecutive referral cases with nontraumatic acute corneal perforation at the University of Washington were reviewed. All open globes were repaired by a combined surgery with a modified conjunctival flap, AMT, fibrin glue, and BCL. Visual acuity, a slit lamp examination, and the patient-reported pain level were collected preoperatively and postoperatively. Subsequent corneal surgeries to improve visual function were also reviewed. **Results:** All ocular surfaces of the 13 eyes were stable at postoperative follow-up. Eleven of the 13 patients had the same or worse visual acuity 1 week postoperatively. Nine of the 13 patients achieved better vision 6 months postoperatively. None of the patients developed perioperative or postoperative complications. Five patients with good visual potential underwent further corneal surgeries, including Boston keratoprosthesis and penetrating keratoplasty. The average referral distance was 217 miles and the median number of follow-up visits within 6 months was 4. **Conclusions:** The combination of a modified conjunctival flap, AMT, fibrin glue, and a BCL could provide a temporary method to stabilize and secure the integrity of the globe as well as the ocular surface after a nontraumatic acute corneal perforation. This approach allows easy follow-up and preserves the eye for future corneal surgery under optimal conditions.

KEYWORDS: Amniotic membrane transplant, Conjunctival flap, Corneal perforation, Fibrin glue, Gundersen flap

Received : 13-Jun-2017
Revised : 13-Sep-2017
Accepted : 09-Oct-2017

INTRODUCTION

Conjunctiva is a well-vascularized ocular tissue. It recruits cells such as fibroblasts and leukocytes into the cornea to promote wound healing. Total conjunctival flaps (TCF) have been used widely for various ocular surface disorders since 1958 [1]. The indications for TCF have ranged from chronic corneal ulceration due to infection, inflammation, and trauma (from small wounds) to alleviation of pain from severe alkali burns or other painful and chronic ocular diseases. A TCF can always provide a good protective covering for the cornea.

The use of conjunctival flaps has decreased in the past 10 years due to great improvements in medications, biomaterials, surgical instruments, and techniques. Nonetheless, conjunctival flaps still have many advantages in treating ocular surface disorders [2,3], including better control of corneal inflammation and pain, no need for donor tissue, fewer follow-up visits, and use of a technically easy procedure. The

goal of this treatment is to preserve the globe and rehabilitate the cornea for delayed definitive treatment.

Herein, we present a case series of patients with nontraumatic acute perforated corneas successfully treated with a combination of a modified conjunctival flap with amniotic membrane transplant (AMT), fibrin glue, and a bandage soft contact lens (BCL).

MATERIALS AND METHODS

Patient collection

Thirteen consecutive patients presenting with nontraumatic acute perforated corneas were included in this study from

*Address for correspondence:

Dr. Yi-Chen Sun,
Department of Ophthalmology, Taipei Tzu Chi Hospital, Buddhist Tzu Chi
Medical Foundation, 289, Jian-Guo Road, New Taipei, Taiwan.
E-mail: ycsun5830@gmail.com

This is an open access journal, and articles are distributed under the terms of the Creative Commons Attribution-NonCommercial-ShareAlike 4.0 License, which allows others to remix, tweak, and build upon the work non-commercially, as long as appropriate credit is given and the new creations are licensed under the identical terms.

For reprints contact: reprints@medknow.com

How to cite this article: Sun YC, Kam JP, Shen TT. Modified conjunctival flap as a primary procedure for nontraumatic acute corneal perforation. Tzu Chi Med J 2018;30(1):24-8.

Access this article online	
Quick Response Code: 	Website: www.tcmjmed.com
	DOI: 10.4103/tcmj.tcmj_191_17

2008 to 2014 at Harborview Medical Center, University of Washington, Seattle, WA, USA. Etiologies of acute corneal perforation in those patients included neurotrophic corneal ulceration, corneal ectasia, and descemetocoele with impending perforation. Nine of the 13 patients were diagnosed with underlying systemic diseases, such as rheumatoid arthritis, Fabry's disease, Ehlers–Danlos syndrome, leukemia, chronic graft-versus-host-disease, and trigeminal squamous carcinoma. Perforation sizes varied from pinpoint to 4 mm. All perforations were located around the center or the inferior part of the cornea. Patients were considered eligible for modified conjunctival flap placement if they had a chronically thin or perforated cornea with poor visual potential or untenable regular follow-up. The study was conducted in accordance with the Declaration of Helsinki and was approved by the Institutional Review Board of Harborview Medical Center. Informed written consent was waived because the study was a retrospective data analysis.

Surgical techniques

Eleven of the 13 patients underwent general anesthesia. Topical anesthesia was administered for the remaining two surgical repairs. First, we surgically debrided the loose epithelium surrounding the perforation and repositioned the prolapsed iris or uveal tissue away from the wound. Then, a 180° peritomy was performed from 3 to 9 o'clock. The inferior conjunctiva was mobilized as much as possible. If the perforation of the cornea was associated with severe tissue melting, an amniotic membrane (Ambio5, IOP Ophthalmics, Denville, NJ, USA) combined with fibrin glue (TISSEEL, Baxter, Deerfield, IL, USA) was applied to stabilize the perforation site. If there was no significant tissue loss, fibrin glue alone was applied without the amniotic membrane. The inferior mobilized conjunctiva was then positioned superiorly to cover the area of corneal perforation accompanied by fibrin glue application to stabilize the conjunctival tissue over the corneal perforation. Three interrupted 10-0 nylon sutures were used to secure the conjunctival flap onto the corneoscleral bed at the 3, 6, and 9 o'clock positions. A large BCL (20 mm) (Kontur Kontakt, Hercules, CA, USA) was placed, and a subconjunctival injection of antibiotic was given at the end of the procedure. Photographs of this modified conjunctival flap surgery are provided in Figure 1.

Postoperative observation

Postoperative visual acuity, intraocular pressure, and slit-lamp examination were checked routinely in the clinic. Grading of postoperative pain (0–3+) and globe stability was also collected postoperatively. Globe stability was graded as good, medium, or poor. Good globe stability was determined by the presence of stable reepithelialization, no leakage, acceptable healing of the flap, and an appropriate surface for a secondary procedure. Medium globe stability was defined as variable reepithelialization and/or surface condition and possibly able to sustain a secondary procedure with further healing. Poor globe stability was defined as poor reepithelialization, poor adherence of the conjunctival flap with residual infection, ulceration, or degradation of the ocular surface threatening the viability of the eye. Surgical success was defined as a stable ocular surface without flap retraction or dehiscence, and the absence of persistent symptoms or pain. Complications were recorded,

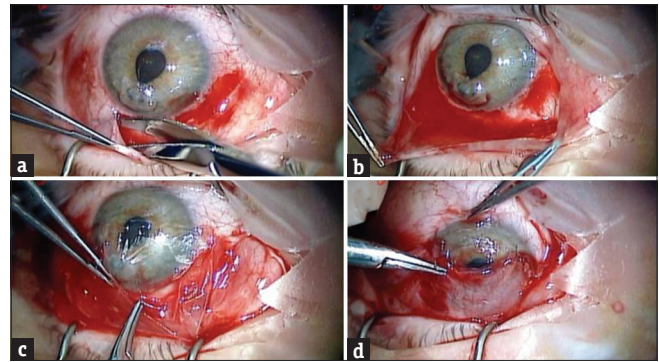


Figure 1: The modified conjunctival flap surgery in this study. An inferior 180° peritomy performed adjacent to the perforation site (a). Appropriate Tenon's tissue dissection to mobilize the conjunctiva (b). Mobilizing the inferior conjunctiva over the underlying amniotic membrane graft (c). Fibrin glue is injected between the modified conjunctival flap and the amniotic membrane graft. Anchoring sutures are placed to further secure the flap (d)

including the progression of an infectious or inflammatory process beneath the flap, flap loss from epithelial ingrowth, and/or epithelial cyst formation.

RESULTS

The preoperative and postoperative characteristics of the patients are presented in Table 1. Thirteen patients (9 men and 4 women) received the procedure using a modified conjunctival flap combined with fibrin glue, and application of a large BCL. Meanwhile, 11 of these 13 patients also underwent AMT during the procedure. The average age of the patients was 51 years old (range, 17–71 years old). Most of the corneal perforations were located in the center of the cornea (8 of 13) [Figure 2a and b]. Three paracentral corneal perforations and two inferiorly peripheral corneal perforations were included in this study. The average perforation size was 2.5 mm (range, pinpoint to 4 mm). Two to four months after the primary procedure, all corneas had thin conjunctival flaps and intact globe integrity [Figure 2c–e]. The follow-up period in this study was 6–48 months. Five of the 13 patients underwent secondary procedures, including penetrating keratoplasty (PKP) (three patients, 6 months after the primary procedure) [Figure 2f and g] and Boston keratoprosthesis (Kpro) (two patients, 1 year after the primary procedure) [Figure 2h]. The patients who received PKP as their secondary procedure recovered very well without marked corneal neovascularization following the primary procedure.

The preoperative best-corrected visual acuity in these 13 patients ranged from light-perception to 20/40. Most of the patients (11 out of 13) had the same or worse visual acuity right after their surgeries. However, most of them achieved better vision 6 months postoperatively. All patients with pain experienced almost immediate pain relief after the primary procedure. Only 1 of the thirteen had complaints of postoperative pain on the postoperative day 1. No wound leakage was found postoperatively and globe stability was graded “good” in all patients. There were no perioperative or postoperative complications. The median number of follow-up visits within 6 months was 4 (range, 1–8). The average referral distance was 217 miles (range, 11–2100 miles).

Table 1: Pre- and post-operative patient characteristics

Gender	Age	Underlying systemic diseases	Preoperative VA	Postoperative VA 1 week	Postoperative VA 6 months	Final Change in VA	Postoperative globe stability	Preoperative pain	Postoperative pain	Postoperative infection	Distance of referral (miles)	Follow-up visits within 6 months	Secondary procedure
#1	Male	52 Fabry's disease	N/A	HM	20/400	Improved	Good	0	0	None	44	1	PKP
#2	Male	40 Ehlers-Danlos syndrome	LP	LP	20/80	Improved	Good	0	0	None	68	1	Kpro
#3	Female	52 None	200E@6'	HM	20/400	Improved	Good	2+	0	None	18	6	None
#4	Male	44 None	200E@5'	CF	20/20	Improved	Good	1+	0	None	28	8	None
#5	Male	71 AML	20/300	20/200	20/100	Improved	Good	1+	0	None	2100	2	None
#6	Male	17 None	HM	HM	20/800	Improved	Good	0	0	None	136	3	None
#7	Male	62 Trigeminal squamous carcinoma	HM	HM	HM	No change	Good	0	0	None	56	2	Kpro
#8	Male	57 Rheumatoid arthritis	CF@3'	LP	LP	No change	Good	3+	0	None	48	4	PKP
#9	Female	47 Rheumatoid arthritis	20/200	CF@2'	20/50	Improved	Good	1+	0	None	156	4	None
#10	Female	68 Breast cancer, myelodysplasia, GVHD	20/40	20/70	20/25	Improved	Good	3+	2+	None	37	3	None
#11	Male	58 Bilateral ocular rosacea	20/100	20/200	20/70	Improved	Good	1+	0	None	11	5	None
#12	Male	48 None	HM	HM	HM@1.5'	Improved	Good	1+	0	None	17	7	PKP
#13	Female	46 ALL, GVHD	HM	LP	LP	No change	Good	1+	0	None	100	5	None

VA: Visual acuity, N/A: Not available, HM: Hand motion, LP: Light perception, CF: Counting fingers, AML: Acute myeloid leukemia, ALL: Acute lymphoblastic leukemia, GVHD: Graft-versus-host disease, PKP: Penetrating keratoplasty, Kpro: Boston keratoprosthesis

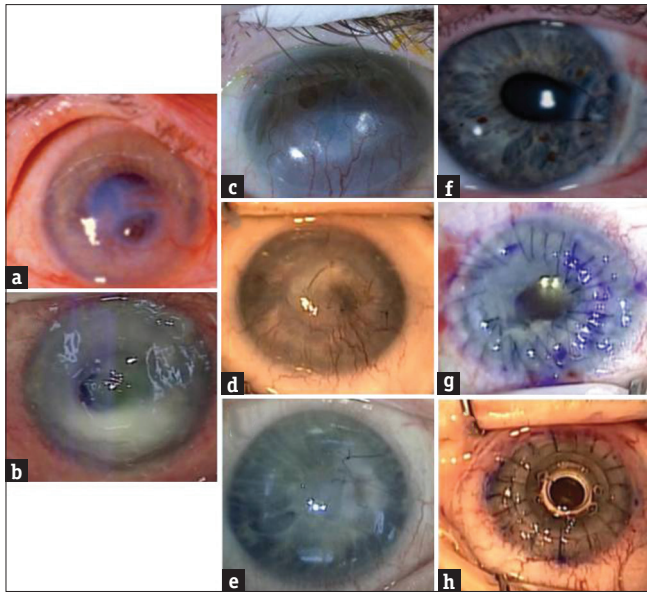


Figure 2: Patients preoperatively (a and b), postoperatively (c-e), and at final outcome (f-h). Patients presenting with acute corneal perforation located paracentrally (a and b). Two to four months after the primary procedure, the conjunctival flap looks thinner with sutures in place and intact globe integrity (c-e). Patients receiving secondary procedures, including corneal patch grafting (f), penetrating keratoplasty (g), and Boston keratoprosthesis (h)

DISCUSSION

Nontraumatic acute corneal perforation is always a challenge for a tertiary referral center. The treatment of choice for acute corneal perforation repair depends on the size and location of the perforation, general condition of the ocular surface, presence of infection, cause of perforation, available surgical materials (i.e., corneal tissue, amniotic membrane, and fibrin glue), and patient's compliance with treatment instructions. We report a case series of patients with nontraumatic acute corneal perforation who were successfully treated with a combination of the modified conjunctival flap, AMT, fibrin glue, and a large BCL without complications.

The use of AMT [4-7], fibrin glue [4-6], and a BCL [8] alone or in combination has been reported as reasonable and effective in treating acute corneal perforation. These methods appear effective in closing corneal perforations, but may not provide enough structural support for corneal rehabilitation. A conjunctival flap can provide this structural support. Conventionally, a conjunctival flap was avoided in the treatment of corneal perforation because of poor cosmesis, poor postoperative vision, and poor view for examination, especially during the first few weeks postoperatively. A conventional Gundersen's flap [1,2] is a relatively time-consuming procedure and results in some level of flap retraction postoperatively. However, there are still many advantages in using a conjunctival flap for the acute perforated cornea, including better vascularity to improve corneal wound healing, immediate pain relief, no need for donor tissue or autograft, and ease of the procedure. In 2009, Bawazeer *et al.* demonstrated a modified Gundersen's flap by placing the flap vertically to reduce the retraction force from the upper eyelid [9]. Unfortunately, they reported a complication rate of approximately 10% in their study. Instead

of a Gundersen's flap or modified Gundersen's flap [9,10], we developed a newly modified conjunctival flap along with the use of an amniotic membrane patch and fibrin glue in this study. This modified flap was much easier to perform with only an inferior 180° peritomy and some dissection beyond the inferior Tenon's capsule. We anchored the flap with three interrupted conjunctivo-scleral stitches (3, 6, and 9 o'clock) with additional fibrin glue application. These three stitches could counteract the force of conjunctival flap retraction in the early stage. In addition, the suture at 6 o'clock could reduce movement of the conjunctival flap postoperatively.

AMT is widely applied in a variety of ocular surface diseases [11-15]. It is indeed an effective treatment for most nontraumatic acute perforations. However, the outcome of treatment may nonetheless be compromised in patients with underlying systemic diseases which are often associated continuous corneal melting postoperatively or patients who cannot have regular checkups. We believe that the modified conjunctival flap likely provides better and longer protection, and it thereby contributed to satisfactory results for the 11 study patients who received this treatment. Notably, neovascularization was not observed among the three patients who subsequently received PKP as a secondary procedure. Indeed, it has been demonstrated that human amniotic membrane has an antiangiogenic effect on severely damaged corneas [16]. The modified conjunctival flap surgery was performed in conjunction with AMT in this study, and the satisfactory treatment outcome was appropriately attributed to the combination of both procedures.

Although our study mostly focused on nontraumatic acute corneal perforation, this modified conjunctival flap combined with AMT may also be considered as a treatment choice for severe noninfectious corneal ulceration or impending perforation. To the best of our knowledge, conjunctival resection has been primarily used for rheumatoid corneal ulceration management [17]; however, whether this treatment can be as effective when applied to rheumatoid corneal perforation is less reported. In this study, we used modified conjunctival flap on two rheumatoid patients, one with corneal perforation and the other with an impending perforation. With appropriate postoperative medications including topical steroids, antibiotics, and lubricants, patients generally recovered well after this primary procedure.

CONCLUSIONS

Patients with nontraumatic acute perforated corneas underwent a combination of a modified conjunctival flap, AMT, fibrin glue, and BCL application, and all had favorable outcomes in our study. With the advent of Kpro and other sight-saving procedures, salvage of the globe primarily for secondary procedures may help reestablish useful sight to the patient. Furthermore, the procedure we introduced here is safe and does not require intensive follow-up, making it a preferred procedure in populations where resources are scarce or compliance difficult.

Acknowledgment

We would like to thank Dr. Naomi Odell for her extraordinary work in data acquisition and data analysis throughout this case series.

Financial support and sponsorship

Nil.

Conflicts of interest

There are no conflicts of interest.

REFERENCES

- Gundersen T. Conjunctival flaps in the treatment of corneal disease with reference to a new technique of application. *AMA Arch Ophthalmol* 1958;60:880-8.
- Alino AM, Perry HD, Kanellopoulos AJ, Donnenfeld ED, Rahn EK. Conjunctival flaps. *Ophthalmology* 1998;105:1120-3.
- Kim S, Yang Y, Kim J. Primary pterygium surgery using the inferior conjunctival transposition flap. *Ophthalmic Surg Lasers* 1998;29:608-11.
- Duchesne B, Tahi H, Galand A. Use of human fibrin glue and amniotic membrane transplant in corneal perforation. *Cornea* 2001;20:230-2.
- Hick S, Demers PE, Brunette I, La C, Mabon M, Duchesne B, et al. Amniotic membrane transplantation and fibrin glue in the management of corneal ulcers and perforations: A review of 33 cases. *Cornea* 2005;24:369-77.
- Kim HK, Park HS. Fibrin glue-assisted augmented amniotic membrane transplantation for the treatment of large noninfectious corneal perforations. *Cornea* 2009;28:170-6.
- Rodríguez-Ares MT, Touriño R, López-Valladares MJ, Gude F. Multilayer amniotic membrane transplantation in the treatment of corneal perforations. *Cornea* 2004;23:577-83.
- Arora R, Jain S, Monga S, Narayanan R, Raina UK, Mehta DK, et al. Efficacy of continuous wear pureVision contact lenses for therapeutic use. *Cont Lens Anterior Eye* 2004;27:39-43.
- Bawazeer A, Maniyar A, Mintsoulis G, Al-Muammar A. The Gundersen flap: A new modification. *J King Abdulaziz Univ Med Sci* 2009;16:21-7.
- Lauring L, Wergeland FL Jr. Total conjunctival flap with a modification of the Gundersen operation. *Am J Ophthalmol* 1973;76:953-6.
- Chen HC, Tan HY, Hsiao CH, Huang SC, Lin KK, Ma DH, et al. Amniotic membrane transplantation for persistent corneal ulcers and perforations in acute fungal keratitis. *Cornea* 2006;25:564-72.
- Ghanavati SZ, Shousha MA, Betancurt C, Perez VL. Combined conjunctival autograft and overlay amniotic membrane transplantation; a novel surgical treatment for pterygium. *J Ophthalmic Vis Res* 2014;9:399-403.
- López-García JS, Rivas L, García-Lozano I, Conesa E, Elosua I, Murube J, et al. Amniotic membrane transplantation in acute toxic epidermal necrolysis: Histopathologic changes and ocular surface features after 1-year follow-up. *Eur J Ophthalmol* 2014;24:667-75.
- Malhotra C, Jain AK. Human amniotic membrane transplantation: Different modalities of its use in ophthalmology. *World J Transplant* 2014;4:111-21.
- Ricciardelli G, Ceccuzzi R, Raneri M, Scalisi A, Bianchi PE. Management of recurrent corneal ulcers: Use of amniotic membrane. *Eur J Ophthalmol* 2014;24:793-6.
- Kim JC, Tseng SC. The effects on inhibition of corneal neovascularization after human amniotic membrane transplantation in severely damaged rabbit corneas. *Korean J Ophthalmol* 1995;9:32-46.
- Feder RS, Krachmer JH. Conjunctival resection for the treatment of the rheumatoid corneal ulceration. *Ophthalmology* 1984;91:111-5.