




Contents lists available at ScienceDirect

Tzu Chi Medical Journal

journal homepage: www.tzuchimedjnl.com

Original Article

Comparison between the Trachway video intubating stylet and Macintosh laryngoscope in four simulated difficult tracheal intubations: A manikin study

Jimmy Ong^a, Chia-Ling Lee^b, Shen-Jer Huang^b, Ming-Hwang Shyr^{b,*}^a Department of Anaesthesiology, Sarawak General Hospital, Malaysia^b Department of Anesthesiology, Buddhist Tzu Chi General Hospital and Tzu Chi University, Hualien, Taiwan

ARTICLE INFO

Article history:

Received 9 May 2016

Received in revised form

7 June 2016

Accepted 14 June 2016

Available online 27 July 2016

Keywords:

Adult learning

Difficult intubation

Medical simulation

Video laryngoscope

ABSTRACT

Objectives: It remains to be determined whether the TVI-4000 Trachway video intubating (TVI) stylet (Markstein Sichtec Medical Corp, Taichung, Taiwan), an airway device for novices, improves airway management practice by experienced anesthesiologists. The aim of this study was to evaluate the feasibility of using the TVI stylet in difficult tracheal intubation situations compared with that of using the Macintosh laryngoscope on an airway manikin.

Materials and Methods: Ten anesthesiologists (with 3–21 years' experience), including three senior residents, participated. We compared tracheal intubation in four airway scenarios: normal airway, tongue edema, cervical spine immobilization, and tongue edema combined with cervical spine immobilization. The time of tracheal intubation (TTI), success rate, and perceived difficulty of intubation for each scenario were compared and analyzed.

Results: The TTI was significantly shorter in both the tongue edema and combined scenarios with the TVI stylet compared with the Macintosh laryngoscope (21.60 ± 1.45 seconds vs. 24.07 ± 1.58 seconds and 23.73 ± 2.05 seconds vs. 26.6 ± 2.77 seconds, respectively). Success rates for both devices were 100%. Concomitantly, participants rated using the TVI stylet in these two scenarios as being less difficult.

Conclusion: The learning time for tracheal intubation using the TVI stylet in difficult airway scenarios was short. Use of the TVI stylet was easier and required a shorter TTI for tracheal intubation in the tongue edema and combined scenarios.

Copyright © 2016, Buddhist Compassion Relief Tzu Chi Foundation. Published by Elsevier Taiwan LLC. This is an open access article under the CC BY-NC-ND license (<http://creativecommons.org/licenses/by-nc-nd/4.0/>).

1. Introduction

For decades, airway management has remained a challenging issue for clinical anesthesiologists. Direct laryngoscopy is usually performed for routine tracheal intubation [1,2]. However, performing this technique may prove difficult or even impossible under certain situations, such as in patients having tongue edema, cervical immobilization, and limitation of mouth opening [3,4]. This can result in airway trauma or severe complications. Failed or

difficult intubation is an important cause of mortality and morbidity during anesthesia.

In its newest practice guidelines, the American Society of Anesthesiologists recommends that videolaryngoscopy can and should be considered both as an initial approach to intubation (awake or following induction of general anesthesia) and following failed intubation in which face mask ventilation is adequate [5]. A number of devices have been developed to circumvent the difficult airway problems typically encountered with direct laryngoscopy. These devices include the flexible fiber optic bronchoscope, rigid optical stylet, lightwand, rigid fiberscope, and many types of video laryngoscopes, including the Trachway video intubating (TVI) stylet (TVI-4000; Markstein Sichtec Medical Corp., Taichung, Taiwan). The true test of airway management is comfort with troubleshooting backup and rescue devices. Practitioners should practice airway management skills regularly, must be familiar with the tools

Conflicts of interest: none.

* Corresponding author. Department of Anesthesiology, Buddhist Tzu Chi General Hospital, 707, Section 3, Chung-Yang Road, Hualien, Taiwan. Tel.: +886 3 8561825x16238; fax: +886 3 8575366.

E-mail address: mhshyr@gmail.com (M.-H. Shyr).

<http://dx.doi.org/10.1016/j.tcmj.2016.06.004>

1016-3190/Copyright © 2016, Buddhist Compassion Relief Tzu Chi Foundation. Published by Elsevier Taiwan LLC. This is an open access article under the CC BY-NC-ND license (<http://creativecommons.org/licenses/by-nc-nd/4.0/>).

available in their institution, and should always anticipate the next step should airway management go awry.

Since our introduction of the TVI stylet for tracheal intubation [6], it has been widely used in clinical practice for normal and emergency airways [7]. It can also be used for double lumen [8], nasal [9], and awake [10] intubations for particularly difficult airways. The aim of this study was to compare tracheal intubation with the TVI stylet with that using the conventional Macintosh laryngoscope by practitioners who are experienced in using a direct laryngoscope but novices to the stylet. We measured and analyzed the time of tracheal intubation (TTI), success rate, and difficulty of tracheal intubation on a manikin with different airway scenarios simulating varying difficulty.

2. Materials and methods

2.1. Participants

Ten anesthesiologists (seven consultants and three senior residents) at a medical center were recruited for this study. They were all experienced with the direct Macintosh laryngoscope but were novices in the use of the TVI stylet for normal or difficult tracheal intubations before the study. Instructions on the use of the stylet were given before the procedure, and all 10 anesthesiologists were given time to practice on the manikin at least 10 times before the study.

2.2. Technical information

Using an airway manikin (Trucorp Airsim Bronchi; Trucorp Ltd., Belfast, Northern Ireland) we simulated four airway scenarios: normal airway, tongue edema (tongue inflated with 50 mL of air), cervical spine immobilization (spine fixed in a neutral position), and tongue edema combined with cervical spine immobilization. In each of the four scenarios, participants were asked to perform a tracheal intubation with an endotracheal tube having 7.0 mm internal diameter (Portex; Smiths Medical, Hythe, UK) through the vocal cords using either a conventional Macintosh laryngoscope with a size 3 blade or the Trachway intubating stylet. In the Macintosh group, a guide stylet (Rusch Inc., Duluth, GA, USA) was preloaded in the endotracheal tube to give it a C-shape curve to facilitate tracheal intubation.

Each participating anesthesiologist was randomly assigned three attempts at tracheal intubation with each device in each scenario. In each scenario, five anesthesiologists intubated the manikin's trachea with the Macintosh laryngoscope (Macintosh group) followed by the Trachway intubating stylet (Trachway group), while the other five intubated the trachea with the Trachway intubating stylet followed by the Macintosh laryngoscope.

Each participating anesthesiologist was allowed a maximum time of 120 seconds for each tracheal intubation attempt. The TTI was defined as the time from insertion of the laryngoscope blade or intubating stylet into the mouth of the manikin until successful tracheal intubation was confirmed by inflation of the lungs. Failed intubation was defined as an intubation exceeding 120 seconds or esophageal intubation. After intubation, the participants were asked to describe the difficulty of intubation on a rating scale graded from 1 (very easy) to 5 (very difficult).

2.3. Statistics

The TTI and success rates were recorded. The TTI was expressed as mean \pm standard deviation, and success rates were expressed as percentages (95% confidence interval). Both were analyzed using Student *t* test. Difficulty ratings were compared using the

Mann–Whitney–Wilcoxon signed-rank test. A *p* value of <0.05 was considered statistically significant.

3. Results

All 10 anesthesiologists completed the study. Their median clinical anesthesia experience was 10.5 years (range 3–21 years). The TTI in the Macintosh group for the normal, tongue edema, cervical spine immobilization, and tongue edema combined with cervical spine immobilization scenarios were 21.87 ± 1.19 seconds, 24.07 ± 1.58 seconds, 24.67 ± 2.66 seconds, and 26.6 ± 2.77 seconds, respectively. In the Trachway group, TTIs were 21.53 ± 1.19 seconds, 21.6 ± 1.45 seconds, 23.13 ± 3.14 seconds, and 23.73 ± 2.05 seconds, respectively (Fig. 1). The TTI of the Trachway group was significantly shorter in the two scenarios tongue edema and tongue edema combined with cervical spine immobilization as compared with that of the Macintosh group ($p = 0.000126$, $p = 0.003457$, respectively).

Success rates for both devices were 100% in all scenarios. The median difficulty scores and ranges for both devices in the four scenarios are shown in Fig. 2. It was significantly easier to perform tracheal intubation using the TVI stylet than it was using the Macintosh laryngoscope in the simulated tongue edema ($p = 0.031$) and in the combined scenarios ($p = 0.04$).

4. Discussion

The TVI stylet has been widely used in normal and difficult intubations. The learning time is short for novice operators, even for nurses [11] and medical students [12]. Interestingly, however, no previous study has compared its use in different airway conditions. We evaluated its efficiency in tracheal intubation by comparing the TTI, success rates and degrees of intubation difficulty between use of the stylet and the conventional Macintosh laryngoscope. We found that the Macintosh group took more time for tracheal intubation in the tongue edema and combined scenarios than did the TVI stylet group. Our study also proved that experienced anesthesiologists have strong motivation to learn the use of a new tool such as the TVI stylet in managing both anticipated and unanticipated difficult airways. The learning curve for using the stylet for different

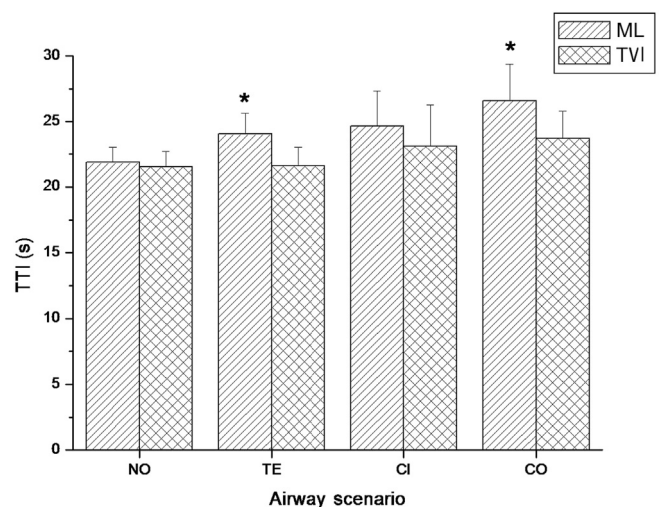


Fig. 1. Time of tracheal intubation (TTI) with the Macintosh laryngoscope (ML) and the Trachway intubating (TVI) stylet in four airway scenarios: normal airway (NO), tongue edema (TE), cervical immobilization (CI), and tongue edema combined with cervical immobilization (CO). The bar and whiskers represent the mean TTI and standard deviation, respectively. *Significant difference between TVI and ML $p < 0.01$.

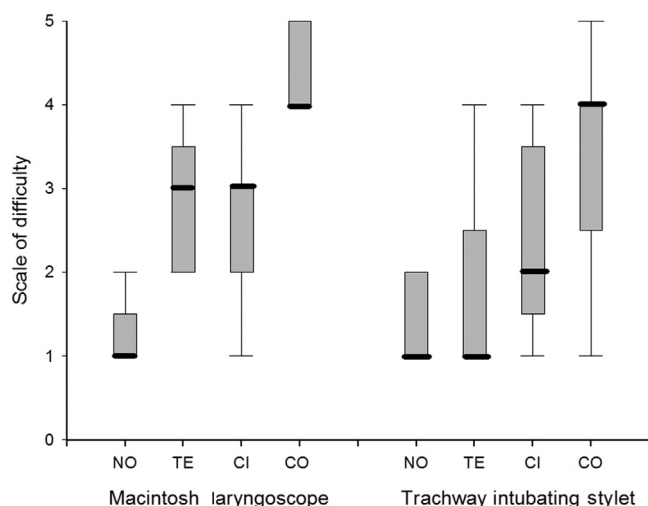


Fig. 2. Difficulty of intubation with the ML and TVI stylet in four airway scenarios using a rating scale of 1 (very easy) to 5 (very difficult). * $p = 0.031$ compared with ML. $^{\dagger}p = 0.04$ compared with ML. ML = Macintosh laryngoscope; TVI = Trachway intubating stylet; NO = normal airway; TE = tongue edema; CE = cervical immobilization; CO = tongue edema combined with cervical immobilization.

types of difficult airway scenarios in manikins was short, requiring only 10 intubations. Participants also felt that tracheal intubations were easier in these two scenarios using the stylet.

The Trucorp Airsim Bronchi manikin was used in the study, as there is evidence of better performance with this manikin compared with other airway simulators [13,14]. Inflation of the tongue was used to simulate disproportion between the tongue and the mandibular space. Neck immobilization simulated clinical cases in which an injured cervical spine is protected against mobilization. In our study, the TTI was longer using the Macintosh laryngoscope as compared with the TVI stylet in the tongue edema and combined scenarios. The participating anesthesiologists also graded intubation scenarios significantly more difficult with the Macintosh laryngoscope than those with the stylet. This difference may be due to the limited space in the oral cavity and oral pharynx, resulting in difficulty in visualization of the vocal cords (line of sight) by direct laryngoscopy [15,16]. This condition may be similar to those encountered with morbidly obese patients whose excessive submandibular soft tissue can obscure direct visualization of vocal cords. In contrast, the TVI stylet enables visualization of laryngeal structures and glottic opening during the entire intubation procedure even in the presence of tongue edema. With visual control from the monitor, the tracheal tube can be directed at and passed through the glottis opening together with the intubating stylet when direct laryngeal exposure by the Macintosh laryngoscope is inadequate.

In this study, we also found that the TTI and degree of intubation difficulty were not statistically different in the normal airway and cervical immobilization scenarios. Compared with other devices such as the lightwand, the TVI stylet may still offer certain potential advantages in clinical practice. It requires an operating maneuver that is similar to that of the lightwand, except that the lightwand involves a blind technique. With a built-in advanced camera and fiber optic system, the stylet provides a view of the larynx and glottis opening that is clear enough for tracheal intubation. Prompt recognition and confirmation of tracheal intubation can be achieved via the camera-monitor system. Additionally, little preparation time or positioning manipulation is needed during intubation with the TVI stylet. With no direct firm contact on oropharyngeal structures, trauma or injuries that might be caused by other

intubation devices can be avoided [17–19]. A previous study by Turkstra et al [20] showed that the use of the lightwand has a TTI that is comparable to that of the Macintosh laryngoscope but is associated with significantly less cervical spine mobilization. The TVI stylet may share the same advantage with the lightwand since they work in almost the same way, with the stylet providing an additional advantage of direct visualization of the pharyngeal inlet. In the present study, the learning experience was easier with the TVI stylet, following a “what-you-see-is-what-you-get” pattern immediately upon identification of the laryngeal structure and glottis opening through the camera system.

In clinical settings, however, the Trachway intubating stylet can be obscured by blood and secretions. As with the flexible fiber optic bronchoscope [21], this may limit its use in conditions such as facial trauma, in which blood and secretions occur frequently in the upper airway. Hence, although nasal intubation is now possible with the Trachway intubating stylet [9] we think it is impractical because of possible nasal trauma.

There were some limitations of this study. First, the use of a manikin in simulating various difficult airway situations may not fully correlate with conditions in clinical patients. Second, all anesthesiologists involved in this study were familiar with the lightwand, making it easier to operate the Trachway intubating stylet without requiring much learning experience.

In conclusion, the TVI may be a useful alternative device for direct visualization in tracheal intubation, especially in cases involving tongue edema or tongue edema combined with cervical spine immobilization, in which direct visualization of the vocal cords cannot be achieved by direct laryngoscopy. The learning time for using the TVI stylet for difficult airway scenarios was short.

References

- [1] Miller RA. The development of the laryngoscope. *Anaesthetist* 1972;21: 145–7.
- [2] Burkle CM, Zepeda FA, Bacon DR, Rose SH. A historical perspective on use of the laryngoscope as a tool in anesthesiology. *Anesthesiology* 2004;100: 1003–6.
- [3] Warner ME, Benenfeld SM, Warner MA, Schroeder DR, Maxson PM. Peri-anesthetic dental injuries: frequency, outcomes, and risk factors. *Anesthesiology* 1999;90:1302–5.
- [4] Hastings RH, Kelley SD. Neurologic deterioration associated with airway management in a cervical spine-injured patient. *Anesthesiology* 1993;78: 580–3.
- [5] Apfelbaum JL, Hagberg CA, Caplan RA, Blitt CD, Connis RT, Nickinovich DG, et al. Practice guidelines for management of the difficult airway: an updated report by the American Society of Anesthesiologists Task Force on management of the difficult airway. *Anesthesiology* 2013;118:251–70.
- [6] Ong J, Lee CL, Lai HY, Lee Y, Chen TY, Shyr MH. A new video intubating device: Trachway® Intubating Stylet. *Anaesthesia* 2009;64:1145.
- [7] Chen JC, Shyr MH. Role of video laryngoscopy in the management of difficult intubations in the emergency department and during prehospital care. *Tzu Chi Med J* 2012;24:100–3.
- [8] Kim YR, Jun BH, Kim JA. The use of the Clarus Video System for double-lumen endobronchial tube intubation in a patient with a difficult airway. *Korean J Anesthesiol* 2013;65:85–6.
- [9] Hsu HT, Lin CH, Tseng KY, Shen YC, Chen CH, Chuang WM, et al. Trachway in assistance of nasotracheal intubation with a preformed nasotracheal tube in patients undergoing oral maxillofacial surgery. *Br J Anaesth* 2014;113:720–1.
- [10] Cheng WC, Lan CH, Lai HY. The Clarus Video System (Trachway) intubating stylet for awake intubation. *Anaesthesia* 2011;66:1178–9.
- [11] Hung KC, Tan PH, Lin VC, Wanh HK, Chen HS. A comparison of the Trachway intubating stylet and the Macintosh aryngoscope in tracheal intubation: a manikin study. *J Anesthesia* 2013;27:205–10.
- [12] Tseng KI, Chau SW, Su MP, Shih CK, Lu IC, Cheng KI. A comparison of Trachway intubating stylet and airway scope for tracheal intubation by novice operators: a manikin study. *Kaohsiung J Med Sciences* 2012;28:448–51.
- [13] Cook TM, Green C, McGrath J, Srivastava R. Evaluation of four airway training manikins as patient simulators for the insertion of single use laryngeal mask airways. *Anaesthesia* 2007;62:713–8.
- [14] Jackson KM, Cook TM. Evaluation of four airway training manikins as patient simulators for the insertion of eight types of supraglottic airway devices. *Anaesthesia* 2007;62:388–93.
- [15] Tremblay MH, Williams S, Robitaille A, Drolet P. Poor visualization during direct laryngoscopy and high upper lip bite test score are predictors of

- difficult intubation with the GlideScope videolaryngoscope. *Anesth Analg* 2008;106:1495–500.
- [16] Rose DK, Cohen MM. The airway: problems and predictions in 18,500 patients. *Can J Anesth* 1994;41:372–83.
- [17] Caplan RA, Posner KL, Ward RJ, Cheney FW. Adverse respiratory events in anesthesia: a closed claims analysis. *Anesthesiology* 1990;72:828–33.
- [18] Weber S. Traumatic complications of airway management. *Anesthesiol Clin North America* 2002;20:503–12.
- [19] Cooper RM. Complications associated with the use of the GlideScope videolaryngoscope. *Can J Anesth* 2007;54:54–7.
- [20] Turkstra TP, Craen RA, Pelz DM, Gelb AW. Cervical spine motion: a fluoroscopic comparison during intubation with lighted stylet, GlideScope, and Macintosh laryngoscope. *Anesth Analg* 2005;101:910–5.
- [21] Ovassapian A, Yelich SJ, Dykes MH, Brunner EE. Fiberoptic nasotracheal intubation—incidence and causes of failure. *Anesth Analg* 1983;62:692–5.