




Contents lists available at ScienceDirect

Tzu Chi Medical Journal

journal homepage: www.tzuchimedjnl.com

Case Report

Microfilaria in a thyroid nodule discovered by fine needle aspiration cytology



A. Hakeem*, A. Mahmood

Department of Pathology and Surgery, ESIC Medical College and Mahmood's Surgical Centre, Gulbarga, India

ARTICLE INFO

Article history:

Received 16 July 2014

Received in revised form

22 July 2014

Accepted 25 July 2014

Available online 6 October 2014

Keywords:

Fine needle aspiration cytology

Microfilaria

Thyroid gland

ABSTRACT

Filariasis is a major health problem in tropical countries, including India. The disease is endemic all over India, especially in Uttar Pradesh, Andhra Pradesh, Orissa, Bihar, Jharkhand, Tamil Nadu, Kerala, and Gujarat. A heavy parasitic load may appear in the blood, urine with chyle, and at times in scrotal aspirates. It is very unusual to find microfilaria in thyroid aspirate. Here, we present a rare case in which microfilaria was found during fine needle aspiration cytology of a solitary thyroid nodule.

Copyright © 2014, Buddhist Compassion Relief Tzu Chi Foundation. Published by Elsevier Taiwan LLC. This is an open access article under the CC BY-NC-ND license (<http://creativecommons.org/licenses/by-nc-nd/4.0/>).

1. Introduction

Filariasis is a common public health problem in Southeast Asia. Approximately 60 million people are infected in this region and approximately 31 million people have clinical manifestations of this disease. Filariasis in India is caused by two closely related nematode worms – *Wuchereria bancrofti* and *Brugia malayi*. The disease mainly involves the lymphatic system of the body [1], with a predilection for the lower limbs, retroperitoneal tissues, spermatic cord, and epididymis. Filariasis can affect other sites on rare occasions. Single cases or a small number of cases of microfilaria have been reported at various sites such as the lymph nodes, breast lumps, bone marrow bronchial aspirate, pleural fluid, ovarian cyst fluid, and a cervicovaginal smear. There are only nine available case reports of microfilaria of the thyroid [2]. Here, we present a woman with filariasis of the thyroid which was detected by fine needle aspiration cytology of the thyroid gland.

2. Case report

A 35-year-old woman presented with slow painless enlargement of the thyroid gland over a period of 2 years. She lived in a village near Hyderabad. The patient had no other complaints. Her thyroid function was normal. On examination a 4-cm × 3-cm thyroid nodule

was palpable over the right lobe. It was soft to firm, nontender, and moved with swallowing (Fig. 1). The cervical lymph nodes were not palpable. A peripheral blood smear showed a total leukocyte count of 13,200/mL with 76% neutrophils, 20% lymphocytes, and 4% eosinophils. The erythrocyte sedimentation rate was 28 mm/hour.

2.1. Cytological findings

Fine needle aspiration of the thyroid nodule revealed blood-mixed colloid. Slides were stained with Field's and Giemsa stains. A microscopic examination of the smear showed microfilarial larvae in the background of blood mixed-colloid along with a few monolayered clusters of benign follicular cells and macrophages. The microfilariae had a sheath, which projected slightly beyond the body of the larvae. The central axis of the larval body contained nuclei, which appeared as granules, and were absent at the tip of the tail (Figs. 2 and 3). The diagnosis was microfilaria of the thyroid, morphologically consistent with *Wuchereria bancrofti*.

2.2. Treatment and follow up

The patient was given diethyl carbamazepine (DEC) for a period of 6 months. After 2 months follow up, the patient responded well to the treatment and swelling subsided. DEC was continued for 6 months.

3. Discussion

Lymphatic filariasis is a common public health problem in tropical and subtropical countries including parts of Latin America,

Conflicts of interest: none.

* Corresponding author. C/O Abdul Azeem Attar, Shameem Masala Attar Bazar, Gulbarga 585101 Karnataka, India. Tel.: +91 9844586236.

E-mail address: attar.hakeem@gmail.com (A. Hakeem).

<http://dx.doi.org/10.1016/j.tcmj.2014.07.007>

1016-3190/Copyright © 2014, Buddhist Compassion Relief Tzu Chi Foundation. Published by Elsevier Taiwan LLC. This is an open access article under the CC BY-NC-ND license (<http://creativecommons.org/licenses/by-nc-nd/4.0/>).

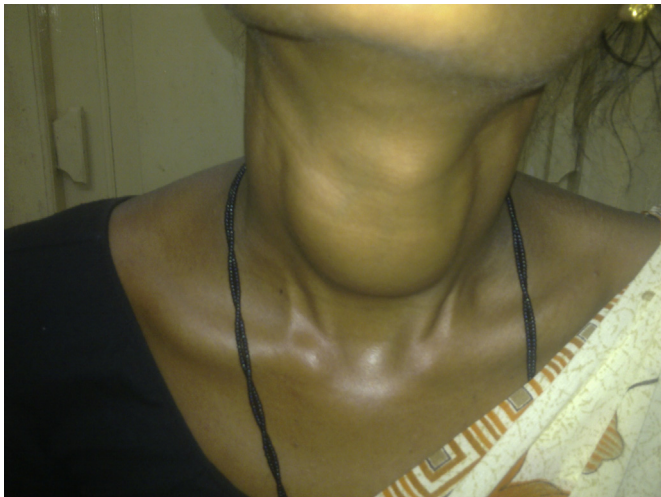

Fig. 1. Photograph of a 4-cm × 3-cm thyroid nodule: soft to firm and nontender which moves with swallowing.

Sub-Saharan Africa and Southeast Asia. It is estimated that approximately 600 million people live in areas endemic for lymphatic filariasis in Southeast Asia. Filariasis is transmitted by the *Culex* mosquito. Two closely related nematodes, *Wuchereria bancrofti* and *Brugia malayi*, are responsible for 90% and 10% of cases, respectively, of the 90 million infections worldwide. Adult worms live in the lymphatic vessels of the definitive host and microfilariae are released and circulate in the peripheral blood. Filariasis causes a spectrum of diseases, including asymptomatic microfilaremia, acute lymphangitis and lymphadenitis, chronic lymphadenitis, edema of the limbs and genitalia, and tropical pulmonary eosinophilia [3]. Filariasis is a global problem and it is also a major health problem in India. Our patient presented in an euthyroid state similar to the findings of Kundu et al, and Kar et al. As with our patient, microfilaria was not suspected in any of the previously

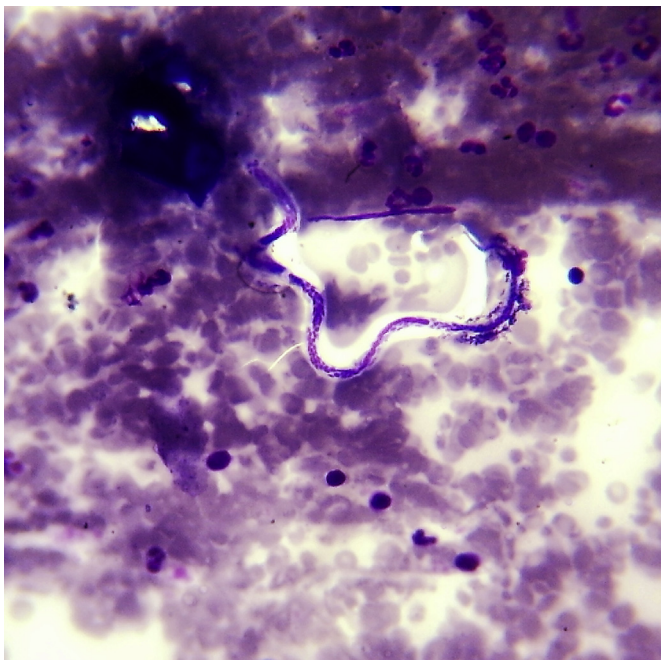


Fig. 2. Photomicrograph of microfilaria in a colloid background (May Grunwald Giemsa (MGG), 400×).

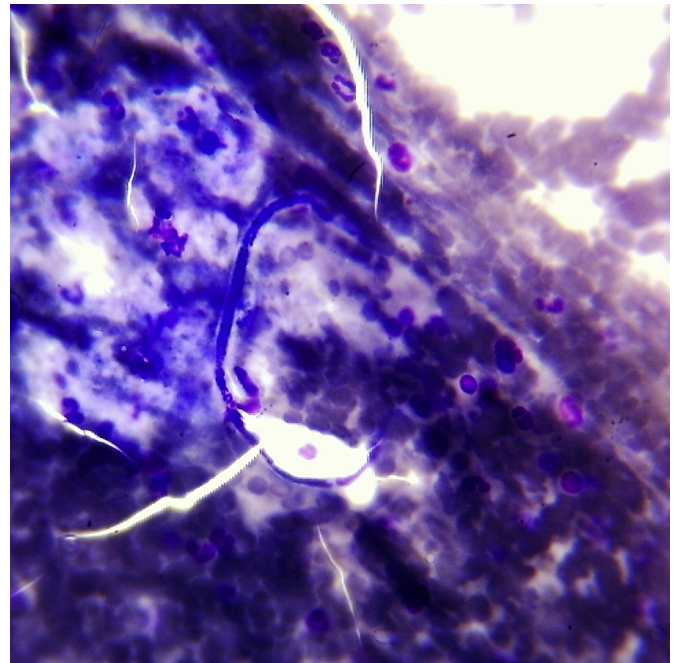


Fig. 3. Photomicrograph of microfilaria with background showing scattered thyroid follicular cells (May Grunwald Giemsa (MGG), 400×).

reported cases and fine needle aspiration cytology was performed for the diagnosis of other primary lesions [2]. Our patient also presented with asymptomatic thyroid swelling, similar to the findings noted by Mohanti et al and Vergese et al [2]. Lymphatic filariasis is a major health problem in tropical countries including India. Due to nocturnal periodicity of species endemic in India, it is difficult to find microfilaria in blood and fine needle aspirates despite its high incidence in this zone. So far about nine cases describing microfilaria in thyroid aspirates have been reported in literature [4]. Various species of microfilaria may be differentiated from each other due to their distinct morphology. There are three sheathed species of microfilariae: *Wuchereria bancrofti*, *Brugia malayi*, *Loa loa*. In India microfilariae bancrofti and microfilariae malayi are the commonly prevalent species [5]. Kundu et al. have also described a similar case in a 38 year old female who also presented with a solitary thyroid nodule, aspirate of which revealed microfilaria, few histiocytes and lymphocytes. There was no associated thyroid lesions and the nodule resolved after treatment with DEC [1].

4. Conclusion

Filariasis of the thyroid is an uncommon condition and requires a high index of suspicion and careful screening of fine needle aspiration smears, especially in asymptomatic patients living in endemic zones.

References

- [1] Chowdhary M, Langer S, Aggarwal M, Agarwal C. Microfilaria in thyroid gland nodule. *Indian J Pathol Microbiol* 2008;51:94–6.
- [2] Mondal RK, Ray R, Kawsar H, Ali MS. A rare case of microfilaria in thyroid aspirate. *Bangladesh J Med Sci* 2014;13:99–100.
- [3] Shastry S. Microfilaria in thyroid aspirate - an unusual finding. *Thyroid Res Pract* 2014;11:26–8.
- [4] Gangopadhyay M, Biswas B, Chowdhury M. Microfilaria in thyroid aspirate - an unexpected finding. *J Cytol* 2011;28:240–1.
- [5] Maheshwari V, Khan L, Mehdi G. Microfilaria in thyroid aspiration smear - an unexpected finding. *Diagn Cytopathol* 2007;36:40–1.