

Case Report

Orbital sarcoidosis

Yi-Ching Lee ^a, Tzu-Lun Huang ^b, Rong-Kung Tsai ^{c, d, *}^a Department of Ophthalmology, Buddhist Tzu Chi General Hospital, Hualien, Taiwan^b Department of Ophthalmology, Far Eastern Memorial Hospital, Banqiao, New Taipei City, Taiwan^c Institute of Eye Research, Buddhist Tzu Chi General Hospital, Hualien, Taiwan^d Institute of Medical Sciences, Tzu Chi University, Hualien, Taiwan

ARTICLE INFO

Article history:

Received 22 February 2014

Received in revised form

10 March 2014

Accepted 19 April 2014

Available online 13 June 2014

Keywords:

Eyelid sarcoidosis

Noncaseating granuloma

Orbital sarcoidosis

ABSTRACT

We report a 50-year-old woman with orbital sarcoidosis. The initial presentation was painless swelling in the upper eyelid and mildly limited extraocular motion. A heterogeneous mass with a surrounding bony defect was noted on an orbital computerized tomography scan. Histopathological examination revealed noncaseating granulomas, which were compatible with a diagnosis of sarcoidosis. Elevation of the serum angiotensin-converting enzyme level and mediastinal lymphadenopathy, found on chest computerized tomography, also confirmed the diagnosis. The patient was treated with low-dose corticosteroids for 5 weeks and showed a favorable outcome.

Copyright © 2014, Buddhist Compassion Relief Tzu Chi Foundation. Published by Elsevier Taiwan LLC. All rights reserved.

1. Introduction

Sarcoidosis is a multisystem disease of unknown cause, which is characterized histopathologically by noncaseating granulomas. Ocular involvement varies with race and sexes, and is seen in approximately 25% of patients [1]. The most common ocular manifestation is uveitis [2]; orbital sarcoidosis is uncommon, and a few series have been reported in the literature [3–5]. We present a case of orbital sarcoidosis.

2. Case Report

A 50-year-old woman presented with painless left eyelid swelling for 1 month. She had no systemic diseases and no recent trauma history. On examination, her best-corrected visual acuity was 20/20 and intraocular pressures were within the normal limits in both eyes. Slit-lamp and fundus examinations revealed no abnormalities. The upper eyelid of the left eye was mildly erythematous and swollen, but not tender. Her extraocular movement showed a slight limitation of supraduction and abduction (Fig. 1). Her pupils were isocoric and reacted promptly to light stimuli.

Prednisolone 25 mg/day for 1 week was prescribed as a treatment trial under the suspicion of an orbital pseudotumor. However, orbital computerized tomography showed a heterogeneous mass with a surrounding bony defect (Fig. 2A), which is not commonly seen in orbital pseudotumors; hence, an incisional biopsy was performed. The tumor was firm, with a cartilage-like consistency. Histopathological findings were diffuse noncaseating granulomas consisting of epithelioid histiocytes and Langhans giant cells (Fig. 3A). Special stains for acid-fast bacilli and fungi were negative (Fig. 3B and C). Her serum angiotensin-converting enzyme level was 25.11 units (normal <22.5 units). A chest radiograph revealed no hilar lymphadenopathy. The patient was reviewed further by a pulmonologist, and enlargement of mediastinal lymph nodes was found on chest computerized tomography (Fig. 2B). A diagnosis of orbital sarcoidosis was made, and she was treated with 10 mg of prednisolone per day for 1 month. The eyelid swelling and limitation of extraocular motion resolved (Fig. 4). She has been followed for 6 months without recurrence.

3. Discussion

Orbital soft tissue involvement is a distinctly uncommon manifestation of sarcoidosis. In one large series of ophthalmic manifestations of sarcoidosis, orbital involvement was seen in two of 202 patients (1%) [3]. Analysis in a recent case series demonstrated that orbital sarcoidosis occurs predominantly in patients older than 50 years and is more common in women [6]. The unique clinical presentation in our case was the bony defect on the

Conflicts of interest: None.

* Corresponding author. Institute of Eye Research, Buddhist Tzu Chi General Hospital, 707, Section 3, Chung-Yang Road, Hualien, Taiwan. Tel.: +886 3 8561825; fax: +886 3 8577161.

E-mail address: rksai@tzuchi.com.tw (R.-K. Tsai).

<http://dx.doi.org/10.1016/j.tcmj.2014.05.005>

1016-3190/Copyright © 2014, Buddhist Compassion Relief Tzu Chi Foundation. Published by Elsevier Taiwan LLC. All rights reserved.

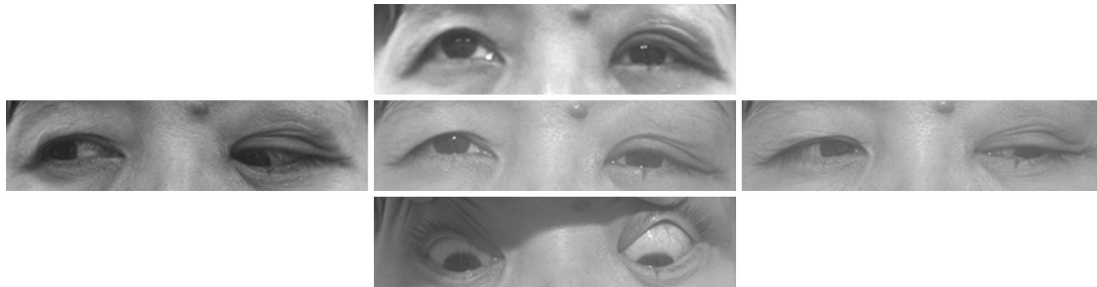


Fig. 1. Initial extraocular presentation. Mild redness and swelling are present in the left upper eyelid. Note that the left eye is mildly displaced inferiorly. There are limitations of upward and left gaze.

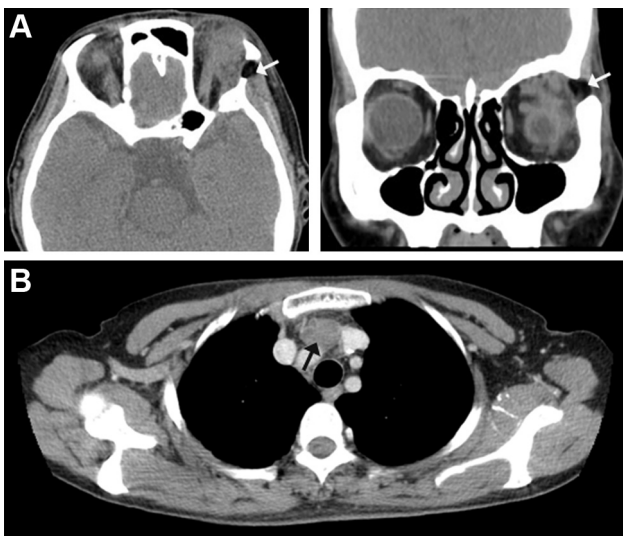


Fig. 2. (A) Orbital CT. A left orbital lesion with bony defect is seen on the CT scan (white arrow). (B) Chest CT. An enlarged mediastinal lymph node is noted (black arrow). CT = computerized tomography.

computerized tomography scan. The potential risk of bone erosion has not been mentioned in previous reports. This image could lead clinicians to consider the lesion a malignancy, such as adenoid cystic adenocarcinoma of the lacrimal gland, and a biopsy is mandatory to confirm the diagnosis. Another distinct point in our case was the rapid response to low-dose corticosteroids. Oral steroids have been the mainstay of treatment in these patients, and most reported cases have shown a good response. In cases without an active systemic disease, a short course of oral prednisolone, starting at 1 mg per kilogram of body weight and tapering over 3 months, may be considered as an initial therapy for orbital sarcoidosis [6,7]. In localized orbital disease, periocular injections of steroids may be an alternative treatment [8]. Other treatments

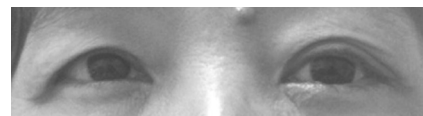

Fig. 4. Clinical picture after steroid treatment. The left eye is in a normal position without displacement compared with that in Fig. 1. Eyelid swelling has resolved.

include surgical excision of the lesion, or observation alone. In a case series, the lesions regressed in 43% of patients with orbital sarcoidosis treated with observation alone, and the response to excisional biopsy and corticosteroid therapy were 88% and 73%, respectively [9]. We could not rule out a natural course of spontaneous regression in our case, and it could be the reason why she had a good response even to low-dose, short-duration corticosteroid treatment. Further large-scale studies are necessary to provide sufficient data on the natural history and standard treatment of orbital and adnexal sarcoidosis.

References

- [1] Newman LS, Roses CS, Maier LA. Sarcoidosis. *New Engl J Med* 1997;336:1224–34.
- [2] Bradley D, Baughman RP, Raymond L, Kaufman AH. Ocular manifestations of sarcoidosis. *Semin Respir Crit Care Med* 2002;23:543–8.
- [3] Obenaus CD, Shaw HE, Sydnor CF, Klintworth GK. Sarcoidosis and its ophthalmic manifestations. *Am J Ophthalmol* 1978;86:648–55.
- [4] Collison JM, Miller NR, Green WR. Involvement of orbital tissues by sarcoid. *Am J Ophthalmol* 1986;102:302–7.
- [5] Jabs DA, Johns CL. Ocular involvement in chronic sarcoidosis. *Am J Ophthalmol* 1986;102:297–301.
- [6] Prabhakaran VC, Saeed P, Esmaeli B, Sullivan TJ, McNab A, Davis G, et al. Orbital and adnexal sarcoidosis. *Arch Ophthalmol* 2007;125:1657–62.
- [7] Marchell RM, Judson MA. Cutaneous sarcoidosis. *Semin Respir Crit Care Med* 2010;31:442–51.
- [8] Goldberg RA. Orbital steroid injections. *Br J Ophthalmol* 2004;88:1359–60.
- [9] Demirci H, Christianson MD. Orbital and adnexal involvement in sarcoidosis: analysis of clinical features and systemic disease in 30 cases. *Am J Ophthalmol* 2011;151:1074–80.

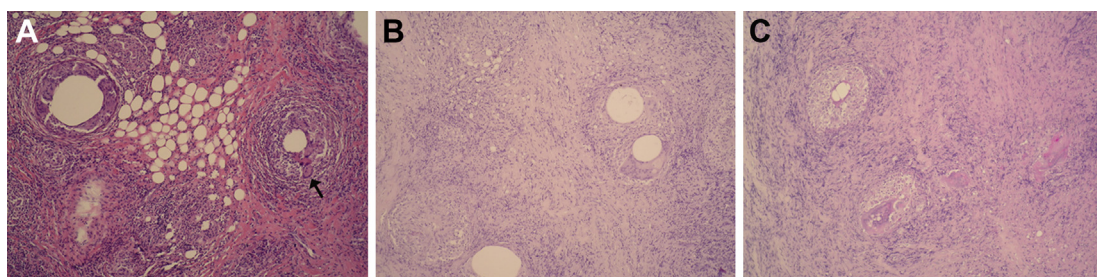


Fig. 3. (A) Histopathological findings. Granulomas consisting of epithelioid cells and Langhans giant cells (arrow) are compatible with the characteristics of sarcoidosis (hematoxylin–eosin, 400×). (B) Negative results of acid-fast stains (400×). (C) Negative results of Periodic Acid-Schiff stain (PAS) (400×).