



## Case Report

## Management of complex open abdominal wounds: Report of two cases

Hwa-Tsung Chen<sup>a,b,\*</sup>, Li-Fu Cheng<sup>a,b</sup><sup>a</sup>Department of Surgery, Buddhist Tzu Chi General Hospital, Hualien, Taiwan<sup>b</sup>School of Medicine, Tzu Chi University, Hualien, Taiwan

## ARTICLE INFO

## Article history:

Received 24 January 2014

Received in revised form

21 February 2014

Accepted 27 February 2014

Available online 16 April 2014

## Keywords:

Abdominal compartment syndrome

Bilateral bipedicle advancement flaps

Open abdomen

Vacuum-assisted closure

## ABSTRACT

This report discusses the successful management of two complex open abdominal wounds. The wounds were temporarily closed with a silastic sheet. After several dressing changes with vacuum-assisted closure (VAC), bilateral bipedicle advancement flaps were used to close the complex open abdominal wound. Case 1: a 41-year-old man underwent gastric bypass surgery for morbid obesity. Wound dehiscence resulted from a sudden increase in intra-abdominal pressure while weaning from mechanical ventilation. The huge open wound was temporarily covered with a silastic sheet. After serial VAC dressing changes, the wound was progressively reduced. The defect was completely repaired using bilateral bipedicle advancement flaps. The skin defects in the lateral abdominal wall were then covered with a split-thickness skin graft. Case 2: a 65-year-old woman underwent emergency surgery for hypovolemic shock from active upper gastrointestinal bleeding. She had a history of three biliary operations for intrahepatic and common bile duct stones. Hemobilia caused by a ruptured intrahepatic pseudoaneurysm was controlled by intraoperative arterial embolization. To prevent abdominal compartment syndrome, the open wound was initially covered with a silastic sheet. The wound was progressively reduced by serial VAC dressing changes. The midline wound was then successfully closed by bilateral bipedicle advancement flaps. After VAC dressing, the skin defects in the lateral abdominal wall were directly closed 2 weeks later. In our experience, a combination of VAC and bilateral bipedicle advancement flaps is effective for the definitive fascia to fascia closure of huge complex open abdominal wounds.

Copyright © 2014, Buddhist Compassion Relief Tzu Chi Foundation. Published by Elsevier Taiwan LLC. All rights reserved.

## 1. Introduction

“Open abdomen” is a strategy used to avoid abdominal compartment syndrome [1,2]. It has become a significant intermediate step in the treatment of abdominal emergencies, including severe abdominal trauma, retroperitoneal hemorrhage, pancreatitis, and severe abdominal sepsis. It has proven effective in reducing mortality and immediate postoperative complications, but it remains a challenging surgical problem with increased late morbidity, such as infection, and enterocutaneous or enteroatmospheric fistula. Various strategies have been proposed to close an

open abdomen, including delayed primary fascia closure, planned ventral hernia [3], component separation [4], a Wittmann patch [5,6], abdominal reapproximation anchoring [7,8], and bilateral bipedicle advancement flaps [9,10]. Each of these strategies has various advantages and disadvantages [11,12].

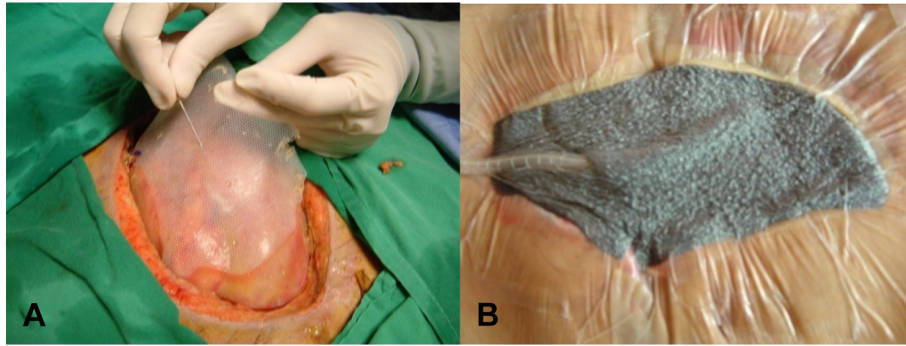
Repeated, tedious abdominal wound dressing changes are usually required to prepare for wound closure before the definitive abdominal wall reconstruction. Negative pressure wound therapy including vacuum pack closure and vacuum-assisted closure (VAC) are currently being used as temporary abdominal closure techniques. These can decrease the frequency of dressing changes and facilitate delayed primary fascia closure [13–15] or enhance secondary fascia closure with a combination of other temporary abdominal closure methods [16–20].

Here, we share our experience in the integration of VAC with bilateral bipedicle advancement flaps to manage two complex open abdominal wounds.

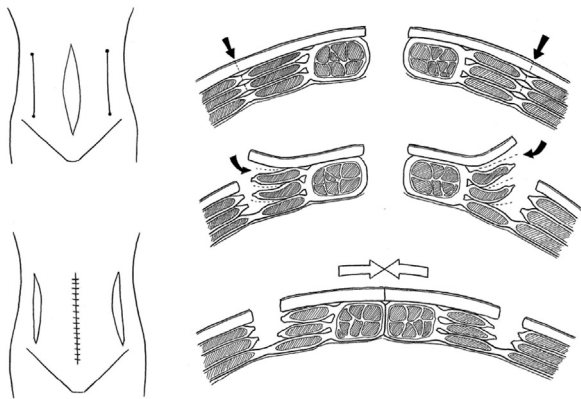
Conflict of interest: none.

\* Corresponding author. Department of Surgery, Buddhist Tzu Chi General Hospital, 707, 3 Section, Chung-Yang Road, Hualien, Taiwan. Tel.: +886 38561825; fax: +886 38577161.

E-mail address: [cht44116@yahoo.com](mailto:cht44116@yahoo.com) (H.-T. Chen).



**Fig. 1.** Case 1: (A) a silo sheath is pierced at multiple sites and used to protect the underlying visceral organs from direct trauma from VAC; (B) the abdominal defect is dressed with a polyurethane sponge and connected to a VAC therapy unit at a negative pressure of approximately 75–125 mmHg. VAC = vacuum-assisted closure.

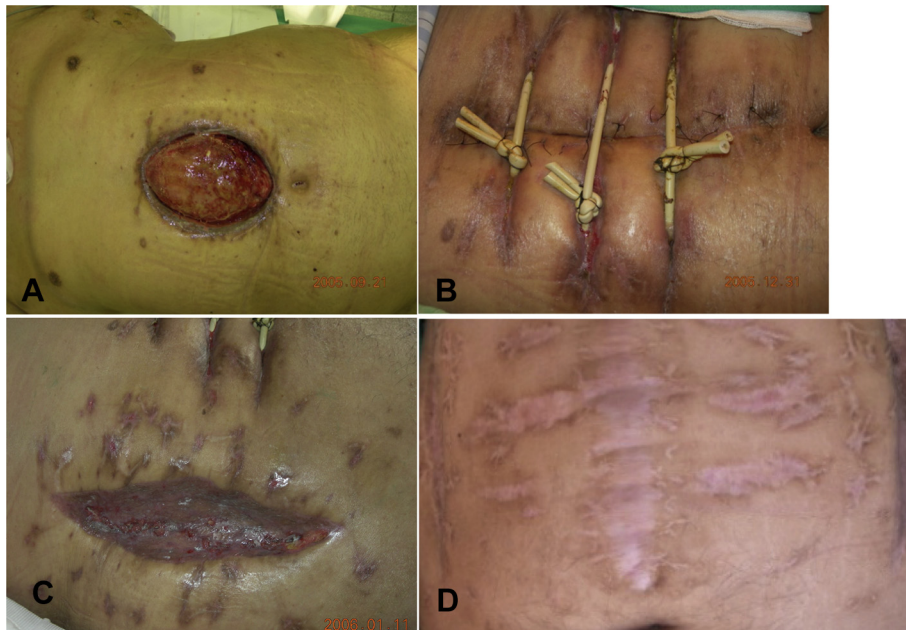


**Fig. 2.** Illustration of the technique used for bilateral bipedicle advancement flaps to close a midline defect.

## 2. Case Reports

### 2.1. Case 1

A 41-year-old man with a body mass index of 53.8 underwent a gastric bypass for morbid obesity. Unfortunately, wound dehiscence and bowel evisceration resulted from a sudden increase in intra-abdominal pressure while weaning from mechanical ventilation. As evisceration and marked swelling of the small bowel hindered primary closure of the abdominal wound, it was initially covered with a silastic sheet and treated with VAC (Fig. 1). VAC dressings were changed twice a week. After 4 weeks of VAC, the abdominal wound was well covered with granulation tissue. Although the defect decreased to 26 × 16 cm<sup>2</sup>, frozen abdomen developed and delayed primary fascia closure could not be achieved by VAC alone. The midline wound was then successfully closed fascia to fascia using bilateral bipedicle advancement flaps (Fig. 2). The skin defects in the bilateral abdominal wall were closed using split-thickness skin grafts (STSGs) (Fig. 3).



**Fig. 3.** Case 1: (A) after 4 weeks of VAC, the abdominal defect is covered with granulation tissue; (B) using bilateral bipedicle advancement flaps, the abdominal defect is closed fascia to fascia with silicon Foley catheter retention sutures; (C) the lateral abdominal wound is repaired using STSGs; (D) after the integration of VAC and bilateral bipedicle advancement flaps, the complex open abdominal wound has completely healed 3 months later. STSGs = split-thickness skin grafts; VAC = vacuum-assisted closure.

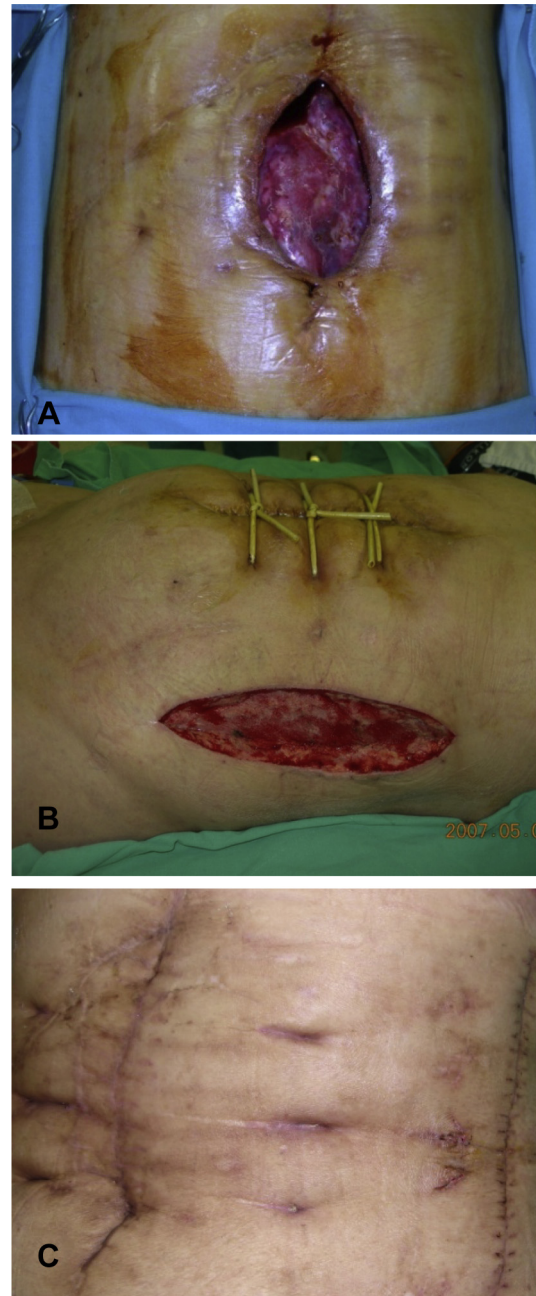
## 2.2. Case 2

A 65-year-old woman with a history of three previous biliary operations for intrahepatic and common bile duct stones, including a choledochoduodenostomy several decades ago, had an emergency laparotomy for hypovolemic shock from active upper gastrointestinal bleeding. During the operation hemobilia was confirmed; it was caused by an intrahepatic pseudoaneurysm that had ruptured into the biliary tract. The bleeding was controlled by intraoperative arterial embolization. After embolization, the intestines became markedly distended and the incisions from the previous operations limited wound closure. The abdominal defect was initially covered with a silastic sheet and dressed with VAC to prevent abdominal compartment syndrome. The VAC dressings were changed twice a week. Three weeks later, the defect had markedly decreased to  $21 \times 15 \text{ cm}^2$  but frozen abdomen developed and the wound could not be directly closed using a component separation technique. Finally, the midline wound was successfully closed using bilateral bipedicle advancement flaps. The skin defects in the bilateral abdominal wall were dressed by VAC and closed directly 2 weeks later (Fig. 4).

## 3. Discussion

Open abdomen management is indicated for patients whose abdomen cannot be closed because of a loss of abdominal wall, such as with necrotizing fasciitis and tertiary peritonitis or bowel edema, and for patients whose abdomen should not be closed, such as those who need damage control surgery or re-exploration in abdominal sepsis, and those with abdominal compartment syndrome. As the abdomen should be kept open in these situations, a temporary abdominal closure device is needed to cover the abdominal defect before the definitive fascia closure. Several temporary abdominal closure techniques have been utilized in the management of open abdomen, including vacuum packs, VAC, artificial burrs (Wittmann patch), dynamic retention sutures, plastic silos (Bogotá bag), mesh/sheets, and skin approximation. Their respective advantages and disadvantages have been well reviewed [20]. With the aid of these temporary abdominal closure devices, the management of open abdomen has evolved from the traditional planned long-term ventral hernia during staged hospitalizations to definitive fascia closure during the initial hospitalization.

At our institution, when a large abdominal defect cannot be closed primarily, it is covered initially with a silastic sheet. The silastic sheet is pierced at multiple sites to allow tissue fluid efflux from this vacuum system (Fig. 1A). Debridement of the necrotic wound is carried out when needed to avoid potential infection. VAC dressings are usually changed twice a week until the defect has reduced markedly and granulation tissue covers the entire wound. The duration and frequency of VAC dressing changes depends on the abdominal pressure and viability of the fascia. After the wound is well prepared, the management of abdominal defects depends on their width. Abdominal defects  $<5 \text{ cm}$  can be closed using delayed primary sutures. A component separation technique can be used to close wounds  $>5 \text{ cm}$  but  $<20 \text{ cm}$ . If the wound is  $>20 \text{ cm}$  and/or frozen, bilateral bipedicle advancement flaps are recommended. With the advancement flap technique, longitudinal incisions are made bilaterally in the abdominal wall from the subcostal region to the lower abdomen along the anterior axillary line. The incision is deepened to the muscle fascia until a midline closure can be achieved without tension (Fig. 2). Silicon Foley catheters (14 Fr) are used for retention sutures (Figs. 3 and 4). The abdominal wound is then closed fascia to fascia with figure-of-eight interrupted "0" Vicryl sutures. Three knots on each retention suture are used to



**Fig. 4.** Case 2: (A) after 3 weeks of VAC, bowel swelling and the abdominal defect are markedly reduce; (B) the abdominal defect is closed fascia to fascia using bilateral bipedicle advancement flaps with silicon Foley catheter retention sutures; (C) the lateral abdominal wounds are directly closed after 1 week of VAC and both midline and lateral abdominal wounds have healed well 6 weeks later. VAC = vacuum-assisted closure.

prevent wound dehiscence. The incisions on the lateral abdominal wall can be closed using STSGs or directly closed after VAC dressing care.

Integrating a silastic sheet in VAC is important because it can protect the intestine from direct trauma from VAC and help prevent bowel evisceration. It provides a smooth and inert surface with minimal to no irritation to the bowel serosa. VAC can decrease bowel edema and reduce the size of the wound [21]. It can reduce bacterial colonization, enhance neovascularization, and increase granulation tissue formation [22]. Recent studies demonstrated that vacuum pack closure or VAC helped achieve delayed primary

abdominal fascia closure rates of up to 33–100% [23,24]. If delayed primary fascia closure cannot be achieved by VAC alone, it can enhance secondary closure of open wounds in combination with an STSG, component separation, a Wittmann patch, abdominal reapproximation anchoring, or bilateral bipedicle advancement flaps. Although several retrospective case control studies and limited prospective data suggest that negative pressure wound therapy may be better than other temporary abdominal closure techniques, clinical evidence is still lacking because of the heterogeneous mix of cases and poor quality of the studies [25]. A randomized control trial protocol to test the validity of this hypothesis was published in 2013 [26]. From our experience, when the initial silastic sheet is too small to cover the entire intestine, the intestine will adhere firmly to the retracted abdominal fascia and become frozen. In this situation, even component separation cannot achieve midline closure. Hence, bilateral bipedicle advancement flaps were selected for wound closure in our cases. We suggest using a larger silastic sheet which can fully cover the intestine to avoid a frozen abdomen.

We used silicon Foley catheters as retention sutures for several reasons. We developed this technique *de novo*. Unlike nylon, a silicon Foley catheter used as a retention suture will not erode the underlying intestine and can avoid a subsequent enterocutaneous fistula. It offers enough strength to allow fascia closure. However, it may cause a seton effect on the abdominal wound. To avoid a serious seton effect, the knots on each silicon Foley catheter retention suture should be loosened every 1–2 weeks starting from the knot next to the abdominal wall.

Midline fascia closure in abdominal defects >20 cm wide is very challenging, even when using the component separation technique [4]. In this situation, a rotational myocutaneous flap or bilateral bipedicle advancement flaps can be used as an alternative method for abdominal wall reconstruction. Bilateral bipedicle flaps were introduced by Sullivan et al [9] for massive abdominal skin-grafted hernias. Guy et al [10] used this technique for one-stage closure in patients with abdominal compartmental syndrome. It allows tension-free fascia to fascia closure.

To avoid a later incisional hernia, synthetic or biological mesh can be applied using either an underlay or onlay technique as an adjunct to delayed primary or secondary abdominal closure. Biological mesh may be preferable in contaminated wounds. The disadvantages of both meshes include a lack of support for dynamic abdominal wall function, recurrence rates of 10–20%, an increased risk of infected mesh, and possible enterocutaneous fistulae.

In our experience, a combination of VAC and bilateral bipedicle advancement flaps seems to be effective for the definitive fascia closure of huge complex open abdominal wounds.

## References

- [1] Smith BP, Adams RC, Doraiswamy VA, Nagaraja V, Seamon MJ, Wisler J, et al. Review of abdominal damage control and open abdomens: focus on gastrointestinal complications. *J Gastrointest Liver Dis* 2010;19:425–35.
- [2] Kirkpatrick AW, Roberts DJ, Waele JD, Jaeschke R, Malbrain ML, De Keulenaer B, et al. Intra-abdominal hypertension and the abdominal compartment syndrome: updated consensus definitions and clinical practice guidelines from the world society of the abdominal compartment syndrome. *Intensive Care Med* 2013;39:1190–206.
- [3] Fabian TC, Croce MA, Pritchard FE, Minard G, Hickerson WL, Howell RL, et al. Planned ventral hernia. Staged management for acute abdominal wall defects. *Ann Surg* 1994;219:643–50.
- [4] Ramirez OM, Ruas E, Dellon AL. “Components separation” method for closure of abdominal-wall defects: an anatomic and clinical study. *Plast Reconstr Surg* 1990;86:519–26.
- [5] Wittman DH. Staged abdominal repair: development and current practice of an advanced operative technique for diffuse suppurative peritonitis. *Acta Chir Austriaca* 2000;32:171–8.
- [6] Weinberg JA, George RL, Griffin RL, Stewart AH, Reiff DA, Kerby JD, et al. Closing the open abdomen: improved success with Wittmann Patch staged abdominal closure. *J Trauma* 2008;65:345–8.
- [7] Verdam FJ, Dolmans DE, Loos MJ, Raber MH, Wit RJ, Charbon JA, et al. Delayed primary closure of the septic open abdomen with a dynamic closure system. *World J Surg* 2011;35:2348–55.
- [8] Haddock C, Konkin DE, Blair NP. Management of the open abdomen with the abdominal reapproximation anchor dynamic fascial closure system. *Am J Surg* 2013;205:528–33.
- [9] Sullivan SR, Engrav LH, Anaya DA, Bulger EM, Foy HM. Bilateral anterior abdominal bipedicle flap with permanent prosthesis for the massive abdominal skin-grafted hernia. *Am J Surg* 2007;193:651–5.
- [10] Guy JS, Miller R, Morris Jr JA, Diaz J, May A. Early one-stage closure in patients with abdominal compartment syndrome: fascial replacement with human acellular dermis and bipedicle flaps. *Am Surg* 2003;69:1025–9.
- [11] Diaz JJ, Dutton WD, Ott MM, Cullinane DC, Alouidor R, Armen SB, et al. Eastern Association for the Surgery of Trauma: a review of the management of the open abdomen — Part 2 “Management of the open abdomen”. *J Trauma* 2011;71:502–12.
- [12] Kaarianinen M, Kuokkanen H. Primary closure of the abdominal wall after “open abdomen” situation. *Scand J Surg* 2013;102:20–4.
- [13] Brock WB, Barker DE, Burns RP. Temporary closure of open abdominal wounds: the vacuum pack. *Am Surg* 1995;61:30–5.
- [14] Barker DE, Kaufman HJ, Smith LA, Ciraulo DL, Richart CL, Burns RP. Vacuum pack technique of temporary abdominal closure: a 7-year experience with 112 patients. *J Trauma* 2000;48:201–6.
- [15] Suliburk JW, Ware DN, Balogh Z, McKinley BA, Cocanour CS, Kozar RA, et al. Vacuum-assisted wound closure achieves early fascial closure of open abdomens after severe trauma. *J Trauma* 2003;55:1155–60.
- [16] Miller PR, Meredith JW, Johnson JC, Chang MC. Prospective evaluation of vacuum-assisted fascial closure after open abdomen: planned ventral hernia rate is substantially reduced. *Ann Surg* 2004;239:608–14.
- [17] Miller RS, Morris Jr JA, Diaz Jr JJ, Herring MB, May AK. Complications after 344 damage-control open celiotomies. *J Trauma* 2005;59:1365–71.
- [18] Cothren CC, Moore EE, Johnson JL, Moore JB, Burch JM. One hundred percent fascial approximation with sequential abdominal closure of open abdomen. *Am J Surg* 2006;192:238–42.
- [19] Carlson GL, Patrick H, Amin AI, McPherson G, MacLennan G, Afolabi E, et al. Management of the open abdomen: a national study of clinical outcome and safety of negative pressure therapy. *Ann Surg* 2013;257:1154–9.
- [20] Kreis BE, de Mol van Otterloo AJ, Kreis RW. Open abdomen management: a review of its history and a proposed management algorithm. *Med Sci Monit* 2013;19:524–33.
- [21] Lindstedt S, Hansson J, Hlebowicz J. Comparative study of the microvascular blood flow in the intestinal wall during conventional negative pressure wound therapy and negative pressure wound therapy using paraffin gauze over the intestines in laparotomy. *Int Wound J* 2012;9:150–5.
- [22] Pliakos I, Papavramidis TS, Mihalopoulos N, Koulouris H, Kesisoglou I, Sapalidis K, et al. Vacuum-assisted closure in severe abdominal sepsis with or without retention sutured sequential fascial closure: a clinical trial. *Surgery* 2010;148:947–53.
- [23] Boele van Hensbroek P, Wind J, Dijkgraaf MG, Busch OR, Goslings JC. Temporary closure of the open abdomen: a systematic review on delayed primary fascial closure in patients with an open abdomen. *World J Surg* 2009;33:199–207.
- [24] Roberts DJ, Zygun DA, Grendar J, Ball CG, Robertson HL, Ouellet JF, et al. Negative-pressure wound therapy for critically ill adults with open abdominal wounds: a systematic review. *J Trauma Acute Care Surg* 2012;73:629–39.
- [25] Perez D, Wildi S, Demartines N, Bramkamp M, Koehler C, Clavien PA. Prospective evaluation of vacuum-assisted closure in abdominal compartment syndrome and severe abdominal sepsis. *J Am Coll Surg* 2007;205:586–92.
- [26] Roberts DJ, Jenne CN, Ball CG, Tiruta C, Léger C, Xiao Z, et al. Efficacy and safety of active negative pressure peritoneal therapy for reducing the systemic inflammatory response after damage control laparotomy (the Intra-peritoneal Vacuum Trial): study protocol for a randomized controlled trial. *Trials* 2013;14:141–54.