



Case Report

Panuveitis following administration of quadrivalent human papillomavirus vaccine

Yu-Hung Chen^a, Ying-Hsiu Chang^b, Yuan-Chieh Lee^{c,d,e,*}^a Department of Nuclear Medicine, Buddhist Tzu Chi General Hospital, Hualien, Taiwan^b Department of Emergency, National Taiwan University Hospital, Taipei, Taiwan^c Department of Ophthalmology, Buddhist Tzu Chi General Hospital, Hualien, Taiwan^d Department of Medicine, Tzu Chi University, Hualien, Taiwan^e Department of Ophthalmology, National Taiwan University Hospital, Taipei, Taiwan

ARTICLE INFO

Article history:

Received 21 March 2012

Received in revised form

24 May 2012

Accepted 31 May 2012

Keywords:

Lymphocytic vasculitis

Panuveitis

Quadrivalent human papillomavirus vaccine

ABSTRACT

A 27-year-old woman had acute panuveitis, associated with bilateral knee pain with morning stiffness, erythematous papules on the bilateral anterior legs, vertigo, and hearing impairment 4 days after administration of the third dose of quadrivalent human papillomavirus vaccine (HPV4). The only abnormal laboratory finding was an elevated erythrocyte sedimentation rate. Skin biopsy of the local erythematous papules disclosed septal panniculitis with lymphocytic vasculitis. Complete remission was achieved with oral and topical steroids for 4 months. There was no recurrence in the following 2 years. Ophthalmologists and primary-care physicians should be aware of this possible adverse reaction to HPV4. Copyright © 2012, Buddhist Compassion Relief Tzu Chi Foundation. Published by Elsevier Taiwan LLC. All rights reserved.

1. Introduction

Human papillomavirus (HPV) is a common sexually transmitted infection, and certain high-risk HPV types act as carcinogens causing cervical cancers. Millions of new HPV infections occur annually in United States, and the related cervical cancer is the second most common cancer in women [1]. Vaccination with quadrivalent HPV vaccine (HPV4; Gardasil, Merck & Co., Inc., Whitehouse Station, New Jersey, USA) has been demonstrated to decrease the incidence of HPV-associated anogenital diseases and high-grade cervical lesions [2–5]. The Advisory Committee on Immunization Practices recommends adding HPV vaccine into the adult immunization schedule [6,7]. However, HPV4-related adverse events have been reported, including autoimmune phenomena such as scleroderma and rheumatoid arthritis [8]. One case of HPV4-related uveitis has so far been reported [9]. We report another case of uveitis following administration of HPV4.

2. Case report

A 27-year-old female resident doctor complained of acutely painful, inflamed eyes with floaters, which developed 4 days after

she received the third dose of HPV4. Concomitant symptoms included bilateral knee pain with morning stiffness, erythematous papules on the bilateral anterior legs, vertigo, and hearing impairment. She denied any medication use, recent life changes, or family history of autoimmune disease. She had no adverse effects after the previous two doses of HPV4. On examination, she had a visual acuity of 16/20 in each eye and an intraocular pressure of 6 and 7 mmHg in her right and left eye, respectively. Biomicroscopy revealed ciliary injection, an anterior chamber reaction with cells +++, keratic precipitates, and snowball aggregates of inflammatory cells in the vitreous. Fundus examination showed some flame-shaped hemorrhages, and cotton wool patches in the left eye (Fig. 1A). Leakage from the peripheral retinal vessels was detected on fluorescein angiography (Fig. 1B). Laboratory examination revealed an elevated erythrocyte sedimentation rate (34 mm/h). The complete blood cell count showed no abnormalities. Rapid plasma antigen, *Treponema pallidum* hemagglutination, antinuclear antibody, and rheumatic factor were nonreactive. The human leukocyte antigen B27 was negative. Chest radiography showed no hilar lymphadenopathy. A skin biopsy of the local erythematous papules disclosed septal panniculitis with lymphocytic vasculitis (Fig. 2). Oral prednisolone 1 mg/kg/d, methotrexate 5 mg weekly, and topical betamethasone 1% every 2 hours for 2 weeks were prescribed. Prednisolone was tapered in 4 months. The final visual acuity was 20/15 in both eyes. There was no recurrence of uveitis or other symptoms in the following 2 years.

Conflicts of interest: none.

* Corresponding author. Department of Ophthalmology, Buddhist Tzu Chi General Hospital, 707, Section 3, Chung-Yang Road, Hualien, Taiwan. Tel.: +886 3 8561825; fax: +886 3 8577161.

E-mail address: yuanchieh.lee@gmail.com (Y.-C. Lee).

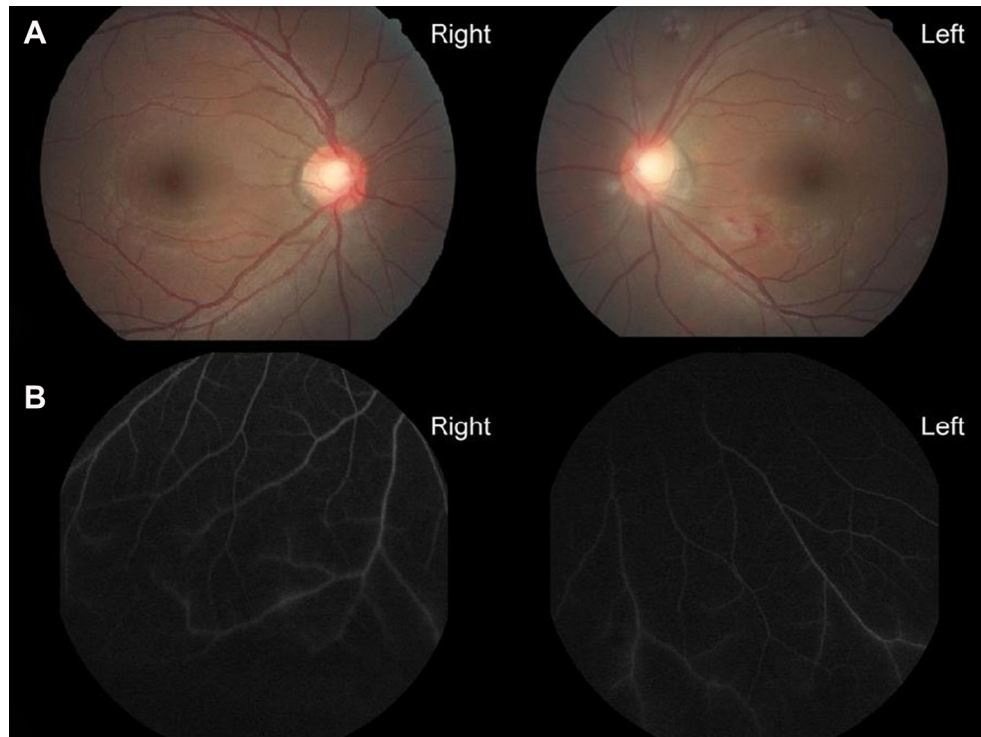


Fig. 1. (A) Fundus examination at presentation (4 days after vaccination) reveals some cotton wool patches with flame-shaped hemorrhages in the left eye. (B) Fluorescein angiography demonstrates leakage from the peripheral retinal vessels in both eyes.

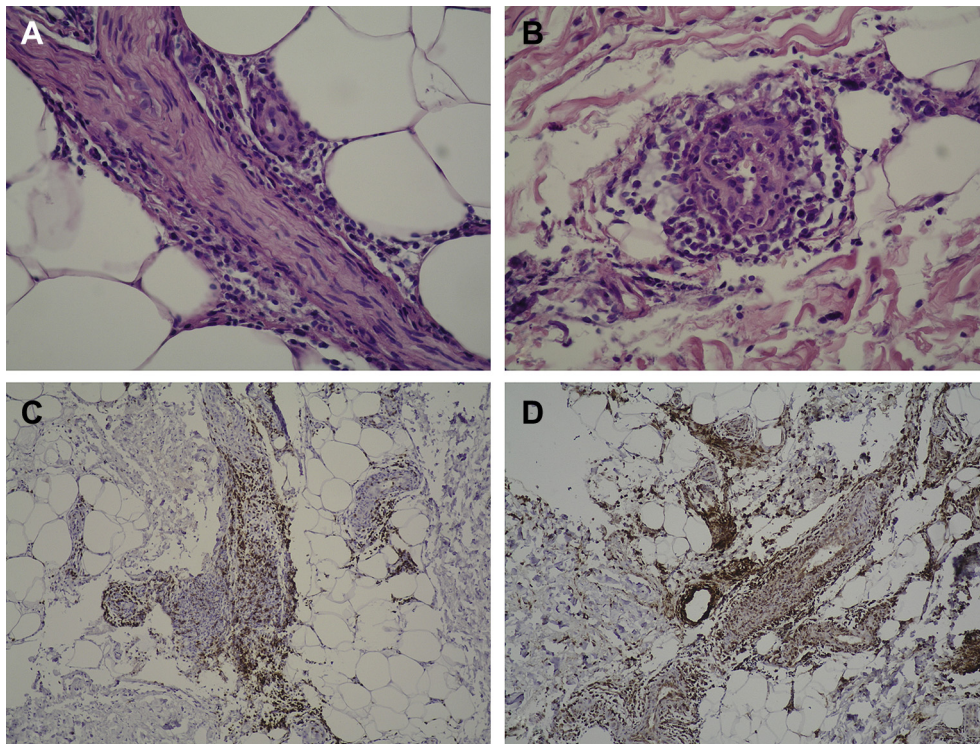


Fig. 2. Pathological examination of a deep skin biopsy shows septal panniculitis with lymphocytic vasculitis (magnification $\times 400$). (A) The septum of the adipose tissue is infiltrated by mononuclear inflammatory cells and lymphoplasmic cells. (B) The arteriole shows intimal hyperplasia with vessel-wall mucinosis. Immunohistochemical staining of the specimen shows many (C) CD3 (+) cells and (D) CD68 (+) cells in the septum and vessel walls.

3. Discussion

There are reports of uveitis associated with various vaccines, including hepatitis B, varicella zoster, meningococcal C conjugated, and Bacille Calmette–Guérin (BCG) vaccines [10–12]. HPV4-related uveitis has been reported only in one case of bilateral ampiginous choroiditis, which was not associated with other systemic manifestations and occurred 3 weeks after HPV4 vaccination [9]. In contrast, our patient had panuveitis, arthritis, panniculitis, and some acoustic symptoms. These adverse effects developed 4 days after vaccination, sooner than that in the previously reported case.

Molecular mimicry and antigenic similarity between proteins from *Mycobacterium tuberculosis* and retinal antigens have been proposed as a potential cause of uveitis elicited by the BCG vaccine [12]. Computer-assisted analysis showed that HPV type16 E7 oncoprotein had a high, widespread similarity to several human proteins involved in critical regulatory processes, and different E7 peptide motifs were present in the same human proteins [13]. While sharing the common motifs between viral proteins and molecules of normal cells might be one cause underlying the scarce immunogenicity of HPV infections [13], the mimicry between proteins in HPV4 and human proteins might be the cause underlying uveitis or other autoimmune reactions elicited by HPV4.

Although direct histopathological study of the ocular tissue was not available, the uveitis in our patient was likely some kind of vasculitis. First, pathological study of the skin biopsy showed intimal proliferation and vessel-wall hyalinization with many monocytes/macrophages and lymphocytes, compatible with lymphocytic vasculitis [14]. Second, the fundus examination demonstrated some cotton wool patches and hemorrhages, consistent with destruction and obliteration of small vessels.

Development of an autoimmune reaction in our patient occurred earlier after vaccination and involved more organs than the previously reported case. This might be due to an older-than-recommended age at vaccination, or an existing HPV infection before vaccination. The suggested age for vaccination is between 9 and 26 years. Vaccination at older ages is not recommended because of possible existing HPV infection. Administration of HPV4 in a patient with pre-existing HPV infection might challenge certain viral antigens similar to self-proteins and thus cause a more severe autoimmune reaction. A recent study [5] in patients with prior infection suggested that natural HPV-infection-elicited antibodies might not provide complete protection against cervical disease over time, while HPV4 prevented reinfection or reactivation

of diseases of the vaccine type. However, vaccine-related adverse experiences were higher.

In summary, the course in this patient suggested an HPV4-related uveitis. Molecular mimicry might lead to systemic autoimmune disorders. Ophthalmologists and primary-care physicians should be aware of this possible adverse reaction, especially in patients older than the recommended age or with possible pre-existing HPV infection.

References

- [1] Weinstock H, Berman S, Cates Jr W. Sexually transmitted diseases among American youth: incidence and prevalence estimates, 2000. *Perspect Sex Reprod Health* 2004;36:6–10.
- [2] FUTURE II Study Group. Quadrivalent vaccine against human papillomavirus to prevent high-grade cervical lesions. *N Engl J Med* 2007;356:1915–27.
- [3] Ault KA, Future II Study Group. Effect of prophylactic human papillomavirus L1 virus-like-particle vaccine on risk of cervical intraepithelial neoplasia grade 2, grade 3, and adenocarcinoma in situ: a combined analysis of four randomised clinical trials. *Lancet* 2007;369:1861–8.
- [4] Garland SM, Hernandez-Avila M, Wheeler CM, Perez G, Harper DM, Leodolter S, et al. Quadrivalent vaccine against human papillomavirus to prevent anogenital diseases. *N Engl J Med* 2007;356:1928–43.
- [5] Olsson SE, Kjaer SK, Sigurdsson K, Iversen OE, Hernandez-Avila M, Wheeler CM, et al. Evaluation of quadrivalent HPV 6/11/16/18 vaccine efficacy against cervical and anogenital disease in subjects with serological evidence of prior vaccine type HPV infection. *Hum Vaccin* 2009;5:696–704.
- [6] Markowitz LE, Dunne EF, Saraiya M, Lawson HW, Chesson H, Unger ER. Centers for Disease Control and Prevention (CDC); Advisory Committee on Immunization Practices (ACIP). Quadrivalent human papillomavirus vaccine: recommendations of the Advisory Committee on Immunization Practices (ACIP). *MMWR Recomm Rep* 2007;56:1–24.
- [7] Centers for Disease Control and Prevention (CDC). Recommendations on the use of quadrivalent human papillomavirus vaccine in males—Advisory Committee on Immunization Practices (ACIP), 2011. *MMWR Morb Mortal Wkly Rep* 2011;60:1705–8.
- [8] Slade BA, Leidel L, Vellozzi C, Woo EJ, Hua W, Sutherland A, et al. Postlicensure safety surveillance for quadrivalent human papillomavirus recombinant vaccine. *JAMA* 2009;302:750–7.
- [9] Khalifa YM, Monahan PM, Acharya NR. Ampiginous choroiditis following quadrivalent human papilloma virus vaccine. *Br J Ophthalmol* 2010;94:137–9.
- [10] Yang DS, Hilford DJ, Conrad D. Acute posterior multifocal placoid pigment epitheliopathy after meningococcal C conjugate vaccine. *Clin Experiment Ophthalmol* 2005;33:219–21.
- [11] Sedaghat M, Zarei-Ghanavati S, Shokoohi S, Ghasemi A. Panuveitis and dermal vasculitis following MMR vaccination. *East Mediterr Health J* 2007;13:470–4.
- [12] Garip A, Diedrichs-Möhring M, Thureau SR, Deeg CA, Wildner G. Uveitis in a patient treated with Bacille–Calmette–Guérin: possible antigenic mimicry of mycobacterial and retinal antigens. *Ophthalmology* 2009;116:2457–62.
- [13] Natale C, Giannini T, Lucchese A, Kanduc D. Computer-assisted analysis of molecular mimicry between human papillomavirus 16 E7 oncoprotein and human protein sequences. *Immunol Cell Biol* 2000;78:580–5.
- [14] Kossard S. Defining lymphocytic vasculitis. *Australas J Dermatol* 2000;41:149–55.