



## Case Report

## Laparoscopic management of a giant adrenal cyst

Yi-Chun Chou<sup>a</sup>, Chih-Wen Lin<sup>b</sup>, Chang-Kuo Wei<sup>c,d</sup>, Jen-En Tseng<sup>d,e</sup>, Kuo-Chih Tseng<sup>a,d,\*</sup><sup>a</sup> Department of Internal Medicine, Buddhist Dalin Tzu Chi General Hospital, Chiayi, Taiwan<sup>b</sup> Department of Medical Imaging, Buddhist Dalin Tzu Chi General Hospital, Chiayi, Taiwan<sup>c</sup> Department of Surgery, Buddhist Dalin Tzu Chi General Hospital, Chiayi, Taiwan<sup>d</sup> School of Medicine, Tzu Chi University, Hualien, Taiwan<sup>e</sup> Department of Pathology, Buddhist Dalin Tzu Chi General Hospital, Chiayi, Taiwan

## ARTICLE INFO

## Article history:

Received 9 March 2012

Received in revised form

16 April 2012

Accepted 2 July 2012

## Keywords:

Adrenal cyst

Adrenalectomy

Laparoscopy

## ABSTRACT

Adrenal cysts, a rare entity, are usually nonfunctional and asymptomatic. Here, we report a 32-year-old woman who presented with mild breathlessness and vague abdominal fullness and discomfort that had lasted 6 months. Chest radiography showed elevation of the left side of the diaphragm. Abdominal sonography showed an anechoic lesion of >15 cm, without a septum, that was situated over the left abdominal area. Abdominal computed tomography (CT) showed a 20 cm suprarenal cyst located between the pancreas, spleen, and left kidney, causing anterior displacement of the pancreas and inferior displacement of the left kidney. Magnetic resonance imaging confirmed the CT and sonographic findings, and revealed that the cystic mass was originating from the left adrenal gland. Fluid analysis of the cystic lesion showed no evidence of infection or malignancy. A laparoscopic adrenalectomy was performed. Histopathologically, the adrenal tissue showed no evidence of adenoma or malignancy, and the cystic component showed a flattened endothelial lining with fibrotic tissue, consistent with an endothelial cyst. The postoperative course was uneventful and the patient had no evidence of recurrence during a 6-year follow-up. We discuss the diagnosis and management of adrenal cysts.

Copyright © 2012, Buddhist Compassion Relief Tzu Chi Foundation. Published by Elsevier Taiwan LLC. All rights reserved.

## 1. Introduction

Adrenal cysts are relatively uncommon and asymptomatic. Their incidence in autopsy studies is approximately 0.064–0.18% [1]. With the advent and widespread use of sonography, computed tomography (CT), and magnetic resonance imaging (MRI), more adrenal cysts are being discovered incidentally. In 1999, Neri and Nance reviewed 613 adrenal cysts and reported that the majority were between 5.1 and 10 cm in size [2]. The management of adrenal cysts depends on size and symptoms, and whether they are functional. When adrenal cysts are larger than 6 cm, symptomatic or functional, or malignancy is suspected, surgical exploration is recommended. Laparoscopic management is a safe and minimally invasive method for adrenal cysts. We report here a case of a giant adrenal cyst that was successfully managed by laparoscopic surgery.

## 2. Case report

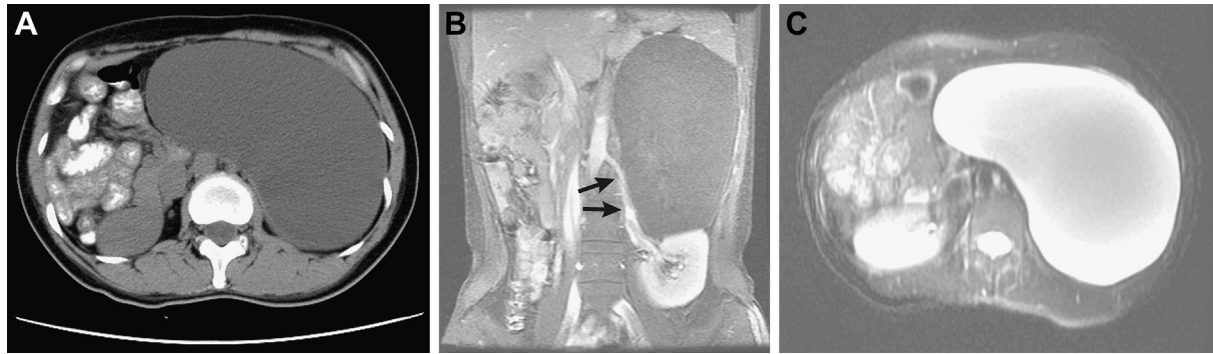
A 32-year-old woman presented with mild breathlessness and vague abdominal fullness and discomfort that had lasted for 6 months. She visited our hospital, where chest radiography showed elevation of the left side of the diaphragm. Abdominal sonography showed an anechoic lesion measuring over 15 cm in diameter, without a septum, that was situated over the left abdominal area. The patient was admitted for further investigation.

On admission, the patient had normal blood pressure and mild abdominal distension without tenderness. Laboratory investigations, including routine blood tests, chemistry, electrolytes, and tumor markers were within normal limits. Abdominal CT showed a 20 cm suprarenal cyst located between the spleen, left kidney, and pancreas (Fig. 1A). MRI revealed a 20 cm × 13 cm × 17 cm left retroperitoneal cyst with anterior displacement of the pancreas and inferior displacement of the left kidney; it was thought to originate from the left adrenal gland (Fig. 1B,C). The diagnosis was a left adrenal cyst. For further management, we inserted a pigtail catheter to drain the cyst. Examination of the cystic fluid showed no evidence of infection or malignancy.

Conflicts of interest: none.

\* Corresponding author. Department of Internal Medicine, Buddhist Dalin Tzu Chi General Hospital, 2, Ming-Shen Road, Dalin, Chiayi, Taiwan. Tel.: +886 5 2648000x5241; fax: +886 5 2648006.

E-mail address: [tsengkuochih@gmail.com](mailto:tsengkuochih@gmail.com) (K.-C. Tseng).



**Fig. 1.** (A) Enhanced abdominal computed tomography shows a huge left suprarenal cyst with thin walls and no septum or calcification, measuring about 20 cm at its largest diameter. The left adrenal gland cannot be identified clearly. (B) Coronal view of a T1-weighted magnetic resonance image shows low signal intensity of the left suprarenal cyst. Note the downward shift of the left renal artery (arrows) due to inferior displacement of the left kidney. (C) Axial view of a T2-weighted magnetic resonance image with fat saturation shows high signal intensity of the left suprarenal cyst, which measures 20 cm × 13 cm × 17 cm.

A laparoscopic adrenalectomy was undertaken after 2 L of cystic fluid had been drained. The operation was performed via a retro-peritoneal approach. The left adrenal gland adhered to the cyst. There were no adhesions between the lesion and the pancreatic tail, spleen, or upper pole of the left kidney. An elastic bag was used to remove the cyst from abdominal cavity. Grossly, the adrenal cyst was a grayish-white, glistening mass of well-circumscribed tissue (Fig. 2A). Histopathologically, the adrenal tissue showed no evidence of adenoma or malignancy. The cystic component showed

a flattened endothelial lining with fibrotic tissue and smooth muscle in the wall (Fig. 2B). Immunohistochemistry staining with CD34 was positive. A diagnosis of adrenal endothelial cyst was made.

The patient was discharged on the 5<sup>th</sup> day after surgery. The postoperative course was uneventful, and the patient remained well without evidence of recurrence during a 6-year follow-up.

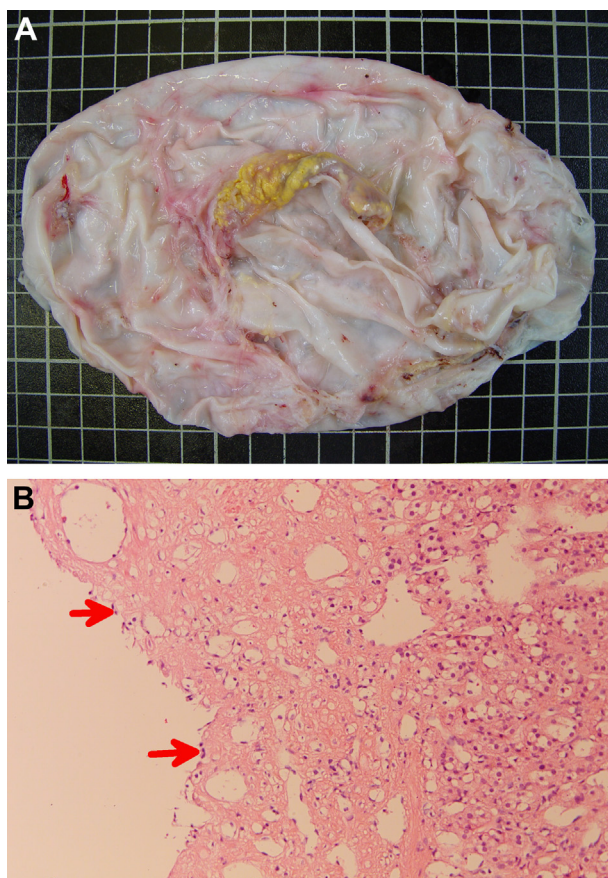
### 3. Discussion

Adrenal cysts are rare entities, with a reported incidence of 0.064–0.18% in autopsy studies [1] and 5–6% in clinical series [3, 4]. However, with the advent and widespread use of sonography, CT, and MRI, more adrenal cysts are being discovered incidentally. Adrenal cysts have been found in patients from the prenatal developmental stages to 86 years old, and peak in the third to sixth decades [2]. They are usually unilateral, have no predilection for either side, and occur more frequently in females, with a 2:1 to 3:1 ratio [4,5]. Most adrenal cysts are between 5.1 and 10 cm, with a mean size of around 9.6 cm [2]. The largest cyst to date, 50 cm in diameter, was reported by Esquivel and Grabstald [6]. In our case, the adrenal cyst was 20 cm in diameter, which is classified as a giant adrenal cyst.

Adrenal cysts are usually asymptomatic. Characteristically, the symptoms are vague and nonspecific. The three most prominent clinical features are dull pain in the adrenal area, gastrointestinal symptoms, and a palpable mass. Additionally, infection, intracystic hemorrhage, and hypertension have been reported [7–9]. The mechanism of adrenal cyst-associated hypertension is probably through the pressure that the cyst exerts on the renal tissue and its vasculature. Amelioration of high blood pressure has been noted after removal of an adrenal cyst [9].

Another condition associated with adrenal cyst-associated hypertension is cystic pheochromocytoma [10]. Clinically, our patient did not have episodic headache, sweating, tachycardia, or hypertension; therefore, cystic pheochromocytoma was not favored. However, because cystic pheochromocytoma may not present with the classic symptoms and a subclinical functional adrenal tumor is not uncommon, a 24-hour urine vanillylmandelic acid or fractionated metanephrine level should be obtained before surgery to exclude this possibility.

A diagnosis of adrenal cyst begins with a careful history and physical examination to determine whether the patient is presenting with signs and symptoms or whether a cyst has been discovered incidentally. With the advanced development of imaging, sonography, and CT, it is possible to differentiate cystic



**Fig. 2.** (A) The adrenal cystic mass is a grayish-white, glistening well-circumscribed structure measuring 18 cm × 11.5 cm × 2 cm. (B) Microscopically, the cystic wall shows a flattened endothelial lining (arrows) with fibrotic tissue and some normal residual adrenal tissue (right).

lesions from solid masses. MRI has advantages over CT and sonography by virtue of its ability to display coronal and sagittal projections that can determine the origin of the retroperitoneal cyst, especially for a giant cyst [11]. MRI has also been reported to have greater specificity because of its ability to differentiate among nonfunctional tumors, functional tumors, metastases, simple cysts, and intra-adrenal hemorrhage [11]. In our case, we could clearly identify the giant cyst arising from the left adrenal gland, and MRI provided strong confirmation that this was a benign lesion. Adrenal angiography can help to differentiate benign or malignant lesions by demonstrating vascularity, and an adrenal cyst should show as an avascular lesion [12].

Aspiration of an adrenal cyst may help to differentiate its nature. In one report, the sensitivity and specificity of cytology in detecting malignancy were 85% and 100%, respectively [13]. In our case, we drained the cyst with a pigtail catheter initially because of the patient's clinical discomfort and the difficulty of performing an operation in the presence of a huge adrenal cystic lesion. The cytology of the cystic fluid showed no evidence of malignancy.

In 1966, based on Abeshouse et al's report, Foster proposed a pathological classification of adrenal cysts into four categories: epithelial, endothelial, pseudocyst, and parasitic [14,15]. In those studies, endothelial cysts were the most common type (45%), falling into two subtypes—lymphangiomatous and angiomatous. Endothelial cysts are identified based on the endothelial cell lining of the cyst wall. Pseudocysts were the second most common type of adrenal cyst (39%), and these are identified based on a fibrous wall lacking an epithelial or endothelial lining. However, the percentage of pathologic classification of adrenal cysts is different from the one reported in a Japanese series [7]. In Tanuma's series, pseudocysts were the most common type, (62.9%), followed by endothelial cysts (29.6%) and epithelial cysts (7.5%). Nevertheless, Foster's classification does not include all pathological findings. Neri et al collected a total of 613 cases and reclassified cysts into five subcategories, adding the unspecified benign adrenal cyst as an additional category [2]. In their series, pseudocysts were the most common type (56%), followed by endothelial cysts (24%). In our case, the cystic wall had an endothelial lining, consistent with an adrenal endothelial cyst.

Small, asymptomatic, or nonfunctioning adrenal cysts can be followed clinically without intervention. However, when they are over 6 cm in diameter, symptomatic, or functional, or when malignancy is suspected, surgical exploration is recommended. The choices for surgical intervention include open surgery with cyst enucleation, en bloc adrenalectomy, or laparoscopic surgery with cyst decortication and partial or total adrenalectomy [3]. Simple laparoscopic enucleation of the cyst with preservation of the kidney and the adrenal gland is the most favored procedure [16]. However, for potentially malignant or complex adrenal cysts, the operation should be carried out abiding by the principles of surgical oncology. Two reports from Taiwan demonstrated that laparoscopic

management with en bloc excision via a lateral transperitoneal approach is safe and feasible, while maintaining the benefits of minimal invasiveness [17,18].

In our patient, the adrenal cyst was considered benign from clinical manifestations and imaging studies, so we performed pigtail drainage before a definite operation. Furthermore, because of compression by the giant cyst and adherence of the cystic wall to the remnant of a small flattened gland in our case, laparoscopic adrenalectomy was performed smoothly. The minimal invasiveness of the laparoscopic approach for adrenal cysts proved to be a safe procedure with a short operative time, low analgesic requirement, and short hospital stay.

In summary, this is a case of a giant adrenal cyst presenting with nonspecific gastrointestinal symptoms. The preoperative diagnosis was made by CT and MRI. A laparoscopic adrenalectomy was performed without complications. The pathology was consistent with an adrenal endothelial cyst. However, when managing an adrenal cyst, the possibility of cystic adrenal carcinoma and cystic pheochromocytoma should be taken into consideration before surgery.

## References

- [1] Bellantone R, Ferrante A, Raffaelli M, Boscherini M, Lombardi CP, Crucitti F. Adrenal cystic lesions: report of 12 surgically treated cases and review of the literature. *J Endocrinol Invest* 1998;21:109–14.
- [2] Neri LM, Nance FC. Management of adrenal cysts. *Am Surg* 1999;65:151–63.
- [3] Castillo OA, Litvak JP, Kerkebe M, Urena RD. Laparoscopic management of symptomatic and large adrenal cysts. *J Urol* 2005;173:915–7.
- [4] Pradeep PV, Mishra AK, Aggarwal V, Bhargav PR, Gupta SK, Agarwal A. Adrenal cysts: an institutional experience. *World J Surg* 2006;30:1817–20.
- [5] El-Hefnawy AS, El Garba M, Osman Y, Eraky I, El Mekresh M, Ibrahim el-H. Surgical management of adrenal cysts: single-institution experience. *BJU Int* 2009;104:847–50.
- [6] Esquivel Jr E, Grabstald H. Giant adrenal cyst. *J Urol* 1965;94:635–8.
- [7] Tanuma Y, Kimura M, Sakai S. Adrenal cyst: a review of the Japanese literature and report of a case. *Int J Urol* 2001;8:500–3.
- [8] Barki Y, Eilig I, Moses M, Goleman L. Sonographic diagnosis of a large hemorrhagic adrenal cyst in an adult. *J Clin Ultrasound* 1987;15:194–7.
- [9] Chang CC, Wu HP, Chen FW, Hsieh HC. Adrenal cyst associated with hypertension: report of a case. *J Formosan Med Assoc* 1988;87:233–7.
- [10] Bush WH, Elder JS, Crane RE, Wales LR. Cystic pheochromocytoma. *Urology* 1985;25:332–4.
- [11] Pastakia B, Miller I, Wolfman M, Cutler Jr GB, Doppman JL. MR imaging of a large adrenal cyst. *J Comput Assist Tomogr* 1986;10:710–1.
- [12] Huang SP, Chen CC, Li CC, Wu WJ, Chou YH, Huang CH. Adrenal cyst – a case report. *Kaohsiung J Med Sci* 2001;17:156–60.
- [13] Katz RL, Patel S, Mackay B, Zornoza J. Fine needle aspiration cytology of the adrenal gland. *Acta Cytol* 1984;28:269–82.
- [14] Abeshouse GA, Goldstein RB, Abeshouse BS. Adrenal cysts: review of the literature and report of three cases. *J Urol* 1959;81:711–9.
- [15] Foster DG. Adrenal cysts. Review of literature and report of case. *Arch Surg* 1966;92:131–43.
- [16] Tagge DU, Baron PL. Giant adrenal cyst: management and review of the literature. *Am Surg* 1997;63:744–6.
- [17] Hung SF, Chung SD, Chueh SC, Lai MK, Yu HJ. Laparoscopic management of potentially malignant or complex adrenal cysts abiding by the principles of surgical oncology. *J Endourol* 2009;23:107–13.
- [18] Chen CH, Chueh SC. An oval mass in an adrenal cyst mimics malignancy. *Surgery* 2008;143:296–7.