



Case Report

Primary Epstein-Barr virus-associated acute acalculous cholecystitis and Gianotti-Crosti syndrome

Wendy Jie-Ying Wu^{a,*}, Daniel Tsung-Ning Huang^b^a Department of Family Medicine, Buddhist Tzu Chi General Hospital, Taipei Branch, New Taipei City, Taiwan^b Department of Pediatrics, Mackay Memorial Hospital, Taipei, Taiwan

ARTICLE INFO

Article history:

Received 28 February 2012

Received in revised form

13 March 2012

Accepted 28 March 2012

Keywords:

Acalculous cholecystitis

Epstein-Barr virus

Gianotti-Crosti syndrome

ABSTRACT

A 15-year-old boy presented with fever, upper respiratory tract symptoms, cervical lymphadenopathy, and vague abdominal symptoms. Abdominal ultrasound findings were consistent with acute acalculous cholecystitis. Serology was positive for acute Epstein-Barr virus (EBV) infection. The patient recovered and was discharged, but returned 1 week later with an acute, symmetric, papulovesicular exanthem on his forearms and lower legs, which was consistent with Gianotti-Crosti syndrome. Although the latter is not uncommonly associated with EBV infection, acalculous cholecystitis of viral origin is exceedingly rare in children.

Copyright © 2012, Buddhist Compassion Relief Tzu Chi Foundation. Published by Elsevier Taiwan LLC. All rights reserved.

1. Introduction

Epstein-Barr virus (EBV) infections in children are often self-limiting. Rarely, life-threatening complications such as airway obstruction, splenic rupture, and neurological or hematological complications do present [1–5]. The most common presentations in adolescents and young adults are infectious mononucleosis with fever, pharyngitis, cervical lymphadenopathy, splenomegaly, hepatocellular dysfunction, and lymphocytosis [5]. An association between primary EBV infection and acute acalculous cholecystitis has been reported in both children and adults, though it is particularly unusual in the pediatric population [6–13]. All reported cases have demonstrated an uneventful recovery without the need for surgery. Most published reports describe female patients.

EBV infection is known to be associated with Gianotti-Crosti syndrome (GCS), a well-established, acute, self-limiting, common dermatosis that typically presents as an asymptomatic, papulovesicular exanthem of the face, extensor surfaces of the extremities, and sometimes the buttocks [14]. Although initially reported in association with hepatitis B viral infection, it is now more commonly reported in association with EBV infection.

Here, we report the first published case of a teenage boy with acute acalculous cholecystitis and GCS in association with an acute EBV infection.

2. Case report

A 15-year-old Taiwanese boy had complained of an intermittent fever of up to 39°C for 1 week. Several days before the fever began, he developed a severe sore throat. He was seen elsewhere and symptomatically treated for a viral upper respiratory infection. In the week prior to admission, he developed nasal congestion, upper abdominal discomfort, nausea, poor appetite, general malaise, and fatigue. Prior to coming to our hospital, he twice passed a soft acholic stool. There was no significant past medical history, and his immunizations were up to date. He denied a history of trauma, insect bites, animal exposure, or recent travel. The family history was unremarkable, with no history of viral hepatitis or G6PD deficiency.

On examination, the patient was a well-developed Taiwanese teenage boy who appeared lethargic. He was febrile with a temperature of 39.4°C, a pulse rate of 127 beats/minute, a respiratory rate of 25 breaths/minute, and a blood pressure of 133/71 mmHg. His sclerae were anicteric. His pharynx was examined, and bilateral nonexudative tonsillar swelling was noted. Cervical lymphadenopathy consisting of a soft, tender, left submandibular lymph node measuring 2.0 × 3.0 cm was noted. His abdomen was soft and distended with epigastric and right upper quadrant tenderness. An equivocal Murphy's sign seemed to be present. The

* Corresponding author. Department of Family Medicine, Buddhist Tzu Chi General Hospital, Taipei Branch, 289, Jianguo Road, Xindian, New Taipei City, Taiwan. Tel.: +886 2 66289779; fax: +886 2 66289009.

E-mail address: wendeez@gmail.com (W.J.-Y. Wu).

Table 1

Laboratory test values of our 15-year-old patient with primary Epstein-Barr virus infection (normal reference levels in terms of the patient's age group are listed in the square brackets).

	May 15, 2010	May 18, 2010	May 21, 2010	May 24, 2010	May 27, 2010
WBC (count) [4500–13,000]	15,300	—	13,500	—	5500
Neutrophils (%) [34–64]	27	—	24	—	33
Monocytes (%) [3–6]	6	—	13	—	14
Lymphocytes (%) [25–45]	48	—	56	—	43
Atypical lymphocytes (%) [0–8]	16	—	6	—	1
AST (U/L) [15–46]	172	123	73	31	23
ALT (U/L) [8–36]	322	207	142	69	35
GGT (U/L) [2–42]	179	—	—	—	—
Albumin (g/L) [35–55]	34	—	—	—	—
Total bilirubin ($\mu\text{mol/L}$) [0–25.6]	71.8	75.3	35.9	25.6	22.2
Direct bilirubin ($\mu\text{mol/L}$) [0–8.5]	47.9	37.6	18.8	10.3	6.8
PT (s) [12.6–15.7]	12.7	12.5	11.6	—	—
INR	1.25	1.23	1.12	—	—
APTT (s) [26–35]	31.6	30.5	31.2	—	—
Anti-EB-IgM VCA	positive	—	—	—	positive
Anti-EB-IgG VCA	40X+	—	—	—	320X+
Anti-EBV EA IgG Ab	negative	—	—	—	negative
Anti-EBV NA IgG Ab	negative	—	—	—	negative

WBC = white blood cell count; AST = aspartate aminotransferase; ALT = alanine aminotransferase; PT = prothrombin time; INR = international normalized ratio; APTT = activated partial thromboplastin time; VCA = viral capsid antigen; EA = early antigen; NA = nuclear antigen.

liver and spleen were not palpated. The remainder of the physical examination was normal.

Initial laboratory data (Table 1) revealed leukocytosis with lymphocyte predominance and 16% atypical lymphocytes. There was evidence of cholestatic hepatitis, as demonstrated by elevated hepatic enzymes and hyperbilirubinemia. Compared with the normal reference range for the patient's age group, his coagulation

profile was within normal limits. The C-reactive protein level was mildly elevated at 1.53 nmol/L. A throat swab for rapid streptococcal A antigen was negative, and the throat culture results were consistent with normal upper respiratory tract flora. Stool, rotavirus, and routine bacterial cultures were all negative, as were the blood cultures.

Ultrasound of the abdomen indicated severe thickening of the gallbladder wall (maximum diameter: 3.43 mm), pericholecystic fluid, a positive sonographic Murphy's sign, and minimal abdominal ascites. There were no gallstones (Fig. 1). Therefore, acute acalculous cholecystitis was diagnosed.

The patient was empirically treated with ceftriaxone and metronidazole, given intravenous fluids, and instructed to fast for 2 days. By day 3, he was able to tolerate a soft diet without postprandial pain. On the sixth day in the hospital, white-to-yellow exudative tonsillitis developed. The serology results indicated an acute EBV infection (Table 1). Serological examinations for hepatitis A, B, C, and cytomegalovirus were all negative. These findings suggested EBV mononucleosis as the cause of the acute acalculous cholecystitis.

The patient demonstrated an uncomplicated recovery, with gradual improvement in the hemogram, liver enzymes, and total and direct bilirubin levels (Table 1). A repeat abdominal ultrasound administered 1 week after the initial exam indicated hydrops of the gallbladder (long axis dimension: 80.1 mm) with the wall thickness having decreased to 3.0 mm (Fig. 2). Marked splenomegaly was noted during this examination. The patient was discharged after he had been afebrile for 1 week.

One week after discharge, the patient returned to our clinic. He had no abdominal discomfort, but there was a pruritic symmetric papulovesicular skin rash on the extensor surfaces of the forearms, knees, and both lower legs. The presumed diagnosis was EBV-associated GCS. Antihistamines and topical steroid cream were prescribed. A repeat abdominal ultrasound continued to show mild hydrops of the gallbladder with normal wall thickness (Fig. 3). His liver enzyme and bilirubin levels were normal (Table 1). After the patient had convalesced, EBV serology was carried out 2 weeks

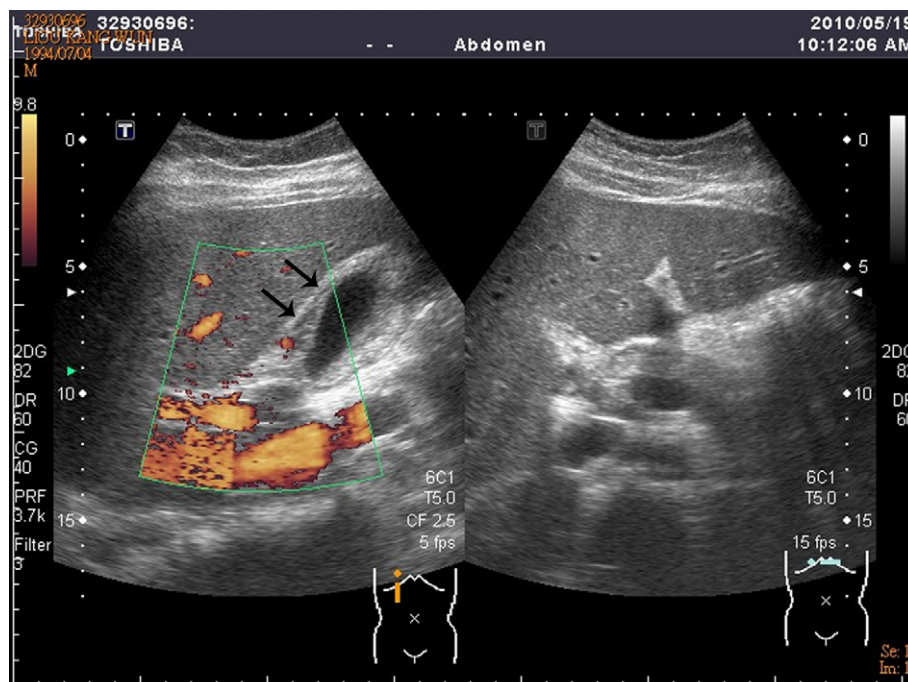


Fig. 1. Longitudinal scan showing gallbladder wall thickening, pericholecystic fluid (arrows), and no evidence of gallstones.

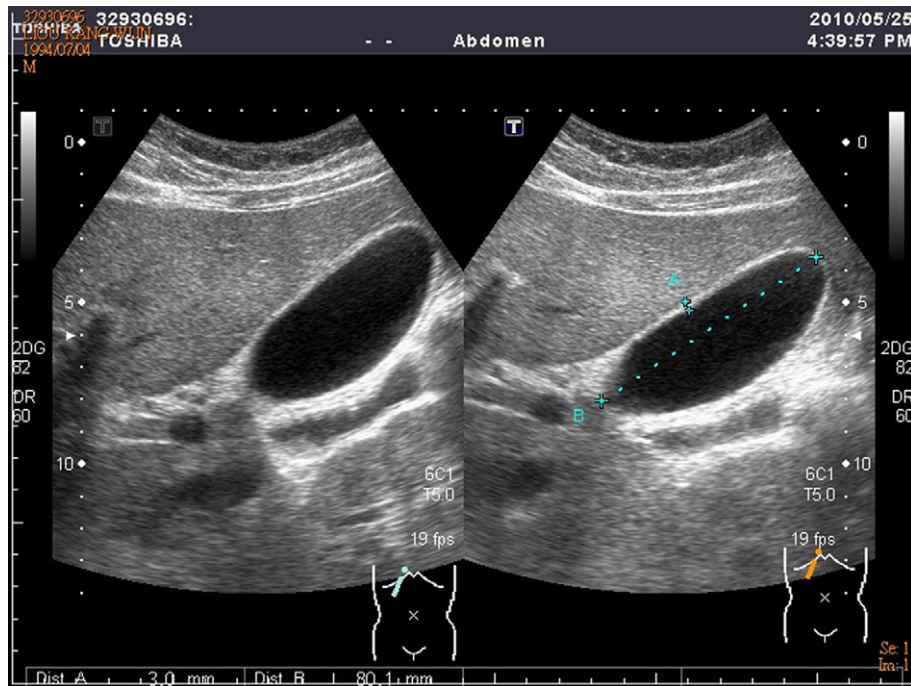


Fig. 2. Repeat abdominal ultrasound 1 week after the initial exam showing hydrops of the gallbladder (Distance B: 80.1 mm) and the resolution of gallbladder wall thickening (Distance A: 3.0 mm).

after the first tests. This showed that EB IgM was positive, EB IgG was strongly positive (320X+), and that both anti-EBV early antigen IgG antibodies and nuclear antigen IgG antibodies were negative, compatible with an acute EBV infection rather than a previous infection. The final diagnosis was acute EBV infection in association with both acute acalculous cholecystitis and GCS.

3. Discussion

This teenage patient was shown to have serologically confirmed primary EBV infection in association with acute acalculous cholecystitis that was resolved with conservative treatment. He then developed GCS, which also resolved. This particular combination of

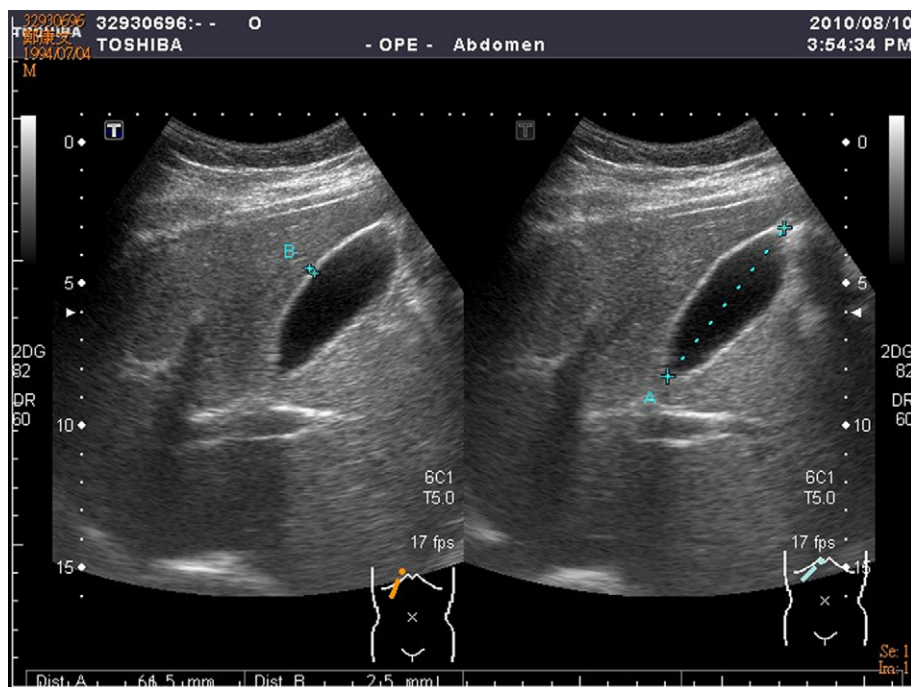


Fig. 3. Subsequent abdominal ultrasound performed at the outpatient department showing normal gallbladder wall thickness (Distance B: 2.5 mm) and mild hydrops of the gallbladder (Distance A: 66.5 mm). No ascites were present.

EBV-associated conditions has not been previously reported in the literature to the best of our knowledge.

Acute acalculous cholecystitis is clinically diagnosed when at least two of the following sonographic criteria are present: gallbladder with a wall thickness of ≥ 3 mm, globular distention of gallbladder, sonographic Murphy's sign, pericholecystic fluid, sludge or intramural gas, and intramural edema [15]. Hydrops of the gallbladder is known to develop occasionally along with EBV infection [16]. Our patient fulfilled the sonographic criteria for acute acalculous cholecystitis, including a thickened gallbladder wall, a positive sonographic Murphy's sign, pericholecystic fluid, and the subsequent development of gallbladder hydrops. The exact pathogenesis of such cases of cholecystitis remains unknown. One suggested mechanism is bile stasis, inducing gallbladder inflammation [17]. Another possibility is the direct invasion of the gallbladder by the virus, as described by Mourani et al in their case of cholecystitis in association with hepatitis A infection [18]. They detected antibodies to hepatitis A virus antigen in the epithelium of the gallbladder. In our patient, the elevated direct and total bilirubin levels and the gamma-glutamyl transferase level were consistent with cholestatic hepatitis, and the subsequent development of gallbladder hydrops suggests bile stasis as a possible mechanism that caused the gallbladder irritation.

Previous case reports of EBV-associated cholecystitis have mostly involved females [6], except for one case where a 5-year-old boy was diagnosed with EBV-associated cholecystitis and Gilbert's syndrome [7]. In the latter case, the patient was diagnosed with unconjugated hyperbilirubinemia, which is characteristic of Gilbert's syndrome together with a homozygous mutation of UGT1A1*28 gene. Unlike the abovementioned young male patient, our male patient was diagnosed with conjugated hyperbilirubinemia, which is consistent with other published cases of EBV-associated cholecystitis [8–13]. As in other reported cases, the cholecystitis resolved spontaneously without surgery. Our patient was empirically treated with antibiotics for 2 weeks, but this treatment should probably have been discontinued once EBV-associated cholecystitis was diagnosed.

The other interesting feature of this case was the diagnosis of GCS. GCS was first described by Gianotti and Crosti in 1953 as monomorphous erythematous acral papular skin lesions in association with viral infection [14]. They called their findings acrodermatitis papulosa eruptiva infantilis. Most patients with GCS are between 3 months and 15 years of age, with a peak in incidence occurring between 1–6 years. In 1970, hepatitis B surface antigen was identified in the serum of affected children [19], but the most commonly identified virus now associated with GCS is EBV [20]. GCS is benign and self-limiting; thus, it usually requires no treatment [14]. However, our patient's rash was pruritic; therefore, we treated him symptomatically.

Our patient was ultimately diagnosed with serologically proven acute EBV infection. An association between EBV infection and GCS is not unusual, but EBV infection and GCS in association with acute

acalculous cholecystitis is very rare. No pathogenic mechanism can explain both conditions occurring in the same patient other than their known association with the virus. Perhaps of more importance than this unusual association is that this case should act as a reminder that acute EBV infection may be associated with a range of secondary abnormalities that are usually, as in the present case, self-limiting.

References

- [1] Glynn FJ, Machle T, Kinsella J. Upper airway obstruction in infectious mononucleosis. *Eur J Emerg Med* 2007;14:41–2.
- [2] Gayer G, Zandman-Goddard G, Kosych E, Apter S. Spontaneous rupture of the spleen detected on CT as the initial manifestation of infectious mononucleosis. *Emerg Radiol* 2003;10:51–2.
- [3] Connelly KP, DeWitt LD. Neurologic complications of infectious mononucleosis. *Pediatr Neurol* 1994;10:181–4.
- [4] Cohen JL. Epstein-Barr virus infections, including infectious mononucleosis. *Harrison's principles of internal medicine*. 16th ed., vol. 1. New York: McGraw-Hill; 2005. p. 165:1046–1049.
- [5] Macsween KF, Crawford DH. Epstein-Barr virus—recent advances. *Lancet Infect Dis* 2003;3:131–40.
- [6] Arya SO, Saini A, El-Baba M, Salimnia H, Abdel-Haq N. Epstein Barr virus-associated acute acalculous cholecystitis: a rare occurrence but favorable outcome. *Clin Pediatr* 2010;49:799–804.
- [7] Attilakos A, Prassouli A, Hadjigeorgiou G, Ladjigeorgiou G, Lagona E, Kitiou-Tzeli S, et al. Acute acalculous cholecystitis in children with Epstein-Barr virus infection: a role for Gilbert's syndrome? *Int J Infect Dis* 2009;13:e161–4.
- [8] Prassouli A, Panagiotou J, Vakaki M, Vakaki M, Giammatou I, Atilakos A, et al. Acute acalculous cholecystitis as the initial presentation of primary Epstein-Barr virus infection. *J Pediatr Surg* 2007;42:e11–3.
- [9] Iaria C, Arena L, Di Maio G, Fracassi MG, Leonardi MS, Famulari C, et al. Acute acalculous cholecystitis during the course of primary Epstein-Barr virus infection: a new case and a review of literature. *Int J Infect Dis* 2008;12:391–5.
- [10] Gora-Gebka M, Liberek A, Bako W, Szarszewski A, Kaminska B, Korzon M. Acute acalculous cholecystitis of viral etiology: a rare condition in children? *J Pediatr Surg* 2008;43:e25–7.
- [11] Chalupa P, Kaspar M, Holub M. Acute acalculous cholecystitis with pericholecystitis in a patient with Epstein-Barr virus infectious mononucleosis. *Med Sci Monit* 2009;15:CS30–3.
- [12] Cholongitas E, Katsogridakis K, Dasenaki M. Acalculous cholecystitis during the course of acute Epstein-Barr virus infection. *Int J Infect Dis* 2009;13:e129–30.
- [13] Koch AD, van den Bosch HC, Bravenboer B. Epstein-Barr virus-associated cholecystitis. *Ann Intern Med* 2007;146:826–7.
- [14] Brandt O, Abeck D, Gianotti R, Burgdorf W. Gianotti-Crosti syndrome. *J Am Acad Dermatol* 2006;54:136–45.
- [15] Imamoglu M, Sarihan H, Sari A, Ahmetoglu A. Acute acalculous cholecystitis in children: diagnosis and treatment. *J Pediatr Surg* 2002;37:36–9.
- [16] Dinulos J, Mitchell DK, Egerton J, Pickering LK. Hydrops of the gallbladder associated with Epstein-Barr virus infection: a report of two cases and review of the literature. *Pediatr Infect Dis J* 1994;13:924–9.
- [17] Barie PS, Eachempati SR. Acute acalculous cholecystitis. *Curr Gastroenterol Rep* 2003;5:302–9.
- [18] Mourani S, Dobbs SM, Genta RM, Tandon AK, Yoffe B. Hepatitis A virus-associated cholecystitis. *Ann Intern Med* 1994;120:398–400.
- [19] De Gaspari G, bardare M, Costantino D. Au antigen in Crosti-Gianotti acrodermatitis. *Lancet* 1970;1:1116–7.
- [20] Hofmann B, Schuppe HC, Adams O, Lenard HG, Lehmann P, Ruzicka T. Gianotti-Crosti syndrome associated with Epstein-barr virus infection. *Pediatr Dermatol* 1997;14:273–7.