



## Clinical Practice and Therapeutics

## Feasibility of genetic testing for tuberous sclerosis in a 13-year-old boy

Chun-Ying Weng<sup>a</sup>, Shao-Yin Chu<sup>a,b,c,\*</sup>, Pei-Chun Lai<sup>a,b</sup>, Lang-Yao Chen<sup>d</sup>,  
Anyi Chen<sup>d</sup>, Yi-Ning Su<sup>d</sup>, Pen-Jung Wang<sup>a,b</sup>

<sup>a</sup> Department of Pediatrics, Buddhist Tzu Chi General Hospital, Hualien, Taiwan

<sup>b</sup> Department of Medicine, Tzu Chi University, Hualien, Taiwan

<sup>c</sup> Department of Medical Education, Buddhist Tzu Chi General Hospital, Hualien, Taiwan

<sup>d</sup> Department of Medical Genetics, National Taiwan University Hospital, Taipei, Taiwan

## ARTICLE INFO

## Article history:

Received 18 October 2011

Received in revised form

28 October 2011

Accepted 3 November 2011

A 13-year-old boy was brought to a genetic counseling clinic for a tuberous sclerosis complex (TSC) gene test by his mother who was affected by TSC. The boy's mother had facial angiofibromas, multiple periungual fibromas, shagreen patches over her lower back, and hypomelanotic macules (ash leaf) over the left side of her waist (Fig. 1). The boy's family history revealed that his 17-year-old brother was also affected by TSC with facial angiofibromas, a left index finger periungual fibroma, shagreen patches over the right lower abdomen, and de-pigmented lesions over the left lower back. Both the mother and the elder brother had their tuberous sclerosis 1 (*TSC1*) gene sequenced directly from peripheral blood leukocyte

DNA. Sequencing revealed a T to C point mutation over the *TSC1* gene at exon 6, codon 482, causing an amino acid change from leucine to proline (*TSC1* c.482 T>C CTG>CCG Leu>Pro) (Fig. 2). High resolution melting (HRM) curve analysis of the *TSC1* gene also revealed a nucleotide T to C mutation in codon 482 (Fig. 3) from the mother and elder brother's peripheral blood leukocyte DNA. This mutated single nucleotide substitution has not been previously reported.

The boy did not have any dermatologic features of TSC and no cardiac murmur was found. In addition, no history of learning disabilities or seizures was reported. Typically, hypomelanotic

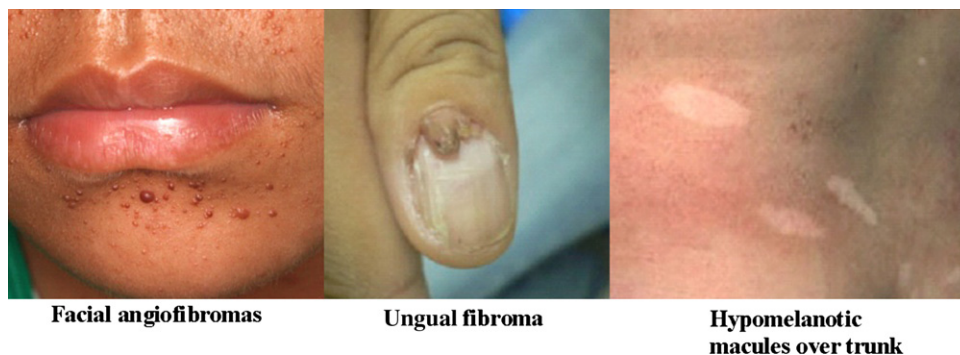
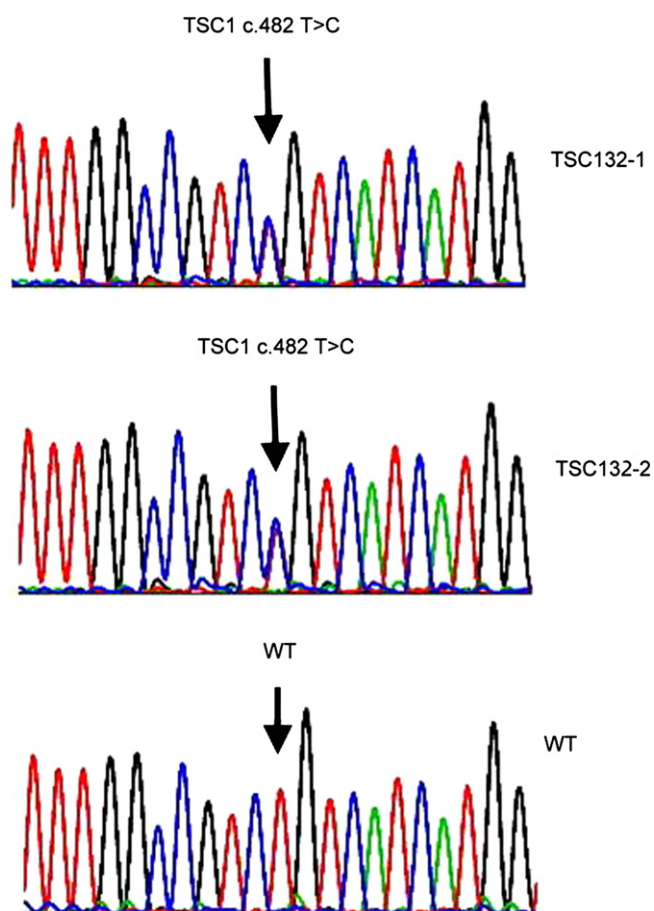


Fig. 1. Dermatological features of tuberous sclerosis complex in the patient's mother.

\* Corresponding author. Department of Pediatrics, Buddhist Tzu Chi General Hospital, 707, Section 3, Chung-Yang Road, Hualien, Taiwan. Tel.: +886 38561825x3649; fax: +886 38563532.

E-mail address: [chu\\_chu@tzuchi.com.tw](mailto:chu_chu@tzuchi.com.tw) (S.-Y. Chu).



**Fig. 2.** Tuberous sclerosis 1 (*TSC1*) gene direct sequencing analysis reveals a T to C point mutation over codon 482 causing an amino acid change from leucine to proline (*TSC1* c.482 T>C CTG>CCG Leu>Pro mutation). WT = wild type; TSC132-1 = mother; TSC132-2 = elder brother.

macules are present at birth in affected individuals and up to 75% of neurocutaneous manifestations, including angiofibromas, occur before the age of nine. Therefore, psychological support was offered to the mother during the genetic counseling process to alleviate her

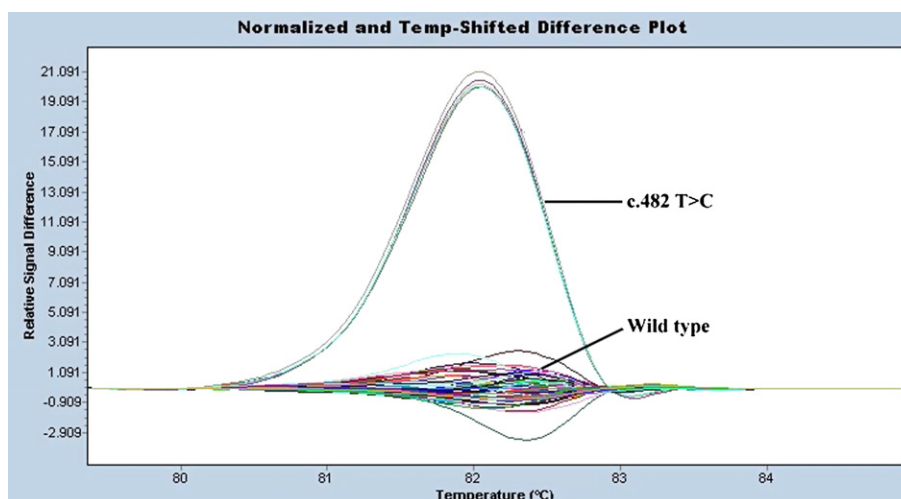
concerns. In addition, genetic counseling for the whole family was encouraged to aid in understanding the clinical characteristics of TSC, disease heritability, and coping strategies for the disease. It was decided that genetic testing would be postponed until the boy reached the age of full decision-making ability.

Recently, tremendous knowledge about molecular genetics has emerged and many genetic testing methods have been rapidly introduced into clinical practice. This change presents many challenges to social policy and to health care ethics. Genetic testing in pediatric patients poses an especially great concern because of the lack of decision-making ability of the patient and parental involvement.

For genetic counseling, the provision of comprehensive information about the disease, the limitations in knowledge, and the available treatment options to the parent is mandatory. It is also important to address the potential psychological harm, stigmatization, and discrimination that acquisition of certain genetic information may cause. The American Academy of Pediatrics does not support the broad use of carrier screening in children and adolescents. In the absence of clearly beneficial treatments or effective preventative methods, it may be preferable to defer genetic testing of children or adolescents. Genetic testing for late-onset genetic disorders should be individualized during the genetic counseling process and should be withheld until adulthood or until mature decision-making capacity has developed. The ethics committee at the specific health care organization may also be consulted in controversial cases.

#### Further reading

- [1] Committee on Bioethics. Ethical issues with genetic testing in pediatrics. *Pediatrics* 2001;107:1451–5.
- [2] Canadian Pediatric Society. Guidelines for genetic testing of healthy children. *Pediatr Child Health* 2003;8:42–52.
- [3] World Health Organization. Review of ethical issues in medical genetics: report of consultants to WHO. 2003;36-7, 58–60.
- [4] Robinson Shenandoah. Neurocutaneous syndromes for pediatric neurosurgery on call: Congress of Neurological surgeons. <http://w3.cns.org/university/pediatrics/ch11.html>; 2011 [accessed 28.08.11].
- [5] Crino PB, Nathanson KL, Henske EP. The tuberous sclerosis complex. *N Engl J Med* 2006;355:1345–56.
- [6] Hung CC, Lin SY, Lee CN, Cheng HY, Lin CY, Chang CH, et al. Identification of fibrillin-1 gene mutations in Marfan syndrome by high-resolution melting analysis. *Anal Biochem* 2009;389:102–6.



**Fig. 3.** High resolution melting (HRM) curve analysis of the tuberous sclerosis 1 (*TSC1*) gene also reveals a nucleotide T to C mutation in codon 482. (Deoxyribonucleic acid (DNA) from both mother and elder brother.)