



## Case Report

## Three cases of successful treatment of granulomatous tenosynovitis

Jui-Teng Chien<sup>a,b</sup>, Fu-Tsung Hsiao<sup>c</sup>, Yu-Chuan Chen<sup>d</sup>, Yu-Hong Chen<sup>b</sup>, Chong-Jang Lay<sup>b,e</sup>, Chen-Chi Tsai<sup>b,e,\*</sup><sup>a</sup> Department of Orthopedics, Buddhist Dalin Tzu Chi General Hospital, Chiayi, Taiwan<sup>b</sup> School of Medicine, Tzu Chi University, Hualien, Taiwan<sup>c</sup> Department of Radiology, Buddhist Dalin Tzu Chi General Hospital, Chiayi, Taiwan<sup>d</sup> Department of Clinical Pathology, Buddhist Dalin Tzu Chi General Hospital, Chiayi, Taiwan<sup>e</sup> Division of Infectious Disease, Department of Medicine, Buddhist Dalin Tzu Chi General Hospital, Chiayi, Taiwan

## ARTICLE INFO

## Article history:

Received 12 May 2011

Received in revised form

1 June 2011

Accepted 22 September 2011

## Key words:

Granuloma

Mycobacterium

Tenosynovitis

## ABSTRACT

Granulomatous tenosynovitis is a rare disease with an indolent, relapsing process, which can be caused by various pathogens. Here, we describe three immunocompetent patients with right wrist granulomatous tenosynovitis. Two cases were attributed to nontuberculous mycobacteria (NTM) infection. In the third case, no definite etiology was found. However, the symptoms and patient history were similar to the other two cases. All three patients were cured by surgical debridement and clarithromycin-based anti-NTM antibiotics.

Copyright © 2011, Buddhist Compassion Relief Tzu Chi Foundation. Published by Elsevier Taiwan LLC. All rights reserved.

## 1. Introduction

Granulomatous tenosynovitis is an indolent, relapsing disease that is difficult to diagnose by inspection alone [1]. It can be caused by infectious etiologies, such as nocardiosis, brucellosis, mycobacteriosis, syphilis, sporotrichosis, coccidioidomycosis, blastomycosis, histoplasmosis, and protothecosis [1–5]; and noninfectious etiologies, including sarcoidosis, crystal-associated diseases, and foreign body reactions [6]. It is a rare disease and sometimes its etiology can not be confirmed. Here, we describe two cases of granulomatous tenosynovitis caused by nontuberculous mycobacteria (NTM) and one case of granulomatous tenosynovitis of unknown etiology. Because the symptoms and history in the third patient were similar to those in the other two cases, he was treated for NTM tenosynovitis and had a favorable outcome.

## 2. Case reports

## 2.1. Case 1

A 67-year-old man was admitted because of a tender, swollen right wrist. He reported that the condition had developed about 1

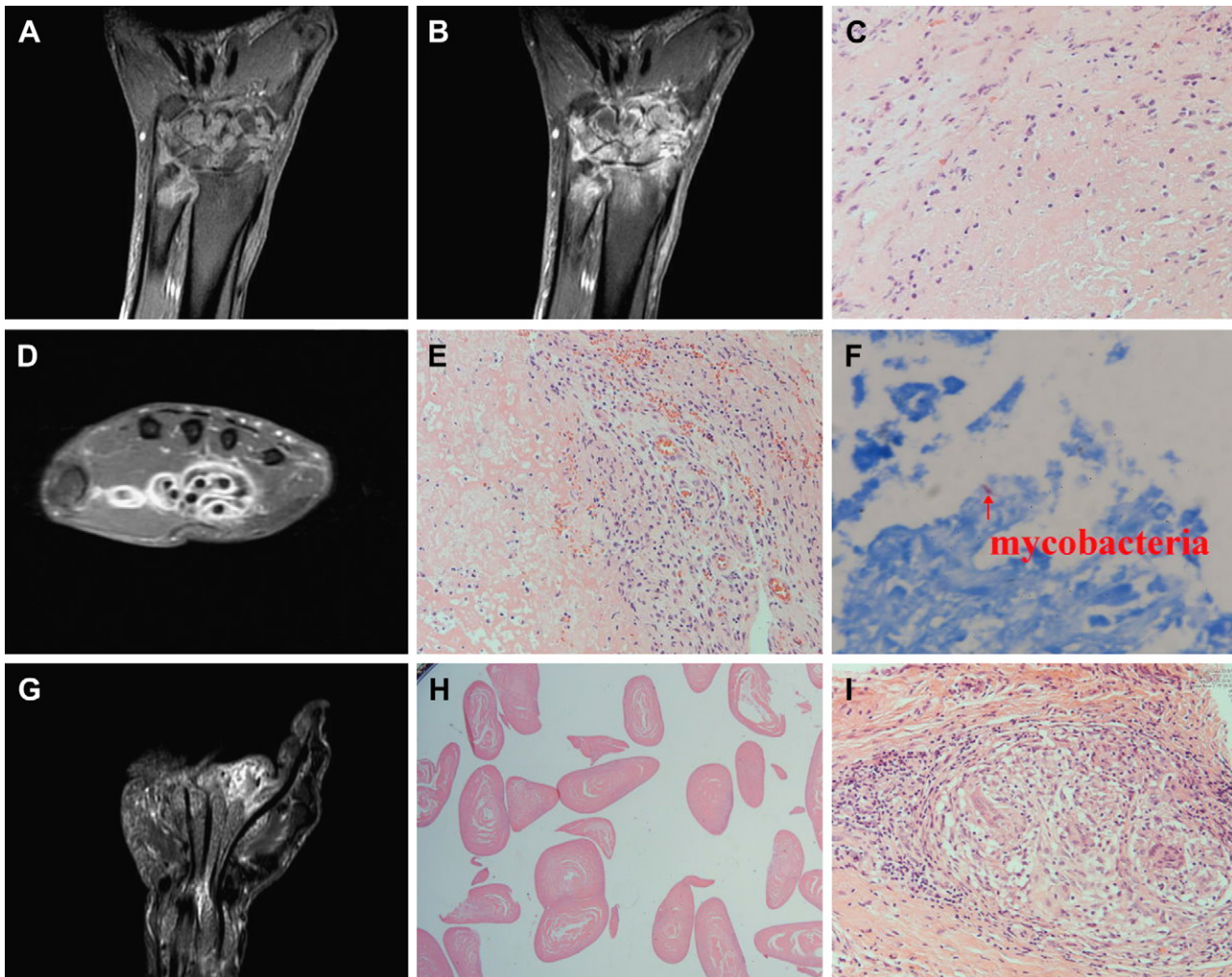
year earlier, without accompanying fever or other discomfort. The swelling extended to the palm with an ulcerative wound. The patient was a fruit farmer and often sustained minor trauma to his hands while working. He had no systemic conditions such as diabetes mellitus, alcoholism, cirrhosis or immunosuppressive status.

A peripheral hemogram revealed a leukocyte count of  $5.76 \times 10^3 / \mu\text{L}$ , hemoglobin level of 15.1 g/dL, and platelet count of  $175 \times 10^3 / \mu\text{L}$ . Serum aspartate aminotransferase was 101 IU/L, urea nitrogen 22 mg/dL, creatinine 1.0 mg/dL and C-reactive protein 0.09 mg/dL. He took oral cephalexin 500 mg every 6 hours, but his symptoms persisted. Plain radiographs showed soft tissue swelling without bone destruction. Magnetic resonance imaging (MRI) revealed granulomas over the carpal bones, distal ulna, carpal joints and wrist joint with peripheral enhancement (Figs. 1A and 1B). He received debridement. During exploration, the abundant granulation tissue spreading along the flexor tendon sheaths was excised as completely as possible. Histological findings revealed chronic granulomatous inflammation with caseous necrosis (Fig. 1C).

After surgery, he was given oral rifampicin 600 mg, ethambutol 800 mg, pyrazinamide 1500 mg and isoniazid 300 mg daily. However, there was erythematous swelling around the surgical wound. One month later, the granulation tissue culture yielded NTM. The antibiotics were changed to clarithromycin 500 mg orally every 12 hours for 6 months. His symptoms subsided gradually. He remained well after 24 months of follow-up.

\* Corresponding author. Division of Infectious Disease, Department of Medicine, Buddhist Dalin Tzu Chi General Hospital, 2 Min-Sheng Road, Dalin, Chiayi, Taiwan. Tel.: +886 5 2648000; fax: +886 5 2648999.

E-mail address: [antibody\\_1@msn.com](mailto:antibody_1@msn.com) (C.-C. Tsai).



**Fig. 1.** In case 1, a coronal T1-weighted magnetic resonance imaging (MRI) scan with fat saturation revealed granulomas over the carpal bones, distal ulna, carpal joints and wrist joint with bony erosions (A). A coronal gadolinium-enhanced fat-suppressed T1-weighted MRI scan showed peripheral enhancement of the granulomas and heterogeneous enhancement of the bony structures (B). Histopathologic examination in case 1 demonstrated granuloma formation with caseous necrosis (H&E, 200 $\times$ ) (C). In case 2, an axial gadolinium-enhanced fat-suppressed T1-weighted MRI scan of the right wrist showed abnormal enhancement of the sheath of the flexor tendons (D). Histopathologic examination demonstrated granuloma formation (H&E, 200 $\times$ ) (E), and a tissue acid-fast stain revealed acid-fast bacilli (Ziehl Neelsen stain, 1000 $\times$ ) (F). In case 3, a coronal short T1 inversion recovery MRI scan revealed loculated fluid signals in the synovial cavity of the tendons with tiny nodular lesions along the flexor tendons (G). Biopsy material revealed rice body formation (H). Histopathologic examination demonstrated noncaseating granuloma formation (H&E, 200 $\times$ ) (I).

## 2.2. Case 2

A 66-year-old man was admitted because of a painful swelling on his right wrist with distal numbness, which had developed 6 years earlier. He was also a fruit farmer and often sustained minor trauma to his hands while working. He had no systemic conditions such as diabetes mellitus, cirrhosis, alcoholism or immunosuppressive status. He had taken several kinds of antibiotics and analgesics, but his symptoms had progressed to the point where he was unable to make a fist.

On arrival, physical examination showed diminished sensation over the territory of the median nerve in the right hand. A peripheral hemogram revealed a leukocyte count of  $6.02 \times 10^3 / \mu\text{L}$ , hemoglobin level of 11.3 g/dL, and platelet count of  $226 \times 10^3 / \mu\text{L}$ . Serum aspartate aminotransferase was 22 IU/L, urea nitrogen 15 mg/dL, creatinine 0.9 mg/dL and C-reactive protein 0.29 mg/dL. A plain radiography revealed a soft tissue swelling over his right hand and wrist. MRI revealed abnormal enhancement of the sheath of the flexor tendons (Fig 1D).

He received a tenosynovectomy and median nerve decompression. During exploration, granulomatous inflammation was noted over the flexor tendon sheaths of the ring and index fingers, spreading into the carpal tunnel involving the tendon sheaths of the flexor digitorum superficialis and flexor digitorum profundus. Histological findings revealed chronic granulomatous inflammation with multinucleated giant cells (Fig. 1E). An acid-fast stain showed positive bacilli pathogens (Fig. 1F). He received oral 600 mg rifampicin and 300 mg isoniazid every day for 2 months, but his symptoms persisted. A tissue culture yielded NTM. The antibiotics were changed to oral clarithromycin 500 mg every 12 hours and ethambutol 800 mg every day for 6 months. His symptoms subsided and he remained well after 5 years of follow-up.

## 2.3. Case 3

A 76-year-old man was admitted because of painful swelling of his right wrist for 2 months. He was also a fruit farmer who sometimes sustained minor trauma to his hands during work. He

had no systemic conditions such as diabetes mellitus, alcoholism, cirrhosis or immunosuppressive status. About 6 months before this admission, he had experienced right hand numbness and was given a local steroid injection. However, his symptoms had persisted and he received carpal tunnel release, after which the numbness in his right hand disappeared. However, 2 months before the current admission, a painful swelling had developed over his right wrist. The swelling extended to the palm and he was unable to make a fist.

A peripheral hemogram revealed a leukocyte count of  $3 \times 10^3/\mu\text{L}$ , hemoglobin level of 15.3 g/dL, and platelet count of  $181 \times 10^3/\mu\text{L}$ . Serum aspartate aminotransferase was 38 IU/L, urea nitrogen 13 mg/dL, creatinine 0.8 mg/dL and C-reactive protein 0.34 mg/dL. A plain radiograph showed soft tissue swelling over the right hand and wrist. Synovial fluid cultures for fungus, bacteria and mycobacteria yielded no pathogens. He took oral cephalexin, but his symptoms progressed. MRI revealed loculated fluid signals in the synovial cavity of the tendons with internal tiny nodular lesions along the flexor tendons (Fig. 1G).

The man was given a synovectomy and decompression of the median nerve. During exploration, numerous shiny soft corpuscles consistent with rice bodies were noted in the flexor tendon sheaths. The soft corpuscles could easily be removed using a spoon (Fig. 2). Histological findings showed rice body formation with granulomatous inflammation (Figs. 1H and 1I). Granulation tissue collected for molecular analysis was negative for *Mycobacterium tuberculosis*. Tissue culture for mycobacteria, bacteria, and fungi yielded no pathogens. He received oral clarithromycin 500 mg, sulfamethoxazole 400 mg/trimethoprim 80 mg, and doxycycline 100 mg every 12 hours for 4 months. His symptoms subsided gradually and he could return to work without limitations. He remained well after 18 months of follow-up.

### 3. Discussion

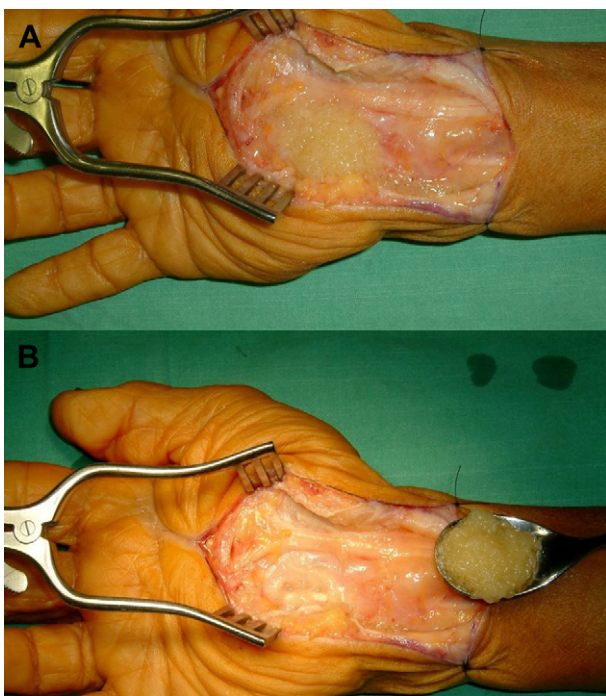
Ninety percent of cases of NTM infection involve the pulmonary system; the rest involve the lymph nodes, skin, soft tissues

and bones. Less frequently reported are central nervous system disease, keratitis and otitis media [7]. NTM tenosynovitis is rarely reported [1,7–10]. However, this pathogen is very important in granulomatous tenosynovitis. A previous study showed that 11 of 25 cases of granulomatous tenosynovitis were caused by NTM, four by *Mycobacterium tuberculosis* (TB) and five by *Mycobacterium* species [1]. Because soil and water are the environmental reservoirs of NTM, most cases of NTM tenosynovitis are associated with traumatic events [1,7–10]. The present patients were all fruit farmers who often sustained minor trauma to their hands while working. They often ignored these lesions, which provided a portal of entry for NTM into the soft tissues. Because of its slow growth, NTM seeding into soft tissue can cause symptoms after wounds heal. Gloves should be used during farm work to prevent this infection.

Typically, the correct diagnosis of NTM tenosynovitis is often delayed. In a previous report, the length of time between the onset of symptoms and diagnosis was often as long as 1 year [8]. This is because of the indolent course, nonspecific presentation and long duration needed for culture. In the present cases, Kanavel's four cardinal signs of flexor tenosynovitis (the presence of intense pain with any attempt to extend the finger, holding of the finger in the flexion or bent position to maintain comfort, swelling that involves the entire finger, and tenderness with touch along the course of the tendon) were absent at the initial presentation even though synovial involvement was noted in the image study. Inflammation markers, such as C-reactive protein, are within normal limits. In the present cases, granulomatous tenosynovitis could be considered in the differential diagnosis only after image study was done before surgery. The erythrocyte sedimentation rate (ESR) is an important marker for chronic inflammation, such as in chronic osteomyelitis. Unfortunately we did not obtain these data in the present cases. However, a previous report showed that the ESR could be normal in NTM tenosynovitis [10]. As a result of the nonspecific clinical findings of NTM tenosynovitis, patients may initially be misdiagnosed with trigger finger and treated with local injections of steroids, which worsens their symptoms. It is very difficult to demonstrate NTM as the cause of tenosynovitis. Pathology, image study, and an acid-fast stain may provide some clues for diagnosis. However, mycobacterial culture is the only way to obtain information on the NTM species and antimicrobial susceptibilities. It is very important to obtain a high yield for mycobacterial culture. According to the recommendations of American Thoracic Society and Infectious Diseases Society of America, aseptic collection of as much body fluid or abscess fluid as possible for NTM culture by needle aspiration or surgical procedures is recommended. Tissue cultures are acceptable, but swabs are not currently recommended [11].

Rice bodies occurring in joints affected by tuberculosis were first described in 1895. They are composed of fibrin. However, the cause of rice body formation remains obscure. It is most likely an unusual complication of chronic bursitis [12]. Some investigators have suggested that a possible cause is microinfarctions after intra-articular inflammation and ischemia, with subsequent synovial shedding and encasement by fibrin derived from synovial fluid [13]. In recent reports of four cases, rice body formation was associated with NTM tenosynovitis [14,15]. In the present third case, rice-body formation was grossly visible in the tissue during surgery. Although the cultures yielded no pathogens, it was still difficult to rule out NTM infection. Because the symptoms, history and disease course were similar to the first two cases, NTM was considered as the most likely pathogen in this third case of granulomatous tenosynovitis.

Treatment for NTM tenosynovitis is surgical resection followed by an antimycobacterial drug regimen. The typical intra-operative



**Fig. 2.** Surgical exploration in case 3 showed numerous shiny, soft corpuscles consistent with rice bodies in the common flexor tendon synovial fluid (A). The soft corpuscles could easily be removed using a spoon (B).

findings include exuberant synovial granulomatous tissue and attenuation of the pulleys. It is essential to remove all infected synovium to prevent recurrence. However, finger stiffness may occur because of tissue scarring after synovectomy. The choice of empirical antibiotics is a big problem after surgery. In case 1, growth of mycobacterial cultures needed a long duration after surgery. In case 2, acid-fast bacilli found in the tissue pathology could not be differentiated between NTM and TB. Anti-TB therapies were given first in both cases and were not effective at controlling clinical symptoms. Differentiation between TB and NTM is important for empirical antibiotic therapy. In previous studies, TB tenosynovitis was associated with several factors, such as older age, poor nutrition, history or exposure to TB, immunosuppression, alcohol abuse and corticosteroid usage [16]. Because the present cases did not have these risk factors and often contacted soil with their hands, a diagnosis of NTM was preferred to TB.

According to present therapeutic guidelines for NTM infection, an antimycobacterial regimen is best based on NTM species and drug-susceptibility tests. However, identification of the NTM species and drug susceptibility are often delayed or not routinely performed in the clinical lab. In one review, 13 different species of NTM were reported in NTM tenosynovitis [17,18]. The most common are *M. marinum*, *M. avium complex* and *M. kansasii*. Other less frequently seen organisms are *M. haemophilum*, *M. szulgai*, *M. terrae*, *M. fortuitum*, *M. chelonae*, *M. abscessus*, *M. malmoense*, *M. nonchromogenicum*, *M. scrofulaceum* and *M. xenopi*. In one review article, different NTM species showed different *in vitro* susceptibilities to different antimycobacterial agents [18]. For this reason, it is very difficult to select an empirical antimycobacterial regimen for a patient with species-unconfirmed NTM tenosynovitis, like the present cases. Because more than 90% of tested NTM isolates, including *M. avium complex*, *M. kansasii*, *M. abscessus*, *M. fortuitum*, *M. chelonae*, *M. malmoense*, *M. xenopi*, *M. marinum* and *M. haemophilum* were susceptible to clarithromycin *in vitro* [18], we selected a clarithromycin-based antimycobacterial regimen to treat all three cases, and they responded well. When a patient is diagnosed with NTM granulomatous tenosynovitis, a clarithromycin-based antimycobacterial regimen seems to be a good regimen for empirical treatment.

In summary, we have reported three cases of granulomatous tenosynovitis of the wrist caused by NTM. All were cured by

surgical debridement and a clarithromycin-based antimycobacterial antibiotic regimen.

## References

- [1] Sutker WL, Lankford LL, Tompsett R. Granulomatous synovitis: the role of atypical mycobacteria. *Rev Infect Dis* 1979;1:729–35.
- [2] Smith J, Ruby LK. *Nocardia asteroides* thenar space infection: a case report. *J Hand Surg Am* 1977;2:109–10.
- [3] Liang KV, Ryu JH, Matteson EL. Histoplasmosis with tenosynovitis of the hand and hypercalcemia mimicking sarcoidosis. *J Clin Rheumatol* 2004;10:138–42.
- [4] Schwartz DA. Sporothrix tenosynovitis—differential diagnosis of granulomatous inflammatory disease of the joints. *J Rheumatol* 1989;16:550–3.
- [5] Waggenspack GA, Amparo EG. Case report 466. Granulomatous tenosynovitis (left 3rd finger). *Skeletal Radiol* 1988;17:133–5.
- [6] Kostman JR, Rush P, Reginato AJ. Granulomatous tophaceous gout mimicking tuberculous tenosynovitis: report of two cases. *Clin Infect Dis* 1995;21:217–9.
- [7] Piersimoni C, Scarparo C. Extrapulmonary infections associated with nontuberculous mycobacteria in immunocompetent persons. *Emerg Infect Dis* 2009;15:1351–8.
- [8] Zenone T, Boibieux A, Tigaud S, Fredenucci JF, Vincent V, Peyramond D. Nontuberculous mycobacterial tenosynovitis: report of two cases. *Clin Infect Dis* 1998;26:1467–8.
- [9] Brown-Elliott BA, Griffith DE, Wallace Jr RJ. Diagnosis of nontuberculous mycobacterial infections. *Clin Lab Med* 2002;22:911–25.
- [10] Akahane T, Nakatsuchi Y, Tateiwa Y. Recurrent granulomatous tenosynovitis of the wrist and finger caused by *Mycobacterium intracellulare*: a case report. *Diagn Microbiol Infect Dis* 2006;56:99–101.
- [11] Griffith DE, Aksamit T, Brown-Elliott BA, Catanzaro A, Daley C, Gordin F, et al. An official ATS/IDSA statement: diagnosis, treatment, and prevention of nontuberculous mycobacterial diseases. *Am J Respir Crit Care Med* 2007;175:367–416.
- [12] Chen A, Wong LY, Sheu CY, Chen BF. Distinguishing multiple rice body formation in chronic subacromial-subdeltoid bursitis from synovial chondromatosis. *Skeletal Radiol* 2002;31:119–21.
- [13] Geiler G, Mehlhorn U. Vasculitis with anemia infarcts of the villi of the synovial membrane in rheumatoid arthritis. *Z Rheumatol* 1989;48:63–7.
- [14] Chau CL, Griffith JF, Chan PT, Lui TH, Yu KS, Ngai WK. Rice-body formation in atypical mycobacterial tenosynovitis and bursitis: findings on sonography and MR imaging. *AJR Am J Roentgenol* 2003;180:1455–9.
- [15] Nagasawa H, Okada K, Senma S, Chida S, Shimada Y. Tenosynovitis with rice body formation in a non-tuberculosis patient: a case report. *Ups J Med Sci* 2009;114:184–8.
- [16] Marques VB, Vieira HP, Alcantara AC, Braga FN, Rocha FA, Medeiros MC. Tenosynovitis and carpal tunnel syndrome from mycobacterium tuberculosis—a rare manifestation of extrapulmonary tuberculosis. *Acta Reumatol Port* 2010;35:82–4.
- [17] Zenone T, Boibieux A, Tigaud S, Fredenucci JF, Vincent V, Chidiac C, et al. Nontuberculous mycobacterial tenosynovitis: a review. *Scand J Infect Dis* 1999;31:221–8.
- [18] Wagner D, Young LS. Nontuberculous mycobacterial infections: a clinical review. *Infection* 2004;32:257–70.