



## Images in Clinical Medicine

## Procidentia-induced hydronephrosis and subsequent urosepsis

Kuo-Hu Chen <sup>a,b,\*</sup>, Li-Ru Chen <sup>c</sup><sup>a</sup> Department of Obstetrics and Gynecology, Buddhist Tzu Chi General Hospital, Taipei Branch, Taipei, Taiwan<sup>b</sup> School of Medicine, Tzu Chi University, Hualien, Taiwan<sup>c</sup> Department of Physical Medicine and Rehabilitation, Mackay Memorial Hospital, Main Branch, Taipei, Taiwan

## ARTICLE INFO

## Article history:

Received 2 May 2011

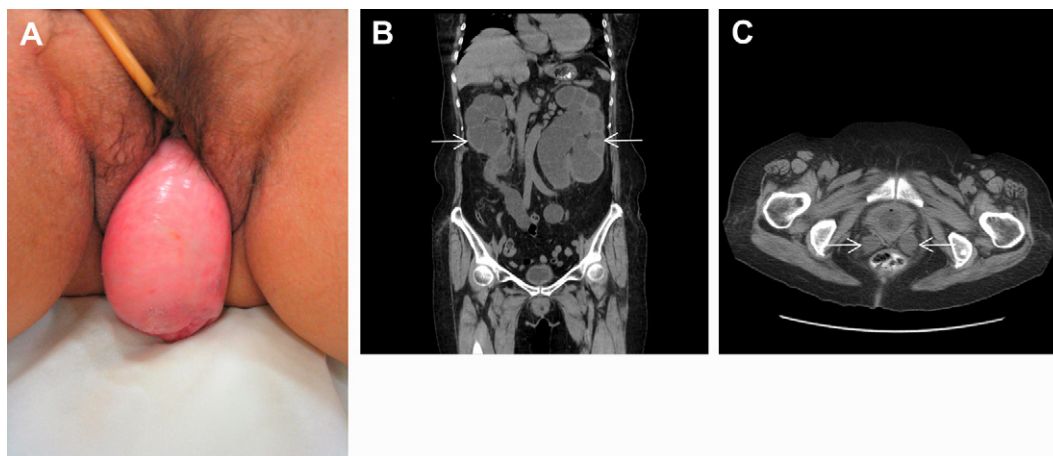
Received in revised form

23 May 2011

Accepted 24 May 2011

A 79-year-old woman presented to the emergency department with loin pain, decreased urine output, and fever up to 39.5°C. On physical examination, she had tenderness over the bilateral flanks, but she declined a pelvic examination. Urinalysis revealed bacteriuria, and a blood test indicated marked leukocytosis. Intravenous

cefazolin plus gentamicin were administered; however, her condition worsened with persistent high fever and altered consciousness. After our detailed explanation of the procedure, she underwent a pelvic examination (Fig. 1A) and abdominal computed tomography (Fig. 1B and C), which showed significant procidentia



**Fig. 1.** (A) Photograph of the external genitalia on pelvic examination shows procidentia; the uterus is noted protruding outside the vagina. (B and C) Abdominal computed tomography reveals severe bilateral hydronephrosis (arrows) and hydroureter without bladder distension, implying that the level of obstruction is at the ureterovesical junction (arrows).

Conflict of interest: none.

\* Corresponding author. Department of Obstetrics and Gynecology, Buddhist Tzu Chi General Hospital, Taipei Branch, 289 Jianguo Road, New Taipei City, Taiwan. Tel.: +886 2 66289779x1552; fax: +886 2 82191896.

E-mail address: [alexgfctw@yahoo.com.tw](mailto:alexgfctw@yahoo.com.tw) (K.-H. Chen).

(total pelvic prolapse, including uterine prolapse, cystocele, and rectocele), severe bilateral hydronephrosis, and hydroureter without bladder distension. Kinked, enlarged ureters were seen before entering the bladder, which further implied that the level of

obstruction was at the ureterovesical junction. Pelvic reconstruction surgery, including a hysterectomy, bladder neck suspension, and mesh repair was performed, followed by administration of broad-spectrum antibiotics. Hereafter, she recovered well and was discharged after 7 days of hospitalization. A follow-up ultrasound demonstrated regression of the hydronephrosis.

This unusual condition occurs more commonly in elderly or multiparous women, in whom the pelvic organs, including the uterus, bladder, and rectum, drop outside the bony pelvis. Distortion of the normal structure may result in urinary tract obstruction, hydronephrosis, and even urosepsis.

In many countries, pelvic prolapse and associated symptoms are considered embarrassing, so women usually avoid mentioning the condition or undergoing related examinations when seeking medical help. Therefore, it can be overlooked by clinicians. Obtaining a detailed patient history and a thorough evaluation, including physical, pelvic, laboratory, and image examinations, are important for both the correct diagnosis and treatment. Releasing the obstruction and regaining function of the urinary system are essential in the management. Restoration of the anatomic position

can be achieved by use of a pessary to improve physical support or by means of surgery if the condition is severe or nonsurgical attempts fail. Early recognition and timely intervention are the keys to saving the kidneys from further irreversible change.

### Further reading

- [1] Chuang FR, Lee CH, Chen CS, Weng HH, Wang IK. Bilateral moderate hydro-ureteronephrosis due to uterine prolapse: two case reports and review of the literature. *Ren Fail* 2003;25:879–84.
- [2] Sanai T, Yamashiro Y, Nakayama M, Uesugi N, Kubo N, Iguchi A. End-stage renal failure due to total uterine prolapse. *Urology* 2006;67:e5–7.
- [3] Sudhakar AS, Reddi VG, Schein M, Gerst PH. Bilateral hydroureter and hydronephrosis causing renal failure due to a procidentia uteri: a case report. *Int Surg* 2001;86:173–5.
- [4] Hadar H, Meiraz D. Total uterine prolapse causing hydroureteronephrosis. *Surg Gynecol Obstet* 1980;150:711–4.
- [5] Flord Jr MS, Casey RG, Bredin HC. Procidentia: a reversible cause of hydronephrosis in an 80-year-old woman. *Int Urogynecol J* 2008;19:1179–81.
- [6] White AB, Wai CY, Mannis SI, Schaffer JI. Bilateral ureteric obstruction of a partially duplicated collecting system improves after surgical correction of procidentia: a case report. *J Reprod Med* 2008;53:449–52.