



Pathology Page

Myeloma cast nephropathy

Yung-Hsiang Hsu*

Department of Pathology, Buddhist Tzu Chi General Hospital and Tzu Chi University, Hualien, Taiwan

ARTICLE INFO

Article history:

Received 21 September 2010

Received in revised form

6 October 2010

Accepted 7 October 2010

A 63-year-old man visited our hospital with a complaint of oliguria for 1 day. Laboratory studies showed the following results: albumin/globulin ratio 3.4/2.7 g/dL, alkaline phosphatase 300 IU/L, blood urea nitrogen 12.4 mg/dL, creatine 11.4 mg/dL, uric acid 21.2 mg/dL, and calcium 3.78 mmol/L. Radiography showed multiple punched-out lesions in the skull. Acute renal failure because of multiple myeloma was diagnosed. The patient died of

pneumonia. At autopsy, bilateral kidney swelling (each kidney 180 g) was noted. On cut section, the cortex appeared waxy. Histopathology showed a broad, dense, fractured (broken glass-like) casts filled with tubules diagnostic of myeloma cast nephropathy (Fig. 1).

Multiple myeloma cast nephropathy refers to renal injury caused by monoclonal immunoglobulin-like chains in the urine that produce tubular epithelial injury and numerous tubular casts. Circulating light chains filtered by the glomeruli are believed to cause the illness. At the acidic pH typical for urine, light chains are likely to precipitate and cause tubular damage and obstruction.

Microscopically, the characteristic tubular lesions associated with multiple myeloma are composed of numerous dense, laminated, fractured casts in the distal and collecting ductules. Immunohistochemistry staining shows that the casts contain light chain material, usually kappa light chains. Patients with myeloma cast nephropathy usually present with acute renal failure. Proteinuria is present, although usually not in the nephrotic range and most often consists predominantly of immunoglobulin light chains.

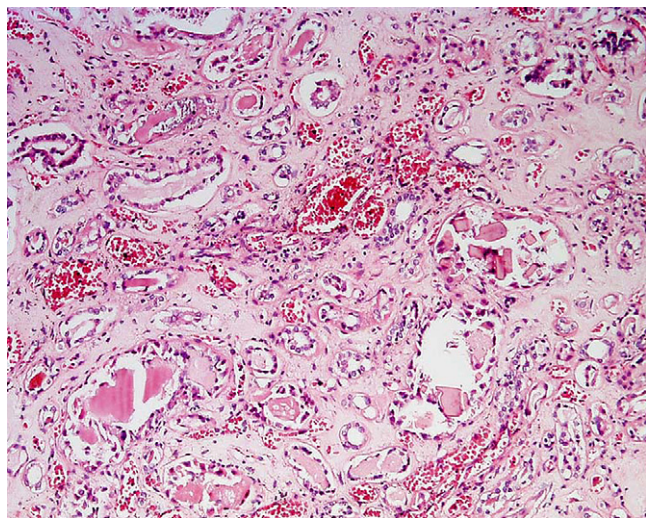


Fig. 1. Histopathology shows broad, dense, fractured casts in the distal tubules and collecting ductules (HE×100). HE = hematoxylin and eosin stain.

Further reading

- [1] Prakash J, Niwas SS, Parekh A, Vohra R, Wani IA, Sharma N, et al. Multiple myeloma—presenting as acute kidney injury. *J Assoc Physicians India* 2009;57:23–6.
- [2] Herrera GA, Joseph L, Gu X, Hough A, Barlogie B. Renal pathologic spectrum in an autopsy series of patients with plasma cell dyscrasia. *Arch Pathol Lab Med* 2004;128:875–9.
- [3] Basić-Jukić N, Kes P, Labar B. Myeloma kidney: pathogenesis and treatment. *Acta Med Croatica* 2001;55:169–75.

* Corresponding author. Department of Pathology, Buddhist Tzu Chi General Hospital, 707, Section 3, Chung-Yang Road, Hualien, Taiwan. Tel: +886 3 856 5301x7298; fax: +886 3 857 4265.

E-mail address: yhsu@mail.tcu.edu.tw.