



Case Report

Perforated Appendiceal Mucinous Cystadenoma Mimicking Ruptured Appendicitis With Abscess Formation: CT Imaging Features

Hsin-Chi Chen^{1*}, Willie Chen², Pao-Sheng Lee², Ming-Chi Chiang¹,
Juin-Shom Liu²

¹Department of Radiology, Nan-Men General Hospital, Hsinchu, Taiwan

²Department of Surgery, Nan-Men General Hospital, Hsinchu, Taiwan

Article info

Article history:

Received: September 13, 2010

Revised: September 21, 2010

Accepted: September 28, 2010

Keywords:

Appendicitis

Appendix

Computed tomography

Mucinous cystadenoma

Perforation

Abstract

We describe the imaging features of a perforated appendiceal mucinous cystadenoma in a 72-year-old woman presenting with right lower quadrant abdominal pain, mimicking ruptured appendicitis with abscess formation. Computed tomography revealed a rim-enhanced cystic lesion at the proximal appendiceal orifice, connecting with the swollen and dilated distal part of the appendix. Disruption of the appendiceal walls and peri-appendiceal fatty infiltrations were also noted. Under the impression of ruptured appendicitis with abscess formation, the patient underwent exploratory laparotomy and appendectomy. The pathologic diagnosis was perforated appendiceal mucinous cystadenoma associated with superinfection, complicated by secondary appendicitis. The patient was uneventfully discharged on the 7th hospital day. Although primary neoplasms of the appendix are uncommon, they should be considered as a predisposing factor in elderly patients manifesting with appendicitis. (*Tzu Chi Med J* 2010;22(4):244–247)

*Corresponding author. Department of Radiology, Nan-Men General Hospital, 20, Linshen Road, Hsinchu, Taiwan.

E-mail address: hsinchi.chen715@msa.hinet.net

1. Introduction

Appendix rupture complicated by peritonitis is an emergency surgical condition. The majority of appendix ruptures are caused by a non-tumoral inflamed appendicitis; about 1% of appendicitis is associated with an underlying primary appendiceal tumor (1). Computed tomography (CT) imaging findings of tumor-related

appendiceal perforation can mimic those of inflammatory ruptured appendicitis without a tumor. Mucinous cystadenoma is the most common benign mucin-secreting tumor arising from the appendix; it occurs in middle-aged adults or elderly people. Here, we present a case of perforated appendiceal mucinous cystadenoma superimposed infection manifesting as ruptured appendicitis with periappendiceal abscess formation.

2. Case report

A 72-year-old woman came to the emergency department because of intensifying right lower quadrant abdominal pain for 4 days and acute exacerbation in the previous 2 days. Physical examination revealed a soft abdomen with local rebound tenderness at the right lower quadrant of the abdomen. The psoas sign and Rovsing's sign were also positive, indicating peritonitis. A mild fever (body temperature, 37.5°C), mild leukocytosis (white blood cell count, 10,220/ μ L) and elevated C-reactive protein (6.3 mg/dL) were also noted. Other laboratory data were within normal limits. Abdominal sonography revealed a hypoechoic lesion in the right lower quadrant of the abdomen which could have been a right ovarian cystic mass, intra-abdominal abscess or another etiology. CT depicted an oblong cystic lesion measuring approximately

2.3×6.2 cm with a CT value of 18 HU. It was located in the right lower quadrant of the abdomen, near the cecum base, and had a whirled appearance of supplying mesenteric vessels around it (Fig. 1A). The cystic lesion seemed to arise from the appendiceal orifice and exhibited rim enhancement. It had a wall defect at its inner aspect, suggesting possible appendiceal wall rupture (Fig. 1B). The cystic lesion was also connected with the enlarged distal part of the appendix, and associated with surrounding periappendiceal fat stranding (Figs. 1C and 1D). The tubular dilated distal portion of the appendix had abnormal enhanced thickened walls, and its lumen was filled with air and fluid-attenuating material (Fig. 1D). No appendiceal mural calcification or regional enlarged lymph nodes were present.

The CT imaging features led to a presumptive diagnosis of ruptured appendicitis complicated by

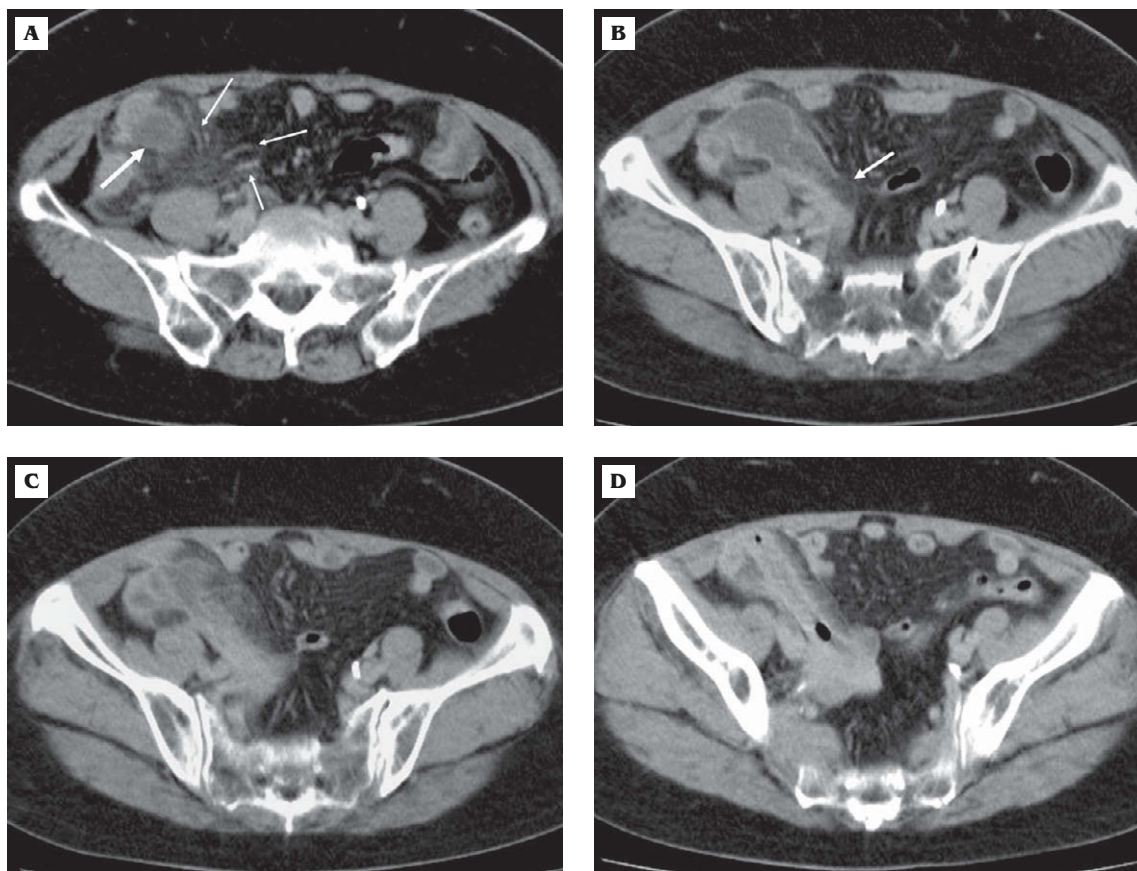


Fig. 1 — A 72-year-old woman presenting with right lower quadrant abdominal pain caused by a perforated appendiceal mucinous cystadenoma. (A) Post-enhanced CT shows a thin-walled, oval, low-attenuation lesion (large arrow) in the right lower quadrant of the abdomen, associated with a whirled appearance of adjacent mesenteric vessels (small arrows), suggesting possible tumor torsion. (B) CT scan at a level more caudal than panel A shows a low-attenuation lesion arising from the appendiceal orifice, contiguous with the cecal base. There is a focal wall defect (arrow) at its inner aspect, indicating tumor rupture. (C) CT scan at a level more caudal than panel B shows the elongated low-attenuation lesion connecting with the distal part of the appendix, associated with periappendiceal fat stranding. (D) CT scan at the appendix tip level shows the dilated distal portion of the appendix exhibiting abnormal enhanced thickened walls with intraluminal air and fluid content.

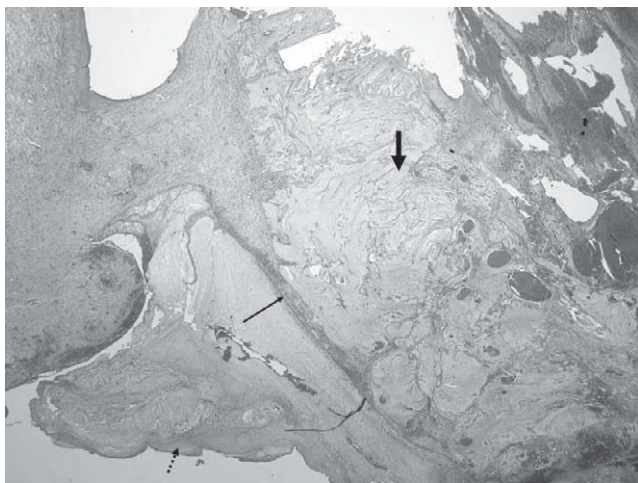


Fig. 2 — Photomicrograph (hematoxylin & eosin, 25×) reveals the dilated appendix filled with basophilic mucin content (large arrow), lined by dysplastic flattened epithelium (small arrow). The neoplastic epithelium shows mild nuclear stratification. Focal appendiceal wall rupture complicated by extraluminal leak of mucin (dotted arrow) is also noted.

periappendiceal abscess formation. The patient subsequently underwent exploratory laparotomy and appendectomy. During surgery, the appendix was found to be enlarged, erythematous and inflamed, with some torsion identified at its base. The appendix was ruptured and surrounded by abundant yellow gelatinous mucoid material mixed with purulent material. Pus culture revealed growth of *Escherichia coli* and Group B *Enterococcus*. Pathologic examination revealed the appendix to be 6.2 cm in length and 2.3 cm at the greatest diameter, and consisted of an intraluminal mucin-containing tumor arising from its proximal portion. The mucin-filled, cystic dilated proximal appendiceal lumen was lined by dysplastic flattened epithelium with mild nuclear stratification (Fig. 2). Focal appendiceal wall rupture with extraluminal leakage of mucin material was also noted. Perforated appendiceal mucinous cystadenoma with superinfection, complicated by appendicitis was diagnosed. The postoperative course was uneventful and the patient was discharged 7 days later without any complications. A follow-up CT study 22 months later revealed no abnormal focal pseudomyxoma peritonei at the pericecal region.

3. Discussion

Appendicitis is a common and urgent surgical illness, caused by appendiceal lumen obstruction and inflammation due to lymphoid hyperplasia, fecalith formation, tumors or other etiologies. Primary neoplasms

of the appendix are present in approximately 0.5–1.0% of appendectomy specimens (1,2), and generally affect middle-aged adults and elderly people (3). In contrast to tumor-related appendicitis, the vast majority of patients under 30 years of age have ordinary acute appendicitis without a coexisting tumor (4), and an impacted appendicolith may be observed in about one-third of cases (5). Therefore, from a clinical standpoint, an elderly patient with an atypical presentation of suspected appendicitis may have an underlying appendiceal neoplasm. Our patient was 72 years old and had no visible impacted appendicolith, so the possibility of an underlying appendiceal tumor with resultant appendicitis needed to be taken into consideration.

Approximately 30–50% of appendiceal neoplasms manifest with acute appendicitis by luminal obstruction and/or association with superinfection (2,6), which is clinically indistinguishable from non-tumoral appendicitis. Mucin-secreting tumors comprise the majority of primary appendiceal tumors manifesting as appendicitis, of which the mucinous cystadenoma is the most common type (6–8). Mucinous cystadenoma can produce an abundant accumulation of mucin leading to marked appendiceal luminal distension. The appendiceal diameter usually exceeds the threshold of 6–7 mm, which corresponds with the CT diagnostic criteria for acute appendicitis without a coexisting tumor (5). Pickhardt and colleagues (6) found that an appendiceal diameter greater than 15 mm and cystic dilatation of the appendix on CT imaging are highly suggestive of an associated neoplasm in patients with acute appendicitis. Bennett et al (3) also concluded that CT features suggestive of a mucinous neoplasm coexisting with acute appendicitis include cystic dilatation of the appendix, mural calcification and a luminal diameter exceeding 13 mm. In our case, the mucinous cystadenoma was seen as an oval cystic lesion situated at the proximal appendiceal orifice with an appendiceal diameter of 23 mm, which provided a diagnostic clue that an appendiceal cystic-like tumor had induced secondary obstructive appendicitis.

Torsion of an appendiceal mucinous cystadenoma is a very rare entity, and only a few cases have been reported in the literature (9). As shown in this case, CT demonstration of whirled-like vessels around the appendiceal cystic tumor is suggestive of tumor torsion. We postulated that in our patient, the distorted appendiceal tumor with its twisted supplying vessels worsened the tumoral vascular compromise, and subsequently induced tumor ischemia and necrosis, which was further followed by superinfection. Once the superinfection developed, the infected mucin-containing tumor had a strong propensity to dissect into the appendiceal mucosa, causing mucosa ulceration and possibly allowing progression to appendiceal wall perforation accompanied by tumor rupture. Our patient not only had appendiceal mucin-tumor torsion with

superimposed infection complicated by purulent material within the mucin pools, but also had tumor rupture with mucin spillage into the peritoneal cavity.

Spontaneous tumor perforation occurs in about 20% of cases of appendiceal mucinous cystadenoma (3); this may cause extraluminal mucin spillage, which may cause CT diagnostic confusion with ruptured non-tumoral appendicitis complicated by periappendiceal abscess formation. Appendiceal mucin-containing tumors usually manifest as paracecal cystic lesions with homogeneous low-attenuation CT Hounsfield values of or near those of water, similar to the values of purulent fluids in a periappendiceal abscess. Hence, once perforation of a mucin-rich tumor occurs, it is often difficult to differentiate the low-attenuation extraluminal mucin composition from a similar low attenuation periappendiceal abscess on CT. Bennett and associates (3) reviewed 12 cases of acute appendicitis related to mucinous neoplasms and found that three of them had presented with ruptured lesions. These ruptured mucinous lesions, in which CT showed periappendiceal fluid and gas-containing collections, were prospectively misinterpreted as perforated ordinary non-tumoral appendicitis with pericecal abscess formation. A concomitant appendiceal mucinous neoplasm was not prospectively diagnosed.

As in our case, a perforated appendiceal mucinous cystadenoma exhibits as a thin rim-enhancing low-attenuation cystic lesion with a focal wall defect in the pericecal area, and is also associated with adjacent fatty infiltration, mimicking a periappendiceal abscess complicated by ruptured non-tumoral appendicitis. Although it is difficult to differentiate an appendiceal mucinous neoplasm from complicated appendicitis with an abscess on CT by evaluation of the lesion attenuation value alone, the characteristic location for appendiceal mucinous neoplasms can provide an additional diagnostic clue. Generally speaking, an appendiceal mucinous neoplasm is usually situated at the proximal appendiceal orifice (near the cecum base) as a leading point causing distal appendiceal lumen obstruction with secondary appendicitis. In contrast, a periappendiceal abscess complicated

by non-tumoral appendicitis is often located at the distal appendix tip and sometimes extends downward to the pelvic cavity.

In conclusion, an accurate preoperative CT diagnosis of appendiceal mucinous neoplasm and tumor rupture is important, because it may affect the appropriate surgical approach. The surgeon should avoid using simple laparoscopic appendectomy and adopt an open procedure with a laparotomy appendectomy for total resection of the tumor and complete removal of the disseminated mucinous implants.

References

1. Connor SJ, Hanna GB, Frizelle FA. Appendiceal tumors: retrospective clinicopathologic analysis of appendiceal tumors from 7,970 appendectomies. *Dis Colon Rectum* 1998;41:75-80.
2. Carr NJ, McCarthy WF, Sobin LH. Epithelial noncarcinoid tumors and tumor-like lesions of the appendix: a clinicopathologic study of 184 patients with a multivariate analysis of prognostic factors. *Cancer* 1995;75:757-68.
3. Bennett GL, Tanpitukpongse TP, Macari M, Cho KC, Babb JS. CT diagnosis of mucocele of the appendix in patients with acute appendicitis. *AJR Am J Roentgenol* 2009;192:W103-10.
4. Addiss DG, Shaffer N, Fowler BS, Tauxe RV. The epidemiology of appendicitis and appendectomy in the United States. *Am J Epidemiol* 1990;132:910-25.
5. Pinto Leite N, Pereira JM, Cunha R, Pinto P, Sirlin C. CT evaluation of appendicitis and its complications: imaging techniques and key diagnostic findings. *AJR Am J Roentgenol* 2005;185:406-17.
6. Pickhardt PJ, Levy AD, Rohrmann CA Jr, Kende AI. Primary neoplasms of the appendix manifesting as acute appendicitis: CT findings with pathologic comparison. *Radiology* 2002;224:775-81.
7. Pickhardt PJ, Levy AD, Rohrmann CA Jr, Kende AI. Primary neoplasms of the appendix: radiologic spectrum of disease with pathologic correlation. *Radiographics* 2003;23:645-62.
8. Persaud T, Swan N, Torreggiani WC. Giant mucinous cystadenoma of the appendix. *Radiographics* 2007;27:553-7.
9. Hebert JJ, Pickhardt PJ. MDCT diagnosis of an appendiceal mucocele with acute torsion. *AJR Am J Roentgenol* 2007;189:W4-6.