



Case Report

Preoperative Diagnosis of Fallopian Tube Carcinoma by Transvaginal Sonography, MRI and CA125

Yaw-Ren Hsu^{1,2*}, Jeng-Hsiu Hung^{1,2}, Chung-Tai Yue^{2,3}

¹Department of Obstetrics and Gynecology, Buddhist Tzu Chi General Hospital, Taipei Branch, Taipei, Taiwan

²School of Medicine, Tzu Chi University, Hualien, Taiwan

³Department of Pathology, Buddhist Tzu Chi General Hospital, Taipei Branch, Taipei, Taiwan

Article info

Article history:

Received: March 8, 2010

Revised: March 25, 2010

Accepted: April 29, 2010

Keywords:

Fallopian tube carcinoma
Magnetic resonance imaging
Transvaginal sonography
Tumor marker CA125

Abstract

Primary fallopian tube carcinoma is the least common of the gynecological malignancies and rarely diagnosed preoperatively. We report the case of a 70-year-old woman with primary tubal carcinoma, which was diagnosed preoperatively on the basis of elevated CA125 and characteristic features found by transvaginal sonography, transvaginal color flow imaging and magnetic resonance imaging. Transvaginal ultrasonography showed a sausage-shaped solid mass alongside the right ovary. Transvaginal color Doppler imaging revealed characteristically low impedance vascular flow within the solid components. A pathohistological study confirmed the diagnosis of fallopian tube carcinoma. (*Tzu Chi Med J* 2010;22(4): 225–228)

*Corresponding author. Department of Obstetrics and Gynecology, Buddhist Tzu Chi General Hospital, Taipei Branch, 289, Jianguo Road, Xindian, Taipei, Taiwan.
E-mail address: yawren.hsu@gmail.com

1. Introduction

Primary adenocarcinoma of the fallopian tube comprises only 0.3% of all gynecological cancers (1). In many patients, fallopian tube carcinoma is asymptomatic. A definite preoperative diagnosis of fallopian tube cancer is made in only 3–15% of patients, and the usual clinical diagnosis is an ovarian tumor or pelvic inflammatory disease (1–4). The aim of this paper is to discuss the clinical presentation, transvaginal sonography results and magnetic resonance imaging (MRI) features of fallopian tube carcinoma as well as the role of the tumor marker CA125 in its diagnosis. Furthermore, we assess the response and follow-up to the postsurgical treatment and chemotherapy of the epithelial ovarian cancer.

2. Case report

A 70-year-old, gravida 4, para 4, woman came to our hospital due to a dull pain over her right lower abdomen, but no serosanguineous vaginal discharge or postmenopausal bleeding. Pap smear was normal. Transvaginal ultrasonography showed a sausage-shaped solid mass measuring 7 × 3 cm alongside the right ovary. Doppler flow indicated a flow with a resistance index of 0.33 (Fig. 1). The patient's CA125 antigen level was 173 U/mL. MRI of the whole abdomen with and without contrast enhancement revealed a tubular tumor mass (7.99 × 2.89 cm) in the right pelvic cavity r/o salpinx tumor, unremarkable changes to the liver, spleen and pancreas, no enlarged lymph nodes in the pelvic and para-aortic regions and no

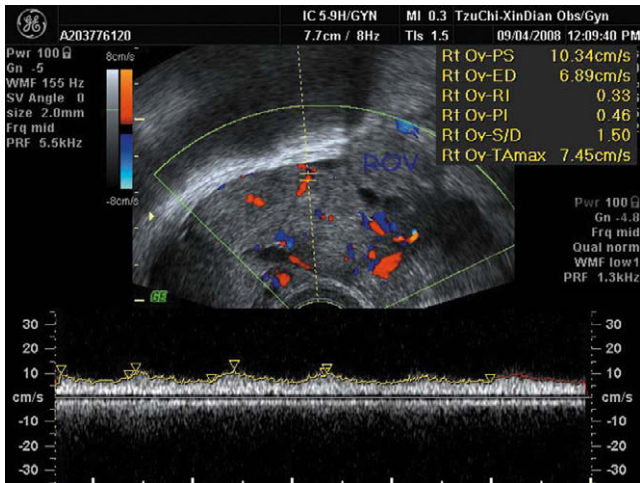


Fig. 1 — Transvaginal ultrasonography shows a sausage-shaped solid mass measuring 7×3 cm alongside the right ovary (ROV). Doppler flow indicates a flow with a resistance index of 0.33.

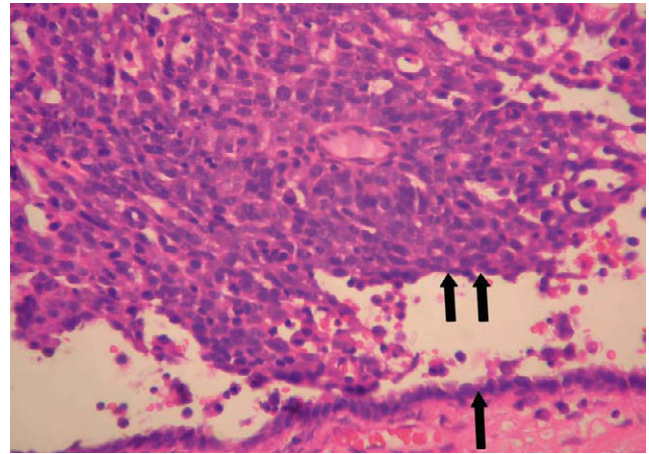


Fig. 3 — Adenocarcinoma of the fallopian tube (hematoxylin & eosin, 400×). The tumor (double arrows) contains pseudolumina and hyperchromatic nuclei within the neoplastic cells. A portion of the fallopian tube (single arrow) is presented in the lower portion of the figure.

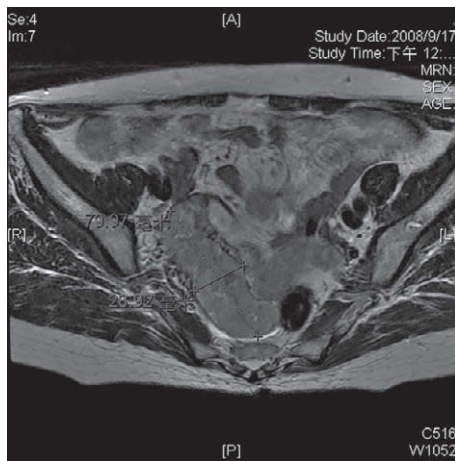


Fig. 2 — Magnetic resonance imaging shows a tubular tumor mass (7.99×2.89 cm) in the right pelvic cavity r/o salpinx tumor.

ascites (Fig. 2). She underwent total hysterectomy, bilateral salpingo-oophorectomy, infracolic omentectomy, and pelvic and para-aortic lymph node sampling. No macroscopic disease was left following the operation.

Microscopically, sections of right fallopian tube and ovary showed the presence of moderately differentiated adenocarcinoma that was characterized by crowded complex branching neoplastic glands with a cribriform to glandular architecture or back-to-back glands without intervening stroma. The tumor cells exhibited dot-like nucleoli within hyperchromatic nuclei with mild to moderate pleomorphism, coarse chromatin and mild mitotic figures. The serosal layers were unremarkable (Fig. 3). There were no metastatic

tumors in the pelvic and para-aortic lymph nodes, and the abdominal cytology was negative. The FIGO stage was assessed to be stage IIA.

Two months later, the patient was treated with six courses of adjuvant chemotherapy including taxol/cisplatin chemotherapy. CA125 decreased to a normal level after two courses of chemotherapy. One year after the operation, MRI revealed no evidence of recurrence and CA125 levels remained normal. The patient continues to receive regular follow-up at our hospital.

3. Discussion

The most common presentation of fallopian tube cancer is vaginal bleeding and discharge (50–60%) followed by abdominal pain (30–49%) and abdominal mass (12–61%) [1–4]. Abdominal pain can be colicky (as a result of forced tubal peristalsis) or dull (as a result of tube distension). Latzko's triad of symptoms, consisting of intermittent profuse serosanguineous vaginal discharge, colicky pain relieved by discharge, and an abdominal or pelvic mass, is reported in only 15% of patients [2–4]. Most patients have a delay in diagnosis, and early clinical suspicion helps early diagnosis. In our case, the patient presented only with right lower abdominal dull pain but did not have serosanguineous vaginal discharge or postmenopausal bleeding. A pap smear was normal.

The sonographic appearance of fallopian tube carcinoma can be nonspecific and may mimic other pelvic diseases such as tubo-ovarian abscess, ovarian tumor, and ectopic pregnancy. Reported features include a sausage-shaped mass, cystic spaces with mural nodules and a multilobular mass with a cog and wheel

appearance in the adnexal region (5–8). Low impedance vascular flow within the solid components has been observed in some cases (5–8). In our case, transvaginal ultrasonography showed a sausage-shaped solid mass measuring 7×3 cm alongside the right ovary. Doppler flow showed low vascular impedance with a resistance index of 0.33. With both computed tomography (CT) and MRI, the lesion can appear relatively solid, and lobulated when not associated with hydrosalpinx. Associated CT and MRI findings include peritumoral ascites, intrauterine fluid collection, and hydrosalpinx (9,10). Importantly, MRI is superior to CT and ultrasound when identifying local tumor infiltration of the bladder, pelvic fat, vagina, pelvic sidewalls, and bowel (9,10).

Serum CA125 is used routinely as a tumor marker for diagnosis, assessing response to treatment and follow-up of epithelial ovarian cancer. Although CA125 is not diagnostic of fallopian tube cancer, more than 80% patients have elevated pretreatment serum CA125 levels and 87% of tumor tissues stain positively for CA125 (11,12). Pretreatment serum CA125 level is an independent prognostic factor of disease-free status and overall survival in patients with fallopian tube cancer. If elevated, serum CA125 level also adequately defines the response to chemotherapy (11,12). In 90% of patients, an increase in serum CA125 level precedes clinical or radiological diagnosis of recurrent disease with a median lead time of 3 months (range, 0.5–7 months) (11,12). In our case, the patient had an elevated pretreatment serum CA125 level of 173 U/mL, which decreased to a normal level after two courses of chemotherapy. One year postoperatively, her CA125 levels remain normal.

The diagnosis of fallopian tube carcinoma is not often made preoperatively and may not be made even on initial surgery. This means that correct staging may not be performed at the time of the initial operation. In advanced disease, postoperative residual disease larger than 2 cm can have an adverse prognostic impact (13–16). Aggressive debulking should be attempted in patients with an advanced tumor. Surgery should consist of bilateral salpingo-oophorectomy, total abdominal hysterectomy, and comprehensive surgical staging (13–16). Patients with advanced disease should undergo paclitaxel-containing regimens, including cisplatin/carboplatin and a standard combination of cyclophosphamide, adriamycin, and platinum (CAP) chemotherapies (17–22). Our patient underwent total hysterectomy, bilateral salpingo-oophorectomy, infracolic omentectomy, and pelvic lymph node and para-aortic sampling. No macroscopic disease was left following the operation. There were no metastatic tumors present in the pelvic and para-aortic lymph nodes and the abdominal cytology was negative. The FIGO stage

was assessed to be stage IIA. Two months later, the patient was treated by adjuvant chemotherapy including cisplatin/taxol chemotherapy, and CA125 decreased to a normal level after two courses of chemotherapy.

In summary, primary carcinoma of the fallopian tube can be strongly suspected preoperatively on the basis of its characteristic clinical symptoms, an elevated CA125 level, a transvaginal sonographic investigation, and MRI findings.

References

- Rosenblatt KA, Weiss NS, Schwartz SM. Incidence of malignant fallopian tube tumors. *Gynecol Oncol* 1989;35:236–9.
- Woolas RP, Smith JHF, Sarharnis P, et al. Fallopian tube carcinoma: an under-recognized primary neoplasm. *Int J Gynecol Cancer* 1997;7:284–8.
- Halperin R, Zehaviy S, Herman A, et al. Fallopian tube carcinoma presenting as tubo-ovarian abscess: a report of two cases with literature review. *Int J Gynecol Cancer* 2005;15:1131–4.
- Nordin AJ. Primary carcinoma of the fallopian tube: a 20-year literature review. *Obstet Gynecol Surv* 1994;49:349–61.
- Obermair A, Taylor KH, Janda M, et al. Primary fallopian tube carcinoma: the Queensland experience. *Int J Gynecol Cancer* 2001;11:69–72.
- Subramanyam BR, Raghavendra BN, Whalen CA, Yee J. Ultrasonic features of fallopian tube carcinoma. *J Ultrasound Med* 1984;3:391–3.
- Ajjimakorn S, Bhamarapavati Y, Israngura N. Ultrasound appearance of fallopian tube carcinoma. *J Clin Ultrasound* 1988;16:516–8.
- Kol S, Gal D, Friedman M. Preoperative diagnosis of fallopian tube carcinoma by transvaginal sonography and CA-125. *Gynecol Oncol* 1990;37:129–31.
- Kurachi H, Maeda T, Murakami T, et al. A case of fallopian tube carcinoma: successful preoperative diagnosis with MR imaging. *Radiat Med* 1999;17:63–6.
- Kawakami S, Togashi K, Kimura I, et al. Primary malignant tumor of the fallopian tube: appearance at CT and MR imaging. *Radiology* 1993;186:503–8.
- Hefler LA, Rosen AC, Graf AH, et al. The clinical value of serum concentrations of cancer antigen 125 in patients with primary fallopian tube carcinoma: a multicenter study. *Cancer* 2000;89:1555–60.
- Tokunaga T, Miyazaki K, Matsuyama S, et al. Serial measurement of CA-125 in patients with primary carcinoma of the fallopian tube. *Gynecol Oncol* 1990;36:335–7.
- Rosen A, Klein M, Lahousen M, et al. Primary carcinoma of the fallopian tube—a retrospective analysis of 115 patients. Austrian Cooperative Study Group for Fallopian Tube Carcinoma. *Br J Cancer* 1993;68:605–9.
- Peters WA III, Andersen WA, Hopkins MP, et al. Prognostic features of carcinoma of the fallopian tube. *Obstet Gynecol* 1988;71:757–62.
- Alvarado-Cabrero I, Young RH, Vamvakas EC, et al. Carcinoma of the fallopian tube: a clinicopathological study of 105 cases with observations on staging and prognostic factors. *Gynecol Oncol* 1999;72:367–79.

16. Gadducci A, Landoni F, Sartori E, et al. Analysis of treatment failures and survival of patients with fallopian tube carcinoma: a Cooperation Task Force (CTF) study. *Gynecol Oncol* 2001;81:150–9.
17. Barakat RR, Rubin SC, Saigo PE, et al. Cisplatin-based combination chemotherapy in carcinoma of the fallopian tube. *Gynecol Oncol* 1991;42:156–60.
18. Pectasides D, Barbounis V, Sintila A, et al. Treatment of primary fallopian tube carcinoma with cisplatin-containing chemotherapy. *Am J Clin Oncol* 1994;17:68–71.
19. Cormio G, Maneo A, Gabriele A, et al. Treatment of fallopian tube carcinoma with cyclophosphamide, adriamycin, and cisplatin. *Am J Clin Oncol* 1997;20:143–5.
20. Wagenaar HC, Pecorelli S, Vergote I, et al. Phase II study of a combination of cyclophosphamide, adriamycin and cisplatin in advanced fallopian tube carcinoma. An EORTC gynecological cancer group study. European Organization for Research and Treatment of Cancer. *Eur J Gynaecol Oncol* 2001;22:187–93.
21. Morris M, Gershenson DM, Burke TW, et al. Treatment of fallopian tube carcinoma with cisplatin, doxorubicin, and cyclophosphamide. *Obstet Gynecol* 1990;76:1020–4.
22. Kosary C, Trimble EL. Treatment and survival for women with Fallopian tube carcinoma: a population-based study. *Gynecol Oncol* 2002;86:190–1.