



Case Report

Nonfatal Gastric Mucormycosis Associated With Emphysematous Gastritis

Wei-Feng Feng¹, Chih-En Tseng^{2,3}, Chih-Wen Lin⁴, Kuo-Chih Tseng^{1,3*}

¹Division of Gastroenterology, Department of Internal Medicine, Buddhist Dalin Tzu Chi General Hospital, Chiayi, Taiwan

²Department of Pathology, Buddhist Dalin Tzu Chi General Hospital, Chiayi, Taiwan

³School of Medicine, Tzu Chi University, Hualien, Taiwan

⁴Department of Radiology, Buddhist Dalin Tzu Chi General Hospital, Chiayi, Taiwan

Article info

Article history:

Received: June 19, 2009

Revised: July 6, 2009

Accepted: July 31, 2009

Keywords:

Emphysema gastritis

Mucormycosis

Stomach

Abstract

Emphysematous gastritis is a rare, often fatal disease characterized by the presence of gas within the walls of the stomach and diffuse gastric wall inflammation due to gas-forming bacteria. Gastric mucormycosis is a rare manifestation of invasive fungal disease, ranging from colonization of peptic ulcers to infiltrative disease with vascular invasion and dissemination. The combination of the two conditions is rare. There are a few reports in the literature of invasive gastric mucormycosis associated with emphysematous gastritis that were fatal. Here, we present a case of invasive gastric mucormycosis associated with emphysematous gastritis for which medical management was successful. (*Tzu Chi Med J* 2010;22(3): 146–148)

*Corresponding author. Division of Gastroenterology, Department of Internal Medicine, Buddhist Dalin Tzu Chi General Hospital, 2, Min-Sheng Road, Dalin, Chiayi, Taiwan.
E-mail address: tsengkuochih@gmail.com

1. Introduction

Emphysematous gastritis is an often fatal, rare clinical entity consisting of gastric wall inflammation, systemic toxicity, and the radiological appearance of air bubbles in the stomach walls secondary to gas production by bacteria. Predisposing factors include ingestion of corrosive substances, alcohol abuse, recent abdominal surgery or gastroenteritis (1). Prognosis is grave, with a reported mortality rate of 61%, which has remained constant since the earliest reports (2).

Mucormycosis is a term used for infections caused by molds of the order Mucorales. Certain conditions predispose to tissue invasion by these saprophytic fungi, including diabetes mellitus, metabolic acidosis, leukemia, lymphoma, corticosteroid therapy, severe malnutrition, organ transplantation, extensive burns,

uremia, deferoxamine-based therapy, use of contaminated bandages and tongue depressors (3,4). Mucormycosis is usually an acute, fulminant infection characterized pathologically by the invasion of major blood vessels, with resultant ischemia and infarction of adjacent tissue. Mixed infections with other fungi and bacteria are common. A recent review reported in the literature showed only 10 survivors out of 50 primary gastric mucormycosis cases (5).

Isolation of fungi from cases of emphysematous gastritis has been rare. Until now, there have been only a few reports of gastric mucormycosis associated with emphysematous gastritis found in the literature, and the results were fatal (6,7). Here, we present a case of invasive gastric mucormycosis associated with emphysematous gastritis for which medical management was successful.

2. Case report

A 57-year-old man presented to our emergency department with fever, shortness of breath, and right upper quadrant pain. He had medical comorbidities of chronic hepatitis B and chronic obstructive pulmonary disease with irregular steroid use. On admission, the laboratory data were: AST, 13,348 IU/L (<41 IU/L); ALT, 7701 IU/L (<41 IU/L); total bilirubin, 2.6 mg/dL (<1.2 mg/dL); blood urea nitrogen, 83 mg/dL (<20 mg/dL); creatinine, 5.5 mg/dL (<1.2 mg/dL); white cell count, 26,590/ μ L (<9600/ μ L); fibrin degradation product, 28.8 μ g/mL (<5 μ g/mL); and D-dimer, 9126 ng/mL (<500 ng/mL). Septic shock with multi-organ failure, involving liver, kidney, lung and coagulopathy was diagnosed. He was intubated for ventilation support.

Intravenous penicillin G 3 MU every 6 hours, levofloxacin 250mg every other day, and cefepime 1000mg/day were used empirically. The antibiotics were shifted to intravenous meropenem 1000mg every 12 hours and vancomycin 1000mg every other day because of the persistent critical condition. Blood cultures showed no growth of bacteria or fungus. Ventilator-associated pneumonia occurred later. Sputum cultures grew *Staphylococcus aureus* and *Hemophilus influenzae*.

On day 12 of admission, we found coffee-ground substance in the nasogastric tube. Esophagogastroduodenoscopy revealed a 6 \times 7-cm round ulcer with a brown-greenish coating on the base over the greater curvature of the body (Fig. 1). Histology disclosed an ulcer with exudates, granulation tissue and fibrin deposits. No *Helicobacter pylori* was found. Under hematoxylin and eosin staining (400 \times , Fig. 2A) and Grocott's methenamine silver staining (400 \times , Fig. 2B),

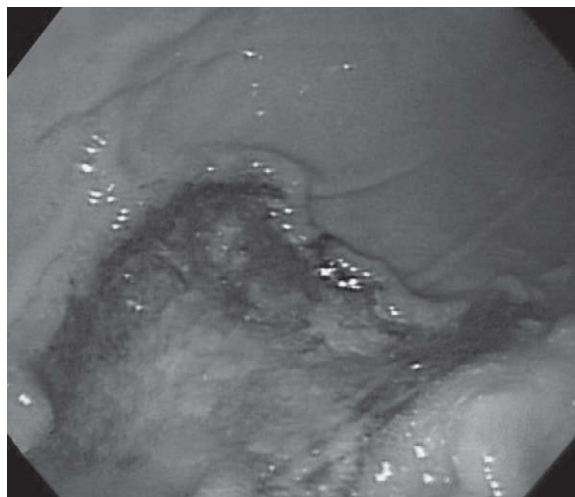


Fig. 1 — Endoscopic view showing a well-defined giant round ulcer with brown-greenish coating on the base over the greater curvature of the body.

many proliferating, nonseptate fungal hyphae with right angle branching were detected that were morphologically consistent with mucormycosis. In addition, he had sphenoid sinusitis but no mucormyces was isolated from nasal sinus fluid.

Contrast-enhanced computed tomography of the abdomen showed a collection of intramural gas over the greater curvature side of the gastric body (Fig. 3). Surgical intervention was not performed due to the patient's poor medical condition. A 21-day course of intravenous liposomal amphotericin B was administered intravenously at a dose of 200mg/day. The patient had a gradual recovery.

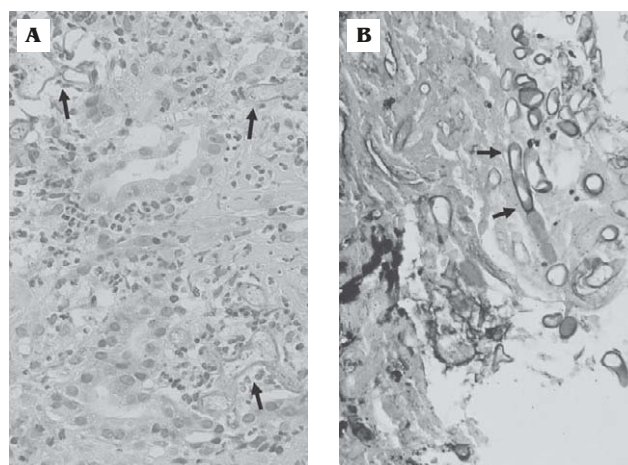


Fig. 2 — Histopathologic photomicrograph showing numerous nonseptate hyphal elements with right angle branching indicative of mucormyces (arrows). (A) Hematoxylin and eosin stain (400 \times). (B) Grocott's methenamine silver stain (400 \times).

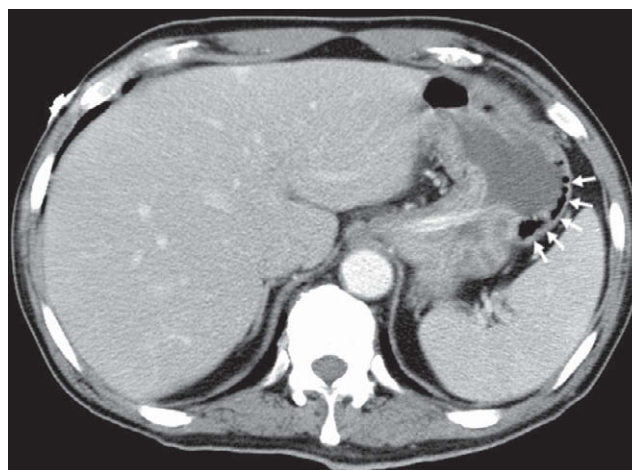


Fig. 3 — Contrast-enhanced computed tomography of the abdomen showing a collection of intramural gas over the greater curvature side of the gastric body (arrows), indicative of emphysematous gastritis.

Follow-up liver function showed rapid return to normal levels, which implied that the acute hepatitis was due to shock. Renal function had deteriorated to creatinine 10.0mg/dL on the 9th day of admission, then gradually improved to normal levels 1 month after admission. The gastric ulcer healed 1 month after the episode, which was documented by esophagogastroduodenoscopy. The patient remained well during the 11-month follow-up period.

3. Discussion

Emphysematous gastritis is a rare fatal disorder. In patients with emphysematous gastritis, broad-spectrum antibiotics for Gram-negative rods and anaerobes should be administered. Indications for surgical intervention include perforation, necrosis, ischemia, or failure of conservative management (2,8).

The most frequent sites of mucormycosis are the lungs (81%), central nervous system (27%), sinuses (16%), liver (16%) and orbital space (10%) (9). The gastrointestinal tract was involved in only 7% of cases (10). The most common gastrointestinal organ affected is the stomach (67%), followed by the colon (21%), small intestine (4%), and esophagus (2%) (10). Abdominal pain and bloody diarrhea are two typical manifestations. Predisposing factors for invasive gastric mucormycosis include malnutrition, renal insufficiency, immunosuppression, other infections, antibiotic use, and diabetes (10). In our case, the patient suffered from chronic obstructive pulmonary disease with steroid use that rendered the patient susceptible to Mucorales infection. Furthermore, the most commonly associated condition is the presence of a preexisting gastric ulcer (11). It is possible that the denuded gastric ulcer base in a compromised host allows the bacteria and fungi to invade deeply, leading to gastric wall necrosis and intramural gas production.

Definitive diagnosis of mucormycosis requires histopathologic evidence of fungal invasion of tissues (3). The direct detection of fungus in tissues was significantly more sensitive than in cultures (12). Mucorales readily stains with periodic acid-Schiff, methenamine silver, and routine hematoxylin and eosin stains (4). Histopathologic sections show broad (3–25 mm in diameter), thin-walled, mostly aseptate hyphae. Frequently, these hyphae show focal bulbous dilation and nondichotomous, irregular branching that occasionally occurs at right angles (3).

Making recommendations for treatment of gastric mucormycosis is difficult because it is a rare condition and is usually associated with a fatal outcome. The therapy of mucormycosis includes surgical debridement of all necrotic tissue, amphotericin B treatment, and aggressive metabolic support (13). Because mucormycosis is a highly angioinvasive infection

with resulting extensive thrombosis and tissue necrosis, antifungal agents often display poor penetration at the site of the infection. Early surgical debridement of the infected tissue should be performed before the infection disseminates to other organs (3). The mortality rate was 55% in patients who received antifungal agents alone versus 27% in patients who received antifungal agents and underwent surgery for pulmonary mucormycosis (14). In our case, however, only medical treatment was given due to his poor medical condition, yet the patient survived.

In conclusion, we present a rare case of a patient who manifested a combination of emphysematous gastritis and gastric mucormycosis. The patient was successfully managed using intensive medical therapy.

References

1. Yalamanchili M, Cady W. Emphysematous gastritis in a hemodialysis patient. *South Med J* 2003;96:84–8.
2. Carlson AP, Chan JW, Ketali LH, Demarest GB. Emphysematous gastritis in a severely burned patient: case report and literature review. *J Trauma* 2007;62:765–7.
3. Kontoyiannis DP, Lewis RE. Invasive zygomycosis: update on pathogenesis, clinical manifestations, and management. *Infect Dis Clin North Am* 2006;20:581–607.
4. Rinaldi MG. Zygomycosis. *Infect Dis Clin North Am* 1989;3:19–41.
5. Berne JD, Villarreal DH, McGovern TM, Rowe SA, Moore FO, Norwood SH. A fatal case of posttraumatic gastric mucormycosis. *J Trauma* 2009;66:933–5.
6. Cherney CL, Chutuape A, Fikrig MK. Fatal invasive gastric mucormycosis occurring with emphysematous gastritis: case report and literature review. *Am J Gastroenterol* 1999;94:252–6.
7. Jung JH, Choi HJ, Yoo J, Kang SJ, Lee KY. Emphysematous gastritis associated with invasive gastric mucormycosis: a case report. *J Korean Med Sci* 2007;22:923–7.
8. Moosvi AR, Saravolatz LD, Wong DH, Simms SM. Emphysematous gastritis: case report and review. *Rev Infect Dis* 1990;12:848–55.
9. Pagano L, Ricci P, Tonso A, et al. Mucormycosis in patients with haematological malignancies: a retrospective clinical study of 37 cases. GIMEMA Infection Program (Gruppo Italiano Malattie Ematologiche Maligne dell'Adulto). *Br J Haematol* 1997;99:331–6.
10. Lyon DT, Schubert TT, Mantia AG, Kaplan MH. Phycomycosis of the gastrointestinal tract. *Am J Gastroenterol* 1979;72:379–94.
11. Thomson SR, Bade PG, Taams M, Chrystal V. Gastrointestinal mucormycosis. *Br J Surg* 1991;78:952–4.
12. Tarrand JJ, Lichtenfeld M, Warraich I, et al. Diagnosis of invasive septate mold infections. A correlation of microbiological culture and histologic or cytologic examination. *Am J Clin Pathol* 2003;119:854–8.
13. Martinez EJ, Cancio MR, Sinnott JT 4th, Vincent AL, Brantley SG. Nonfatal gastric mucormycosis in a renal transplant recipient. *South Med J* 1997;90:341–4.
14. Lee FY, Mossad SB, Adal KA. Pulmonary mucormycosis: the last 30 years. *Arch Intern Med* 1999;159:1301–9.