



## Case Report

## Rare Type of Deep Neck Infection: Two Cases of Descending Necrotizing Mediastinitis

Shih-Ming Huang<sup>1</sup>, Ren-Chieh Wu<sup>1,2\*</sup>

<sup>1</sup>Department of Emergency Medicine, Buddhist Tzu Chi General Hospital, Hualien, Taiwan

<sup>2</sup>School of Medicine, Tzu Chi University, Hualien, Taiwan

### Article info

#### Article history:

Received: October 6, 2008

Revised: October 28, 2008

Accepted: November 11, 2008

#### Keywords:

Deep neck infection

Mediastinitis

Necrotizing fasciitis

### Abstract

Descending necrotizing mediastinitis is a relatively uncommon complication of deep neck infections. Patients often have some type of immunocompromised condition. Computed tomography is very helpful for early diagnosis. Poor prognosis is due to delays in diagnosis or inappropriate surgical drainage. We present two cases of descending necrotizing mediastinitis that was successfully treated because of early diagnosis and adequate surgical intervention. (*Tzu Chi Med J* 2009;21(4):348–351)

\*Corresponding author. Department of Emergency Medicine, Buddhist Tzu Chi General Hospital, 707, Section 3, Chung-Yang Road, Hualien, Taiwan.

E-mail address: rcw@tzuchi.com.tw

## 1. Introduction

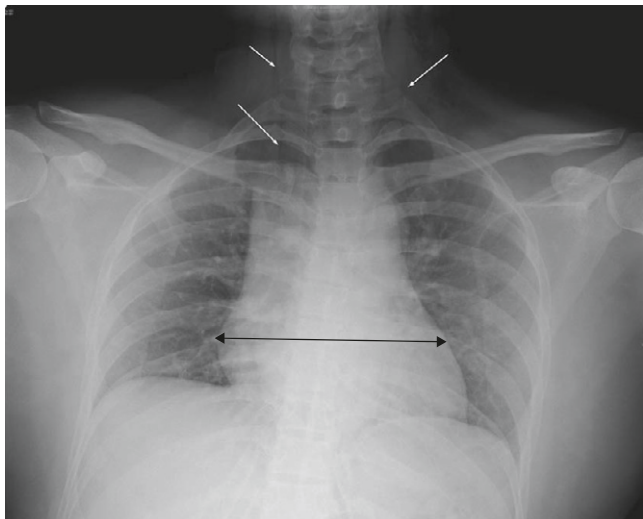
Descending necrotizing mediastinitis (DNM) occurs as a complication of odontogenic infection or deep neck infections such as peritonsillar abscess, post-traumatic neck abscess, suppurative parotitis, or Ludwig's angina. Neck infections, which are usually self-limiting and localized, may rapidly spread downward to the mediastinum, pleural cavities, and pericardium. Although computed tomography (CT) has been used as a diagnostic aid, delayed diagnoses and inappropriate drainage of the mediastinum are the main causes of the high mortality rate of 25–38% (1). Two patients with DNM who were diagnosed early and successfully treated with appropriate surgical approaches are reported here. The diagnosis of DNM of the two cases was confirmed with CT and operative findings. Gas collection was noted from the neck to the mediastinum and was the major evidence of DNM; however, there was no pathologic proof.

## 2. Case reports

### 2.1. Case 1

A 48-year-old woman complained of a toothache but did not receive any odontotherapy for 3 months. She presented to our hospital with painful swelling on the left side of her face after a tooth extraction about 8 hours prior to admission. She had underlying diabetes mellitus that was poorly controlled, and her blood sugar was 149 mg/dL on arrival. There was no complaint of trismus, dysphagia, odynophagia, dysphonia, hoarseness, stridor or dyspnea. The only discomfort was facial swelling and tenderness that extended to the neck region. On examination, there was swelling from the left eyebrow to the neck with palpable crepitus and local heat sensation. X-rays of her chest showed abnormal linear low density shadow at the neck bilaterally, hyperlucency of the supraclavicular region bilaterally and widening mediastinum

(Fig. 1). Findings from neck and chest CT showed soft-tissue swelling of the left buccal region with extensive gas collection in the left side of the face, the lower neck area bilaterally, and the mediastinum. No fluid collection was noted (Fig. 2).

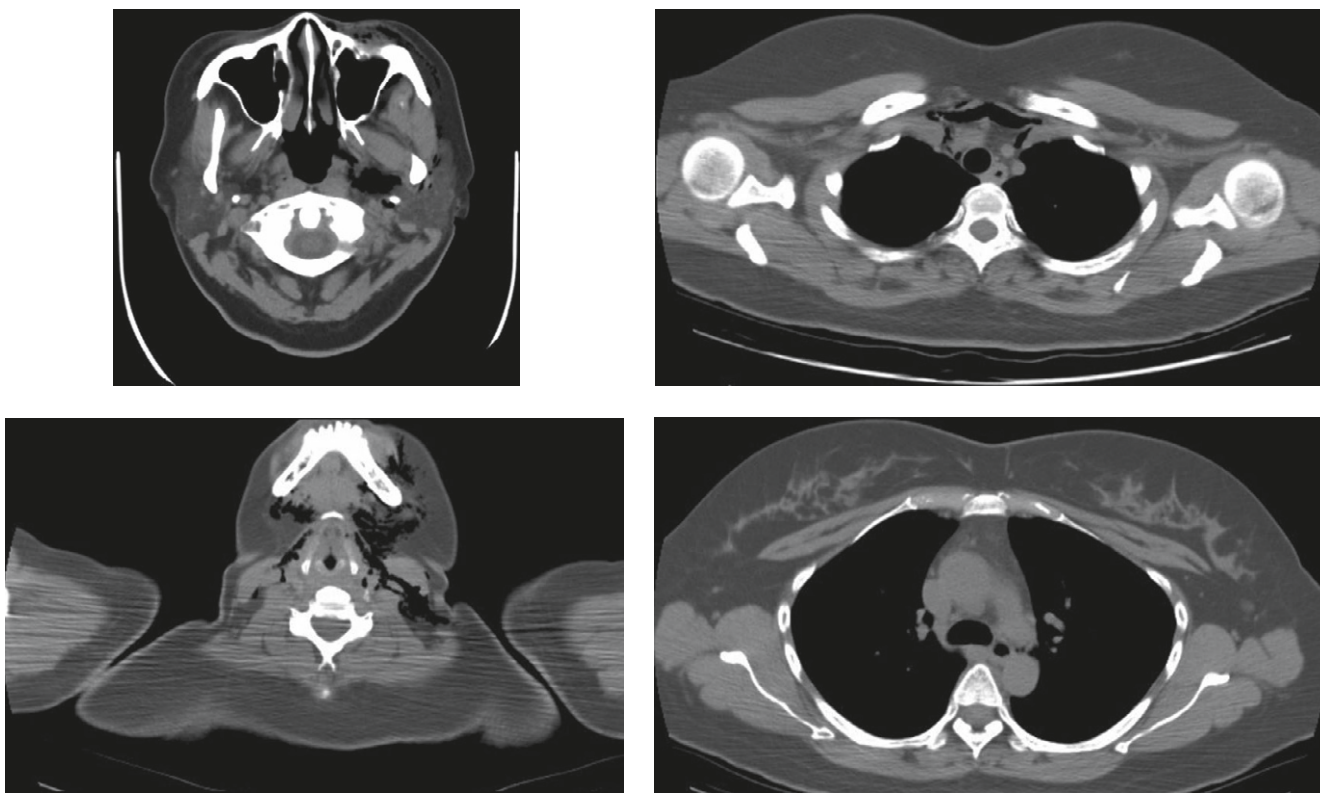


**Fig. 1** — Chest X-ray shows abnormal linear low density shadow at the neck bilaterally (white arrows), suggesting emphysematous collection, as well as widening mediastinum (black arrow).

Tracheotomy and left cervical drainage were performed through a submandibular incision, the parapharyngeal and pretracheal spaces were explored, and four drainage tubes were inserted. Gas collection was found in the subcutaneous space. As there was no definite mediastinal fluid collection, the otolaryngological surgeon decided not to perform any surgical intervention, and no culture was taken. Systemic amoxicillin and clavulanate were administered and the patient's condition improved progressively in the general ward. Cervical debridement and tracheotomy were repaired 5 days after the operation and the patient was discharged on the 7<sup>th</sup> day of admission.

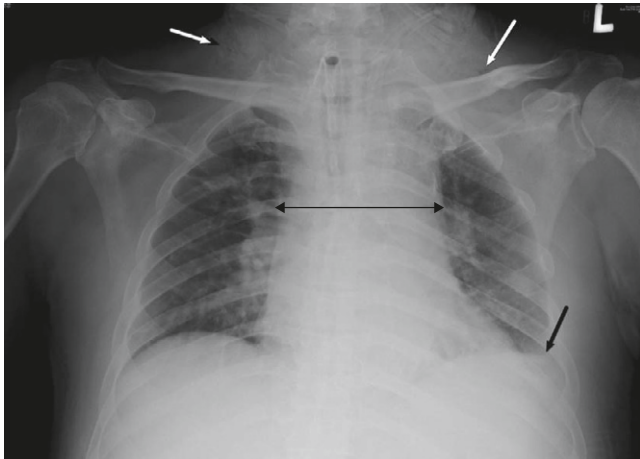
## 2.2. Case 2

A 57-year-old man developed a sore throat and fever sensation for 1 week without any history of recent odontotherapy or trauma. Fever and swelling of the neck progressed gradually. He had poorly controlled diabetes mellitus and liver cirrhosis associated with hepatitis C. Chest X-ray at a local hospital showed air in the subcutaneous tissue of the neck and a tentative diagnosis of subcutaneous emphysema was made. The patient was transferred to our hospital for



**Fig. 2** — Computed tomography shows extensive gas collection from the left side of the face to the mediastinum through the parapharyngeal and pretracheal spaces. Emphysematous change is localized in the upper mediastinum above the tracheal bifurcation.

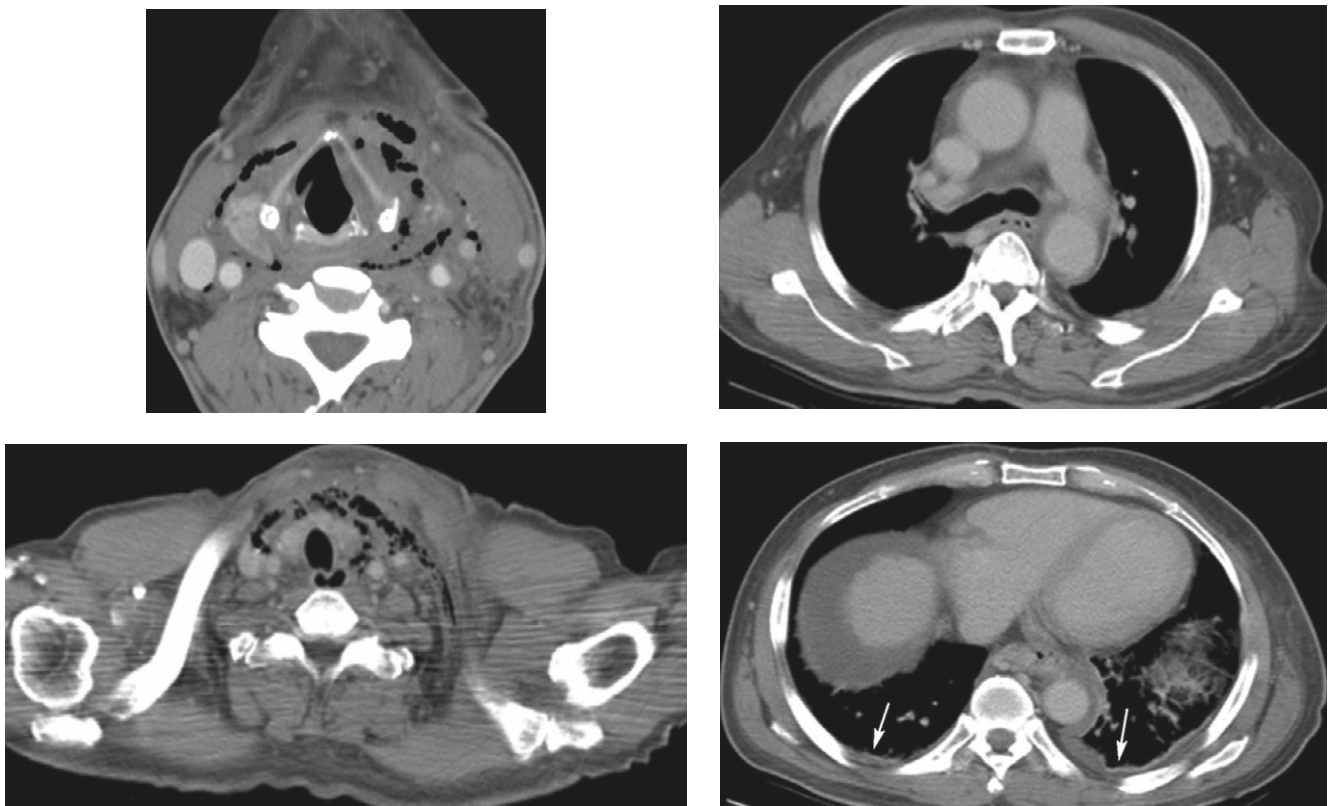
suggested cervical infection or rupture of the tracheobronchial tree. Findings from chest X-rays showed subcutaneous emphysema of the neck region bilaterally and widening mediastinum (Fig. 3). Neck and



**Fig. 3** — Chest X-ray shows hyperlucency of the neck bilaterally, suggesting subcutaneous emphysema (white arrows). Widening mediastinum and blunting of the left lateral costophrenic angle (black arrows) are also revealed.

chest CT showed bilateral pleural effusion, marked swelling with liquefaction and emphysematous collection in the parapharyngeal space and retropharyngeal soft tissue of the cervical spine that extended to the upper anterior chest wall and anterior mediastinum (Fig. 4).

Tracheostomy and bilateral cervical drainage and debridement were performed through a submandibular incision. The parapharyngeal and pretracheal spaces were also explored bilaterally. The pus and necrotic tissue were dissected from the neck and a total of eight drainage tubes were implanted. Irrigation of the wounds with saline from the cervical drainage tubes was performed twice per day for 6 days. Bacterial culture of the pus revealed *Klebsiella pneumoniae* and systemic administration of the antibiotics amoxicillin, clavulanate and metronidazole was carried out. Metronidazole was used for possible anaerobic Gram-negative bacilli infection. The general condition of the patient improved. Vomiting with coffee-ground material was noted 5 days after admission. After being transferred to the gastrointestinal ward, panendoscopy revealed severe rupture of esophageal varices with active bleeding. He was admitted to the intensive care unit. After several blood



**Fig. 4** — Computed tomography shows marked soft tissue swelling with liquefaction and emphysematous collection in the parapharyngeal, pretracheal and retropharyngeal spaces. Mediastinal collection with air and fluid extend to the upper anterior chest wall and anterior mediastinum above the tracheal bifurcation (type I). Bilateral pleural effusion is noted (white arrows).

transfusions and vasopressin were given, his general condition improved and he was transferred to the general ward after a 3-day stay in the intensive care unit. Twenty days after tracheostomy and pus drainage, the tracheostomy and open wounds had closed and his general condition was much improved. He was discharged after 30 days in the hospital.

### 3. Discussion

Odontogenic and oropharyngeal infections are relatively common in the cervicocephalic region. DNM was first described by Pearse (2) as a serious infection involving the mediastinal soft tissue caused by an oropharyngeal abscess spreading downward to the mediastinum through the loose anatomic structure of the retropharyngeal, parapharyngeal and pretracheal spaces with the help of gravity and negative intrathoracic pressure. Pearse reported mortality rates of 86% in nonsurgical patients and 35% in surgical patients (2). Due to the use of antibiotics, the mortality rate has fallen to about 25% in the last decade (3). Delayed diagnosis and inappropriate surgical approaches are two of the main reasons for the high mortality rate in patients with DNM. CT is critical for determining the level of infection and for monitoring treatment progress. Furthermore, CT surveillance is recommended to ensure the adequacy of drainage and to identify unsuspected progression of DNM (4). Aggressive surgical drainage with intravenous broad-spectrum antibiotics is essential in the primary treatment of DNM. Broad-spectrum penicillin such as ampicillin/sulbactam provides extended coverage against oral anaerobes, including those that produce beta-lactamases, and is the treatment of choice. Penicillin G in combination with metronidazole, an agent active against anaerobic Gram-negative bacilli, is an alternative regimen. Patients allergic to penicillin should be treated with clindamycin (5).

Tracheostomy is indicated for severe or impending airway obstruction when trismus or massive soft tissue edema precludes endotracheal intubation or when repeated attempts at intubation have failed (6).

Several authors (7–9) have reported that patients with immune system deficiencies, mainly diabetes mellitus, are more predisposed to developing DNM. In our two cases, both were diagnosed with type II diabetes mellitus that was not adequately controlled. In Case 2, the patient also had a history of liver cirrhosis. The Kupffer cells in the liver are part of the reticuloendothelial system and the immune system, which consists of the phagocytic cells located in reticular connective tissue. Decreased reticuloendothelial system phagocytic activity in patients with liver cirrhosis may reduce plasma bacteria elimination rate.

Therefore, immune system deficiencies in our two cases were also noted.

The authors recommend early combined drainage using neck and chest incisions. Endo et al (10) classified the degree of DNM based on the results of CT. Type I DNM is localized in the upper mediastinum above the tracheal bifurcation and may not always require aggressive mediastinal drainage (3), trans-cervical drainage should be adequate (11). Type IIA DNM extends to the lower anterior mediastinum, and trans-cervicotomy and anterior mediastinal drainage through a subxiphoidal incision are recommended (3,11). Type IIB DNM extends to the anterior and lower posterior mediastinum and demands complete mediastinal drainage such as cervicotomy with video-assisted mediastinal drainage (3,11). Our two patients were classified with type I DNM; cervical drainage was feasible and effective, and both patients recovered well.

### References

1. Freeman RK, Vallieres E, Verrier ED, Karmy-Jones R, Wood DE. Descending necrotizing mediastinitis: an analysis of the effects of serial surgical debridement on patient mortality. *J Thorac Cardiovasc Surg* 2000;119:260–7.
2. Pearse HE. Mediastinitis following cervical suppuration. *Ann Surg* 1938;107:588–611.
3. Rocca F, Pecorari GC, Oliaro A, et al. Ten years of descending necrotizing mediastinitis: management of 23 cases. *J Oral Maxillofac Surg* 2007;65:1716–24.
4. Pinto A, Scaglione M, Scuderi MG, Tortora G, Daniele S, Romano L. Infection of the neck leading to descending necrotizing mediastinitis: role of multi-detector row computed tomography. *Eur J Radiol* 2008;65:389–94.
5. Brook I. Antibiotic resistance of oral anaerobic bacteria and their effect on the management of upper respiratory tract and head and neck infections. *Semin Respir Infect* 2002;17:195–203.
6. Yellon RF. Head and neck space infections. In: Bluestone CD, Casselbrant ML, Stool SE, eds. *Pediatric Otolaryngology, Volume 2*, 4<sup>th</sup> edition. Philadelphia: Saunders, 2003: 1681–701.
7. Endo S, Murayama F, Hasegawa T, et al. Guidelines for surgical management based on the diffusion of descending necrotizing mediastinitis. *Jpn J Thorac Cardiovasc Surg* 1999;47:14–9.
8. Makeieff M, Gresillon N, Berthet JP, et al. Management of descending necrotizing mediastinitis. *Laryngoscope* 2004; 114:772–5.
9. Novellas S, Kechabtia K, Chevallier P, Sedat J, Bruneton JN. Descending necrotizing mediastinitis: a rare pathology to keep in mind. *Clin Imaging* 2005;29:138–40.
10. Endo S, Tsubochi H, Nakano T, Sohara Y. Descending necrotizing mediastinitis secondary to retropharyngeal abscess without cervical spread. *Gen Thorac Cardiovasc Surg* 2008;56:25–7.
11. Chen KC, Chen JS, Kuo SW, et al. Descending necrotizing mediastinitis: a 10-year surgical experience in a single institution. *J Thorac Cardiovasc Surg* 2008;136:191–8.