



Case Report

Late-onset Methemoglobinemia Induced by Metobromuron/metolachlor

Bang-Gee Hsu^{1,2}, Han-Yu Huang^{2,3,4*}

¹Division of Nephrology, Buddhist Tzu Chi General Hospital, Hualien, Taiwan

²School of Medicine, Tzu Chi University, Hualien, Taiwan

³Division of Medical Intensive Care Unit, Department of Internal Medicine, Buddhist Tzu Chi General Hospital, Hualien, Taiwan

⁴Institute of Medical Sciences, Tzu Chi University, Hualien, Taiwan

Article info

Article history:

Received: September 18, 2008

Revised: October 16, 2008

Accepted: December 11, 2008

Keywords:

Methemoglobinemia

Metobromuron

Metolachlor

Methylene blue

Abstract

The herbicide, Galex, containing 25% of metolachlor and 25% of metobromuron dissolved in 46.7% emulsifiable concentrate was widely used for the control of grasses and broad-leaf weeds in the 1990s and continues to be used today. Metobromuron, a substitute urea herbicide, may cause methemoglobinemia in humans, but very few studies are available about the harmful effects on humans. We report here a case where a 47-year-old man developed severe methemoglobinemia 10 hours after ingestion of 1000 mL of Galex. Acute hypoxic respiratory failure with coma occurred suddenly. After ventilator support was instituted, intravenous methylene blue (1%, 2 mg/kg) was administered immediately. A second dose of methylene blue was given because of a persistent high level of methemoglobin 2 hours later. The patient was weaned from the ventilator on day 4. However, hemolytic anemia, possibly due to the administration of methylene blue, occurred and persisted to day 11. This resolved gradually only after multiple blood transfusions. Ingestion of a large volume of herbicide containing metobromuron, a substituted urea herbicide, can induce late-onset methemoglobinemia in humans and, while rare, may be fatal if not observed for a sufficient time in the emergency department. Death is possible following the ingestion of this herbicide when adequate diagnoses and treatment are not instituted. Methylene blue is useful in reversing methemoglobinemia, but the side effects such as hemolytic anemia should be monitored, especially at doses exceeding 4 mg/kg or in patients with glucose-6-phosphate dehydrogenase (G6PD) deficiency. Clinicians should consider the relevant history of G6PD deficiency before using methylene blue to decrease the risk of unnecessary hemolytic anemia. Methemoglobinemia in patients with G6PD deficiency is best treated with blood transfusions. (*Tzu Chi Med J* 2009;21(4): 334–338)

*Corresponding author. Division of Medical Intensive Care Unit, Department of Internal Medicine, Buddhist Tzu Chi General Hospital, 707, Section 3, Chung-Yang Road, Hualien, Taiwan.

E-mail address: huanghy@tzuchi.org.tw

1. Introduction

The herbicide Galex, containing 25% of metobromuron and 25% of metolachlor dissolved in 46.7% emulsifiable concentrate, was widely used for the control of grasses and broad-leaf weeds during the 1990s and continues to be used today. Metobromuron is a substitute urea herbicide, which acts by inhibiting photosynthesis (1). Metolachlor is a herbicide from the chloroacetanilide family. Its mode of action is elongase inhibition (2). Galex herbicide consists of metobromuron in a solid dispersed form and an organic phase comprised of metolachlor dissolved in an organic hydrophobic solvent, which can increase the physical and chemical stability of both chemicals (3). The usage of metolachlor has been decreased because of the possible risk for mutation of fetuses (2). However, occasional usage still occurs. Metobromuron may cause methemoglobinemia in humans, but there are very few studies available about the harmful effects on humans (4,5). If not adequately diagnosed and treated, fatal outcomes are possible. We present a case of severe late-onset methemoglobinemia after ingestion of a large amount of Galex, which was successfully treated using methylene blue.

2. Case report

A 47-year-old man was sent to the emergency department (ED) of Tzu Chi General Hospital, 12 hours after an intentional ingestion of two bottles (500 mL per bottle) of Galex herbicide in April 2006. He had a history of suicide attempts by swallowing glyphosate 1 year prior to this event without sequelae. He was initially taken to a local hospital in a stable condition.

However, a disturbance of his consciousness and central cyanosis occurred 10 hours after ingestion, and he was unresponsive to oxygen supplement. Endotracheal intubation with mechanical ventilation was instituted. Blood methemoglobin (MetHb) levels were 58.2%. Intravenous methylene blue (1%, 2 mg/kg) was administered immediately. He was transferred to our ED in a coma. Bottles with the trade name "Galex" herbicide were brought in to the ED by his family.

On arrival to our ED, his vital signs were as follows: body temperature was 36.5°C, heart rate was 107 beats per minute, respiratory rate was 25 breaths per minute, and blood pressure was 131/74 mmHg. His Glasgow coma scale score was E1VtM1. Cyanotic lips and peripheral extremities were noted. Laboratory test results showed that white blood cell count was $17.2 \times 10^3/\mu\text{L}$, neutrophils were 92%, lymphocytes were 1%, hemoglobin was 13.4 g/dL, platelets were $209 \times 10^3/\mu\text{L}$, aspartate aminotransferase level was 19 IU/L, alanine aminotransferase level was 15 IU/L, blood urea nitrogen level was 10 mg/dL, creatinine level was 0.9 mg/dL, sodium was 140 mmol/L, and potassium was 4.4 mmol/L. Arterial blood gas data under 100% oxygen therapy showed that pH was 7.355, PaCO₂ was 38.4 mmHg, PaO₂ was 151.9 mmHg, HCO₃⁻ was 22.0 mmol/L, and SaO₂ was 99.3%. Follow-up blood MetHb levels were 43.5% at 2 hours after the first dose of methylene blue. The SaO₂ using a CO-oximeter was 83.7%. A second dose of methylene blue (1%, 2 mg/kg) was administered.

The patient was admitted to our medical intensive care unit and his consciousness had fully recovered 1 hour after the second injection of methylene blue. Central cyanosis (Fig. 1A), ashen gray skin and "chocolate brown" colored blood (Fig. 1B) persisted. Transient blue-green discoloration of the urine was noted

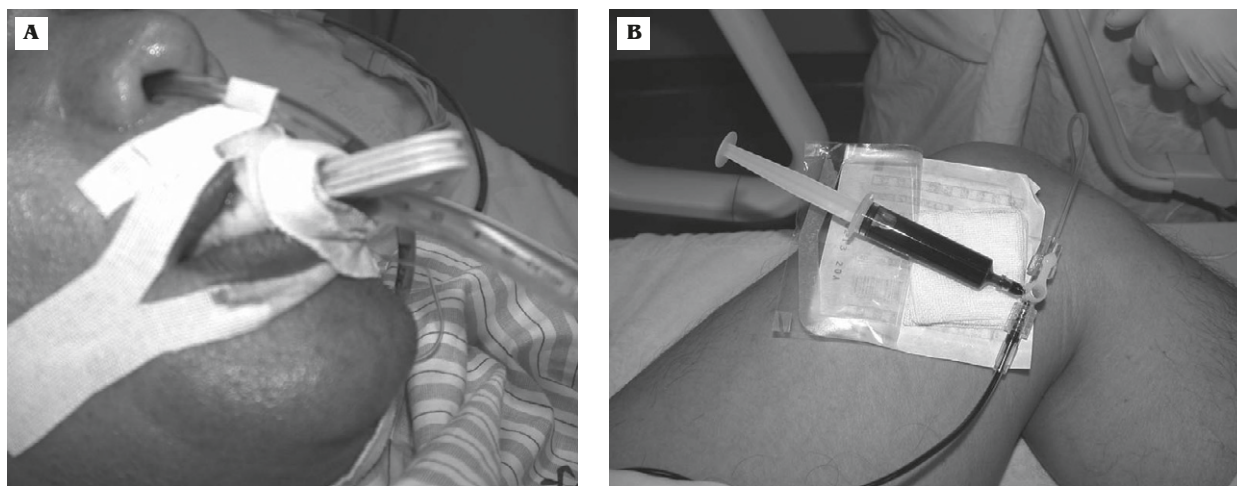


Fig. 1 — (A) The patient was intubated with cyanotic lips and ashen gray skin. (B) "Chocolate brown" colored blood was noted in the arterial line while methemoglobin was approximately 43.5%.

later on the same day. Follow-up blood MethHb levels were 5.2% on the following morning (10 hours after the second methylene blue dose). He was weaned from the ventilator on day 4 (Table 1). However, hemolytic anemia was noted on day 4 (hemoglobin was 6.7 g/dL, haptoglobin was <10 mg/dL, Heinz bodies). His serum total bilirubin level was 28.9 mg/dL and direct bilirubin was 21.1 mg/dL on day 6 (Table 1). Serum aspartate and alanine aminotransferase levels were 84 IU/L and 88 IU/L, respectively. Abdominal sonography showed no signs of biliary tract obstruction. The patient's HBs Ag and anti-HCV Ab results were negative. Blood transfusion with packed red blood cells was required daily until day 11, when a follow-up blood MethHb level was 0.1% (Table 1). The patient's hemoglobin level gradually stabilized and he was discharged in a stable condition on day 14.

3. Discussion

Methemoglobinemia involves the oxidation of ferrous iron to ferric iron, which takes place within the hemoglobin complex (6,7). Once MethHb is formed, the hemoglobin loses its ability to transport oxygen. Methemoglobinemia may occur after exposure to an oxidizing chemical, but it may also arise from genetic etiologies (8). Most proven cases of congenital methemoglobinemia have been in persons of European descent. Only three Chinese families have been unequivocally documented (9,10). The majority of patients with congenital methemoglobinemia are asymptomatic despite the intense cyanosis. This is a very important differentiating point from acquired methemoglobinemia (9). An intense "chocolate brown" colored blood, central cyanosis unresponsive to oxygen supplement, and discrepancy between arterial blood gases and pulse oximetry indicates abnormal hemoglobin levels (11). Definite diagnosis can be made using a multiple-wavelength CO-oximeter that measures oxy-, deoxy-, carboxy-, and MethHb directly using spectral absorption.

Metobromuron is a substitute urea herbicide that was widely used for the control of grasses and broad-leaf weeds during the 1990s. Major toxicity of metobromuron has rarely been reported even though it is commonly used (4,5). Methemoglobinemia could result from the metabolism of metobromuron to 4-bromoaniline and 4-bromoacetanilide (5). In our case, the late onset of cyanosis suggests that this mechanism may underlie the patient's methemoglobinemia. It is unlikely that metolachlor induced the methemoglobinemia as it does not induce methemoglobinemia in animals, and there are no case reports of methemoglobinemia in humans with metolachlor (4).

Methylene blue is known to be an antidote for methemoglobinemia (11,12). Methylene blue is reduced to

Table 1 — Summary of the clinical course and laboratory data

Time post intake	10 hr	12 hr	15 hr	22 hr	Day 2	Day 3	Day 4	Day 5	Day 6	Day 7	Day 8	Day 9	Day 10	Day 11	Day 12	Day 13	Day 14	
GCS score*	E1V1M1	E1V1M1	E4V1M6	-	-	-	E4V5M6	-	-	-	-	-	-	-	-	-	-	-
MethHb (%)	58.2	43.5	-	5.2	-	-	-	-	-	-	-	-	-	0.1	-	-	-	-
Methylene blue injection	2 mg/kg	2 mg/kg	-	-	-	-	-	-	-	-	-	-	-	-	-	-	-	-
SaO ₂ by CO oximeter (%)	75.2	83.7	-	91.1	-	-	-	-	-	-	-	-	-	96.6	-	-	-	-
Hb (g/dL)	-	13.4	-	-	12.3	10.0	6.7	4.0	3.9	6.5	7.6	8.2	8.8	9.4	-	-	-	-
Total bilirubin (mg/dL)	-	-	-	-	-	-	3.2	-	28.9	-	-	-	-	5.7	-	-	-	-
Direct bilirubin (mg/dL)	-	-	-	-	-	-	0.8	-	21.1	-	-	-	-	3.8	-	-	-	-
Packed RBC transfusion	-	-	-	-	-	-	2U	4U	4U	4U	2U	2U	2U	2U	-	-	-	-

*Data points are shown only when the patient's condition changed. GCS = Glasgow coma scale; MethHb = methemoglobin; Hb = hemoglobin; RBC = red blood cell.

leukomethylene blue by erythrocyte MetHb reductase, subsequently facilitating reduction of MetHb to oxy-hemoglobin (13). It is generally reserved for patients with symptomatic MetHb levels over 20%, or over 10% in those individuals with preexisting conditions that interfere with tissue oxygenation (e.g. anemia and coronary insufficiency) (14). However, hemolytic anemia and even methemoglobinemia have been reported after the administration of methylene blue (15,16). It has been recommended that methylene blue be intravenously administered in 1–2 mg/kg doses for 5–10 minutes, with the total dose not exceeding 15 mg/kg (11). Because the maximum effect of methylene blue is at 30 minutes, it may be necessary to repeat the dose of 1 mg/kg within 1 hour for MetHb levels over 60%, or when the patient's condition does not improve (14). Our patient received a second dose of intravenous methylene blue (2 mg/kg) because of the persistent high level of MetHb (43.5%) at 2 hours after the first dose. At doses exceeding 4 mg/kg, blue-green discoloration of the urine and feces due to leukomethylene blue and hemolytic anemia may occur, as noted in our patient (14). Hemolytic anemia may be delayed for several days and delay can even be up to 10 days after administration (14). Monitoring the blood counts is necessary. Methylene blue should be used carefully in young patients with glucose-6-phosphate dehydrogenase (G6PD) deficiency due to low endogenous concentrations of NADPH, which is necessary for leukomethylene blue production. These patients can develop hemolytic anemia without any reduction in methemoglobin levels (17). It has been suggested that low doses of methylene blue (< 1 mg/kg) may be beneficial in these individuals (17). Methylene blue doses greater than 4 mg/kg can exhibit oxidizing effects in these patients, resulting in hemolysis. Methemoglobinemia in patients with G6PD deficiency is best treated with blood transfusions (17). Despite our patient never having been tested for G6PD deficiency, we believe that he did not suffer from this condition due to the effective reduction of MetHb levels using methylene blue.

It is quite plausible that the hemolytic anemia in our patient was the result of the methylene blue. Hemolysis developed prior to the transfusion, excluding the transfusion reaction as the cause of the initial hemolysis. However, prolonged methemoglobinemia and ongoing oxidative stress may itself produce hemolysis, and it is possible that the hemolysis in our case was the result of exposure to metobromuron or, possibly, to both agents (4,8).

There have only been two similar cases reported in the English literature (4,5). The first case was a 22-year-old woman who was 36 weeks pregnant and developed central cyanosis 15 hours after ingestion of 500 mL of Galex herbicide (4). She received

1.5 mg/kg methylene blue intravenously with reversal of her central cyanosis 40 minutes after admission. The MetHb, which was not measured at admission, was still positive (5%) 50 hours post ingestion. The second case, a 36-year-old male alcoholic, appeared with diffuse cyanosis 17 hours after ingestion of beer (nearly 3 L) and 250 mL of a commercial herbicide "Patoran" containing 50% metobromuron and 7% propylene glycol in water (5). An 80% MetHb level was detected on admission. He received three doses of intravenous 2 mg/kg methylene blue for relapsing MetHb. Both patients fully recovered, but the second patient experienced transient hemolysis similar to our case report after the dosage had accumulated to 4 mg/kg.

In conclusion, ingestion of a large volume of herbicide containing metobromuron can induce methemoglobinemia. The onset of methemoglobinemia may be delayed for hours. Prolonged close observation in hospital is necessary. There is the potential for death following ingestion of herbicides containing metobromuron when adequate diagnosis and treatment are not instituted. Methylene blue is useful in reversing methemoglobinemia, but the side effects, such as hemolytic anemia, should be monitored, especially at doses exceeding 4 mg/kg or in patients with G6PD deficiency. Clinicians should attain relevant medical histories of G6PD deficiency before the use of methylene blue to decrease unnecessary hemolytic anemia. Methemoglobinemia in patients with G6PD deficiency is best treated with a blood transfusion.

References

1. Watt BE, Proudfoot AT, Bradberry SM, Vale JA. Poisoning due to urea herbicides. *Toxicol Rev* 2005;24:161–6.
2. Wikipedia. *Metolachlor*. Available at <http://en.wikipedia.org/wiki/Metolachlor> (Date accessed: October 22, 2008)
3. US Patent 6455471 — Pesticidal Compositions. Available at <http://www.patentstorm.us/patents/6455471/description.html> (Date accessed: October 22, 2008)
4. Yang CC, Hwang SF, Chou MM, Deng JF. Metobromuron/metolachlor ingestion with late onset methemoglobinemia in a pregnant woman successfully treated with methylene blue. *J Toxicol Clin Toxicol* 1995;33:713–6.
5. Turcant A, Cailleux A, Le Bouil A, Allain P, Harry P, Renault A. Acute metobromuron poisoning with severe associated methemoglobinemia. Identification of four metabolites in plasma and urine by LC-DAD, LC-ESI-MS, and LC-ESI-MS-MS. *J Anal Toxicol* 2000;24:157–64.
6. Price D. *Methemoglobinemia*, 7th edition. New York: McGraw-Hill, 2002.
7. Wright RO, Lewander WJ, Woolf AD. Methemoglobinemia: etiology, pharmacology, and clinical management. *Ann Emerg Med* 1999;34:646–56.
8. Haymond S, Cariappa R, Eby CS, Scott MG. Laboratory assessment of oxygenation in methemoglobinemia. *Clin Chem* 2005;51:434–44.

9. Kueh YK, Chio LF, Guan R. Congenital enzymopenic methaemoglobinaemia. *Ann Acad Med Singapore* 1986;15:250-4.
10. Wang Y, Huang C, Wu Y, Lan F, Tang Y, Zhu Z. Molecular mechanism of recessive congenital methemoglobinemia in Chinese pedigrees. *Chin Med J* 1999;112:1032-5.
11. Hall AH, Kulig KW, Rumack BH. Drug- and chemical-induced methaemoglobinaemia. Clinical features and management. *Med Toxicol* 1986;1:253-60.
12. Smith RP, Olson MV. Drug-induced methemoglobinemia. *Semin Hematol* 1973;10:253-68.
13. Disanto AR, Wagner JG. Pharmacokinetics of highly ionized drugs. II. Methylene blue: absorption, metabolism, and excretion in man and dog after oral administration. *J Pharm Sci* 1972;61:1086-90.
14. Clifton J 2nd, Leikin JB. Methylene blue. *Am J Ther* 2003;10:289-91.
15. Whitwam JG, Taylor AR, White JM. Potential hazard of methylene blue. *Anaesthesia* 1979;34:181-2.
16. Goluboff N, Wheaton R. Methylene blue induced cyanosis and acute hemolytic anemia complicating the treatment of methemoglobinemia. *J Pediatr* 1961;58:86-9.
17. Liao YP, Hung DZ, Yang DY. Hemolytic anemia after methylene blue therapy for aniline-induced methemoglobinemia. *Vet Hum Toxicol* 2002;44:19-21.