



## Case Report

## Surgical Excision of Tumoral Calcinosis of the Distal End of the Clavicle in a Patient With Uremia

Jui-Kuo Hung<sup>1\*</sup>, Ing-Lin Chang<sup>1</sup>, Hui-Mei Chang<sup>2</sup>

<sup>1</sup>Department of Orthopedic Surgery, Changhua Christian Hospital, Changhua, Taiwan

<sup>2</sup>Department of Pathology, Changhua Christian Hospital, Changhua, Taiwan

### Article info

#### Article history:

Received: September 16, 2008

Revised: October 3, 2008

Accepted: October 29, 2008

#### Keywords:

Distal end of the clavicle

Hemodialysis

Surgical excision

Tumoral calcinosis

### Abstract

Tumoral calcinosis is an uncommon disease characterized by tumor-like lesions composed of calcium salt. This condition is not a true neoplasm but an imbalance of calcium and phosphorus metabolism resulting from hereditary causes or secondary defects. Medical therapy to balance calcium and phosphorus is the cornerstone of treatment. However, when pain or other compression symptoms occur, surgical excision is indicated. We report a 53-year-old man who presented with a swollen mass over his left shoulder with severe pain and a decreased range of motion for about 6 months. He had a history of chronic renal failure and was on hemodialysis for 20 years. After serial examinations, hyperphosphatemia, hypocalcemia, and secondary hyperparathyroidism were diagnosed. Excision of the mass was performed. The pathological examination results revealed tumoral calcinosis. He was then referred to a nephrologist to adjust the medication, and dialysate was supplied to balance the calcium and phosphorus metabolism. He recovered well without significant complications or recurrence after 5 years of follow-up. (*Tzu Chi Med J* 2009;21(3):239–243)

\*Corresponding author. Department of Orthopedic Surgery, Changhua Christian Hospital, 135, Nanhsiao Street, Changhua, Taiwan.

E-mail address: [jkhung5728@yahoo.com.tw](mailto:jkhung5728@yahoo.com.tw)

## 1. Introduction

Tumoral calcinosis is an uncommon clinical and histopathologic syndrome characterized by calcium salt deposits in periarticular regions (1). Soft tissues of the shoulder, elbow, and hip regions are the most commonly involved areas. However, spinal and temporomandibular joint involvement has also been reported. The extensor aspect of the joint is the usual site of the lesion, where it often connects with a synovial bursa (2).

We present a 53-year-old male patient who was diagnosed with tumoral calcinosis around his left

shoulder and had surgical excision due to compression symptoms. He had a history of chronic renal failure with 20 years of hemodialysis therapy. After 5 years of follow-up, he recovered well and no recurrence or lesions were found.

## 2. Case report

A 53-year-old man presented with a swelling mass over his left shoulder, and 6 months of reported severe pain and decreased range of motion. He had a history of chronic renal failure and had received hemodialysis

for 20 years during his initial presentation. In addition, he had taken approximately 1000 mg of calcium supplement per day for more than 10 years. He began to note the swelling mass in his left shoulder about 6 months prior to this admission—the mass had enlarged progressively. Due to failure of conservative treatment, he was referred to our clinic for further evaluation from a nephrologist.

Physical examination revealed a mass, about 6 cm in length, with a stiff and elastic consistency, located in the left shoulder area. The patient reported a painful sensation while palpating the mass. It limited elevation and abduction of his left arm. The overlying skin was intact.

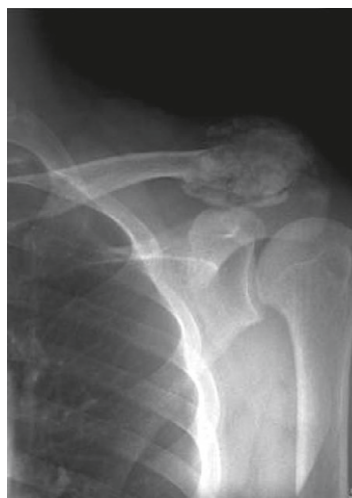Plain radiographs showed a large periarticular mass with heterogeneously calcified density and bony destruction around the left distal end of the clavicle (Fig. 1). Magnetic resonance imaging (MRI) showed the heterogeneous consistency of the lesion, consisting of multiple cavities alternating with calcified areas and compressing the surrounding structures (Fig. 2). Tumoral calcinosis was impressed and ultrasound examination of the neck was arranged, but no obvious abnormalities were noted.

The pertinent blood studies were within reference ranges except for blood urea nitrogen of 41 mg/dL (reference range, 9–23 mg/dL), creatinine of 8.4 mg/dL (reference range, 0.9–1.5 mg/dL), calcium of 7.4 mg/dL (reference range, 8.7–10.0 mg/dL), and phosphorus of 7.7 mg/dL (reference range, 2.2–4.3 mg/dL). Parathyroid hormone level was 228 pg/mL (reference range, 12.1–60.6 pg/mL). Secondary hyperparathyroidism was impressed on admission.

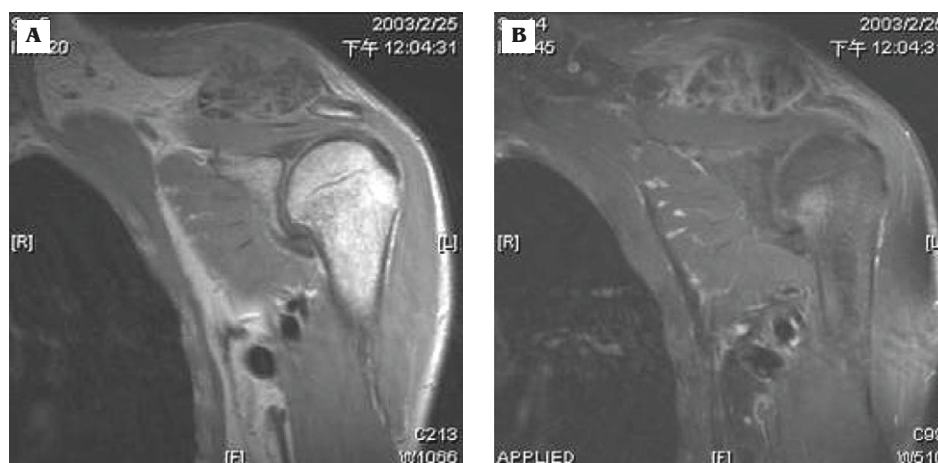An incision biopsy confirmed the diagnosis of tumoral calcinosis. The lesion was then excised (Fig. 3). The distal end of the clavicle was removed due to the advanced destruction. The soft mass was encircled

by a thin layer of woven fibrous tissue that seemed to arise from the acromioclavicular joint capsule (Fig. 4). Histologically, the excised tissue contained fibrous septum with giant cells and granulation tissues separating multiple lobules of calcium (Fig. 5).

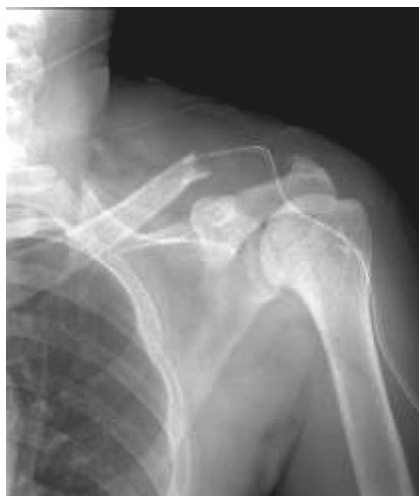After the operation, a nephrologist adjusted the medical and hemodialytic regimens for the patient. The dialysate was changed to a low calcium form and the intake of calcium supplements, high-calcium foods, and vitamin D were restricted. In addition, aluminum-hydroxide antacid was used to derivate the phosphate. After 3 months of management, the patient's blood calcium, phosphate, and parathyroid hormone levels returned to within reference ranges.



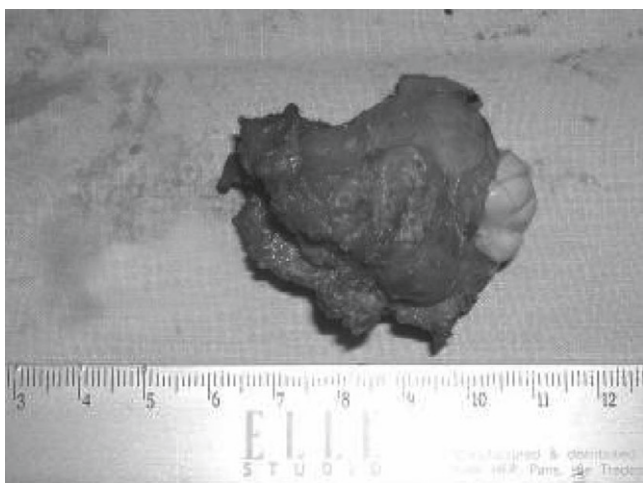
**Fig. 1** — Plain radiography of the left shoulder shows a large periarticular mass with heterogeneously calcified density and bony erosion around the left distal end of the clavicle.



**Fig. 2** — Magnetic resonance imaging shows a tumor with heterogeneous consistency and multiple cavities alternating with a calcified area: (A) coronal T1-weighted; (B) coronal T2-weighted.



**Fig. 3** — The mass and distal end of the clavicle were excised.

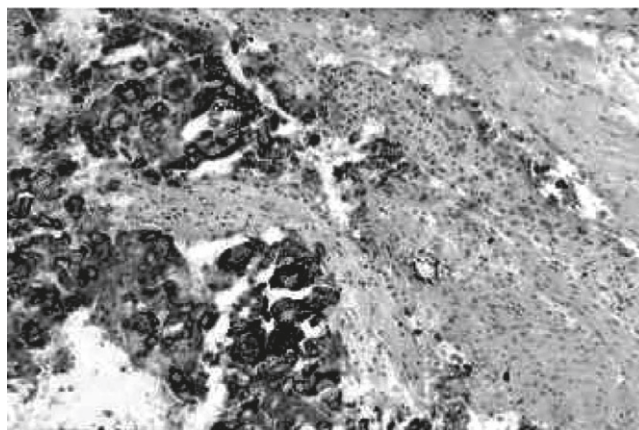


**Fig. 4** — Photograph showing the mass lesion, measuring about 5 cm in diameter, with a thin woven layer of fibrous pseudocapsule with multiple lobules of calcium deposits.

During the 5-year follow-up period, the patient's blood calcium, phosphate, and parathyroid hormone levels were within reference ranges. The patient reported marked clinical improvements. Physical examination revealed a normal range of motion, with no recurrence of the mass or any new lesion.

### 3. Discussion

Tumoral calcinosis is a tumor-like mass composed of calcium salt identified as calcium phosphates, calcium carbonates, pyrophosphates, hydroxyapatites, or a combination of these substances resulting from metabolic imbalances of calcium and phosphate.



**Fig. 5** — Photomicrograph showing amorphous calcified foci surrounded by fibrous cicatrix tissue (hematoxylin & eosin; original magnification, 200 $\times$ ).

The most common locations of tumoral calcinosis are the hip, elbow, shoulder, foot, and wrists (in descending order). They are often periarticular and large (1,3).

Tumoral calcinosis can be divided into primary or idiopathic and secondary categories (3). Primary or idiopathic tumoral calcinosis, the most common form, has a familial correlation in 30% of cases, and an autosomal recessive pattern of inheritance is suggested (4). However, recent discoveries in the field of genetics have suggested that autosomal recessive mutations also play important roles in the metabolic dysregulation of phosphate (5,6). Tumoral calcinosis often affects the black population in Africa during the first or second decade of life (7). The pathogenesis includes enhancement in renal tubular phosphate reabsorption, reduced urinary calcium excretion, and increased 1,25-dihydroxy-vitamin D formation (4). Prince et al (8) proposed an abnormality in the metabolism of calcitriol and hyperphosphatemia (for the failure of its feedback).

The secondary form is associated with a wide variety of metabolic abnormalities of calcium and phosphorus, such as primary or secondary hyperparathyroidism, scleroderma, prolonged therapies of calcitriol or calcium carbonate, and clinical features that often compose the complex outline of patients with chronic renal failure on long-term hemodialysis.

In the secondary form of tumoral calcinosis, the main pathogenetic mechanism reaches critical levels of serum calcium-phosphorus products of solubility ( $\text{Ca}^{2+} \times \text{P} > 70 \text{ mg/dL}$ ), creating the conditions for the precipitation of calcium salt in the soft tissues. In about half of patients with uremic tumoral calcinosis (9), the most frequent cause of this increase is secondary hyperparathyroidism. In patients without hyperparathyroidism, an increase in serum of  $\text{Ca}^{2+} \times \text{P}$

can be caused by iatrogenic hypercalcemia or severe hyperphosphatemia of multifactorial etiologies, such as prolonged or excessive administration of calcium carbonate and calcitriol, inadequate phosphorus chelating therapy, and insufficient dialysis. The duration of dialysis has been cited as a predisposing factor to the development of uremic tumoral calcinosis, and the risk of occurrence increases with the number of years of hemodialysis, despite normal values of  $\text{Ca}^{2+} \times \text{P}$  (10).

Tumoral calcinosis often consists of masses of multilobulated tissues of varying diameters, with fibrovascular septa that enclose areas of whitish calcifications with chalky firmness. They occur as multiple masses in two thirds of patients and are often firmly attached to muscles, underlying fascia, tendons, or the capsular joint. They may also infiltrate these structures (11). Growth of these lesions is usually slow and progressive, often taking place during many years. Sometimes, ulceration of the overlying skin occurs, causing secondary infections.

The masses are usually asymptomatic unless they enlarge enough to compress the surrounding tissues. The main symptoms are discomfort, swelling, pain, and joint limitation. Neurovascular compression is sometimes reported as compression of the ulnar nerve, median nerve in the carpal tunnel, and the sciatic nerve. The main joints involved are the shoulder, elbow, and hip. However, rare locations such as the spine, temporomandibular joint, hand and fingers, and knee extensor have also been described.

Radiographically, tumoral calcinosis is a calcified, lobulated, homogeneous mass, with rounded opacity separated by thin radiolucent lines that give it a so-called chicken wire appearance. MRI shows multiple cavities of low-signal density on T1- and T2-weighted sequences. Scintigraphy is useful, especially for the identification of multiple lesions and for assessing the results of the therapy.

Many periarticular masses may mimic the presenting pictures of tumoral calcinosis. The possible differential diagnoses are outlined in Table 1. History, physical examinations, radiographic pictures, and laboratory examination results must be accessed carefully before beginning the definite management (3).

Many reports have outlined various treatments of metabolic disorders and symptoms. Increased calcium-phosphorus serum products should be regulated. Regulation of hyperphosphatemia must be the first target. It is lowered by dietary deprivation of phosphorus, combined with phosphate-binding chelating agents, which have provided satisfactory results, clinical improvement, and often a reduction in the mass (12,13). The induction of a negative calcium balance may also be obtained by an increased number of dialysis sessions, with low  $\text{Ca}^{2+}$  dialysate concentration (14). Patients who underwent renal transplantation

**Table 1 – Differential diagnoses of tumoral calcinosis**

Calcific tendonitis
Synovial osteochondromatosis
Calcinosis universalis
Calcinosis circumscripta
Myositis ossificans
Tophaceous gout
Synovial sarcoma
Osteosarcoma
Chondrosarcoma
Others

showed marked improvement in the complete regression of tumoral calcinosis (10). Alternative medical treatments include the administration of steroids, diphosphonates, or calcitonin—but research has shown these to be unsuccessful (15).

Patients with secondary hyperparathyroidism have shown improvements in their clinical symptoms, and the progression of soft-tissue calcification has been halted after subtotal parathyroidectomy (16). However, the operation should be reserved for the most severe patients with multifocal tumoral calcinosis.

In summary, tumoral calcinosis is an imbalance of calcium and phosphorus metabolism. It is often found in patients with chronic renal failure and prolonged hemodialysis in Taiwan. Corrections of electrolyte imbalances and hormone abnormalities are the cornerstone of treatment. Once severe pain or other compression symptoms develop, surgical excision is indicated. After the operation, adjustment of medications, food, and dialysate to balance calcium and phosphorus metabolism is necessary to prevent the recurrence of old lesions as well as occurrence of new lesions.

## References

- Enziger FM, Weiss SW. Benign soft tissue tumors of uncertain type. In: *Soft Tissue Tumors*, 3<sup>rd</sup> edition. St Louis, Mo: CV Mosby, 1995:1039–45.
- Knowles SA, Declerck G, Anthony PP. Tumoral calcinosis. *Br J Surg* 1983;70:105–7.
- Olsen KM, Chew FS. Tumoral calcinosis: pearls, polemics, and alternative possibilities. *Radiographics* 2006;26: 871–85.
- Nedin S, Mustafa CA, Zekeriya T. Hyperphosphatemic tumoral calcinosis. *Plast Reconstr Surg* 2000;105:162–5.
- Larsson T, Davis SI, Garringer HJ, et al. Fibroblast growth factor-23 mutants causing familial tumoral calcinosis are differentially processed. *Endocrinology* 2005;146:3883–91.
- Benet-Pages A, Orlik P, Strom TM, Lorenz-Depiereux B. An FGF23 missense mutation causes familial tumoral calcinosis with hyperphosphatemia. *Hum Mol Genet* 2005;14:385–90.
- Steinbach LS, Johnston JO, Tepper EF, Honda GD, Martel W. Tumoral calcinosis: radiologic-pathologic correlation. *Skeletal Radiol* 1995;24:573–8.
- Prince MJ, Schaeffer PC, Goldsmith RS, Chausmer AB. Hyperphosphatemic tumoral calcinosis: association with

- elevation of serum 1,25-dihydroxycholecalciferol concentration. *Ann Intern Med* 1982;96:586-91.
9. Cofan F, Garcia S, Combalia A, Campistol JM, Oppenheimer F, Ramon R. Uremic tumoral calcinosis in patients receiving longterm hemodialysis therapy. *J Rheumatol* 1999;26:379-85.
  10. McGregor D, Burn J, Lynn K, Robson R. Rapid resolution of tumoral calcinosis after renal transplantation. *Clin Nephrol* 1999;51:54-8.
  11. McClatchie S, Bremner AD. Tumoral calcinosis: an unrecognized disease. *Br J Med* 1969;1:153-5.
  12. Davies M, Clements MR, Mawer EB. Tumoral calcinosis: clinical and metabolic response to phosphorus deprivation. *J Med* 1987;63:493-8.
  13. Mozaffarian G, Lafferty FW, Pearson OH. Treatment of tumoral calcinosis with phosphorus deprivation. *Ann Intern Med* 1972;77:741-5.
  14. Fernandez E, Montoliu J. Successful treatment of massive uremic tumoral calcinosis with daily hemodialysis and very low calcium dialysate. *Nephrol Dial Transplant* 1994;9:1207-9.
  15. Kallmeyer JC, Seimon LP, MacSearraigh ET. The effect of thyrocalcitonin therapy and phosphate deprivation on tumoral calcinosis. *S Afr Med J* 1978;54:963-9.
  16. Thakur A, Hines OJ, Thakur V, Gordon HE. Tumoral calcinosis regression after subtotal parathyroidectomy: a case presentation and review of literature. *Surgery* 1999;126:95-8.