

Pathology Page

Chromomycosis

Yung-Hsiang Hsu*

Department of Pathology, Buddhist Tzu Chi General Hospital and Tzu Chi University, Hualien, Taiwan

An 87-year-old man who was a retired farmer came to our hospital. One verrucous-like lesion measuring 3.0×2.0cm on his left lower leg was found. Malignancy was suggested. Incisional biopsy was performed. Microscopically, we found suppurative granuloma with brown-colored sclerotic cells (muriform cells) that were diagnostic of chromomycosis. Chromomycosis is a chronic skin infection caused by several species of fungi that live as saprophytes in the soil and decaying

vegetable matter. The fungi are brown, round, thick-walled, measure 8µm across, and have been described as "copper pennies". The histopathology is characterized by cutaneous suppurative granulomas containing "sclerotic cells" or "muriform cells" without hyphae formation. The infection is most commonly seen in barefoot agricultural workers in the tropics in whom the fungus is implanted during trauma, usually below the knee. The lesions begin as papules and, over the years, become verrucous, crusted, and sometimes ulcerated. The infection spreads by contiguous growth and through the lymphatic system. They may eventually involve the entire limb. In the primary stages, chromomycosis is best treated by surgical excision. In advanced cases, promising results have been obtained through the administration of amphotericin B. (*Tzu Chi Med J* 2009;21(1):89)

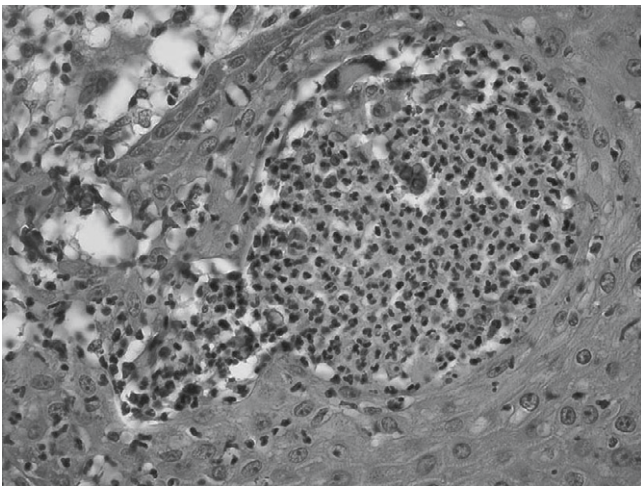


Fig. 1 — Histopathology shows pigmented spores resembling "copper pennies" surrounded by neutrophils (hematoxylin & eosin, 400×).

References

1. Santos AL, Palmeira VF, Rozental S, et al. Biology and pathogenesis of *Fonsecaea pedrosoi*, the major etiologic agent of chromoblastomycosis. *FEMS Microbiol Rev* 2007;31: 570–91.
2. Rasul ES, Hazarika NK, Sharma A, Borua PC, Sen SS. Chromoblastomycosis. *J Assoc Physicians India* 2007;55: 149–51.
3. Pradhan SV, Talwar OP, Ghosh A, Swami RM, Shiva Raj KC, Gupta S. Chromoblastomycosis in Nepal: a study of 13 cases. *Indian J Dermatol Venereol Leprol* 2007;73:176–8.

*Corresponding author. Department of Pathology, Buddhist Tzu Chi General Hospital, 707, Section 3, Chung-Yang Road, Hualien, Taiwan.
E-mail address: yhhsu@mail.tcu.edu.tw