



Case Report

Cercarial Dermatitis

Chao-Hwei Wang, Chung-Hsing Chang*

Department of Dermatology, Buddhist Tzu Chi General Hospital and Tzu Chi University, Hualien, Taiwan

Article info

Article history:

Received: May 23, 2007

Revised: August 8, 2007

Accepted: September 3, 2007

Keywords:

Cercarial dermatitis

Schistosome

Prurigo

Abstract

Cercarial dermatitis (swimmer's itch) is an acute cutaneous inflammatory response caused by the penetration of cercaria of nonhuman schistosomes. It frequently presents with itchy erythematous papules, which cover the water-exposed areas within 24 hours. This paper reports a case of cercarial dermatitis in a 60-year-old man who presented with itchy erythematous papules on bilateral lower legs after walking upstream in the Mu-Gua River in Hualien. His symptoms and signs could not be relieved by treatment with topical steroids and a skin biopsy was performed. Skin pathology revealed massive eosinophil infiltration of the dermis and fragments of larvae perpendicular to the skin surface. Based on the history, clinical course and the shape, length and penetration of the larvae, which was revealed by the skin pathology, cercarial dermatitis was diagnosed. His symptoms were relieved spontaneously 3 weeks after infection. (*Tzu Chi Med J* 2008;20(1):63–66)

*Corresponding author. Department of Dermatology, Buddhist Tzu Chi General Hospital, 707, Section 3, Chung-Yang Road, Hualien, Taiwan.

E-mail address: chchang@tzuchi.com.tw

1. Introduction

Cercarial dermatitis is characterized by a sudden onset of severe itchy monomorphic maculopapular skin eruptions affecting areas exposed to water, where the cercaria of non-human *Schistosoma* exist and have penetrated into the human skin. The cercaria's normal hosts are birds, rodents and various other small mammals. Man is an accidental host. *Schistosoma*, (*Austroilharzia*, *Dendritobilharzia*, *Schistosomatium*), *Gigantobilharzia*, *Austroilharzia*, *Trichobilharzia* and *Orientobilharzia* are some of the over 20 species that have been implicated in this disease. It is also referred to as swimmer's itch, rice farmer's itch or clam digger's itch because this dermatosis is encountered most frequently in leisure activities or

occupations that expose the patient to water. Cases have been reported in North America (in lake regions especially), Canada, Europe, Africa and the Far East and the peak season is summer (1,2). Several outbreaks of cercarial dermatitis have also been reported in Quebec, Canada, Germany, France, Thailand and along the Huaihe River of China (3–6). Here, we report the first case in Taiwan.

2. Case report

A 60-year-old man suffered from severe itchy maculopapular skin eruptions bilaterally over his lower legs (Fig. 1) after walking upstream in the Mu-Gua River in Hualien, Taiwan. Before visiting the outpatient

clinic of Buddhist Tzu Chi General Hospital, his skin lesions were diagnosed as prurigo or insect bites and treated with a topical steroid ointment and oral antihistamines. However, the skin lesions and symptoms persisted. Therefore, a skin biopsy was performed on the lesion. The histological examination revealed intensive eosinophil and lymphocyte infiltration of the dermis and some larval sections were identified within the biopsy (Fig. 2). All the symptoms resolved spontaneously 3 weeks after infection. On the basis

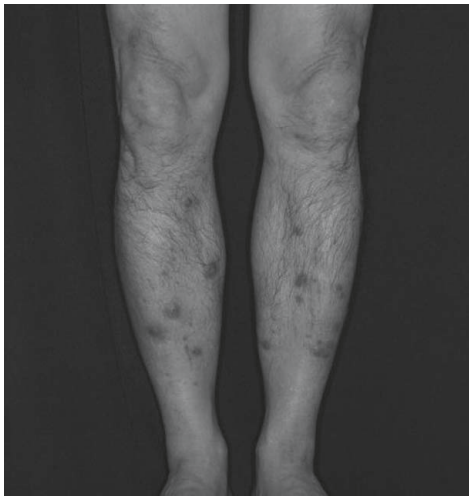

Fig. 1 — Multiple erythematous papules and nodules over the lower legs, which had been immersed in the Mu-Gua River.

of leisure activity, cutaneous manifestations, pathological findings and the clinical course, cercarial dermatitis was diagnosed.

3. Discussion

The cercariae are larvae of trematodes of related genera *Schistosoma* and *Trichobilharzia*. The typical lifecycle of these trematodes begins when the primary hosts (water birds, deer, mice, etc.) excrete parasite eggs in their feces into the water, where the fully developed larvae (miracidia) hatch from the eggs within 10–15 minutes. Miracidia need to penetrate into their intermediate hosts (water snails) within 12 hours or they will die. The miracidia gather in the digestive gland of the snail where they develop into multiple sporocysts. In about 5 weeks, the sporocysts give rise to hundreds of fork-tailed cercaria that measure 700–800 μm in length (7–9). Light and heat can stimulate water snails to release the cercaria into water. When an appropriate host is encountered, the cercaria attach onto the host's skin by oral suckers and release a proteolytic enzyme that facilitates their penetration through the stratum corneum (Fig. 3). The tail part is left outside the skin by means of histolytic enzymes. In addition to thermotactile stimulation, ceramide and cholesterol serve as non-selective chemoattractants to facilitate the sticking of the cercaria onto the host's skin (10).

Although cercaria of non-human schistosomiasis can accidentally penetrate the epidermis, they are

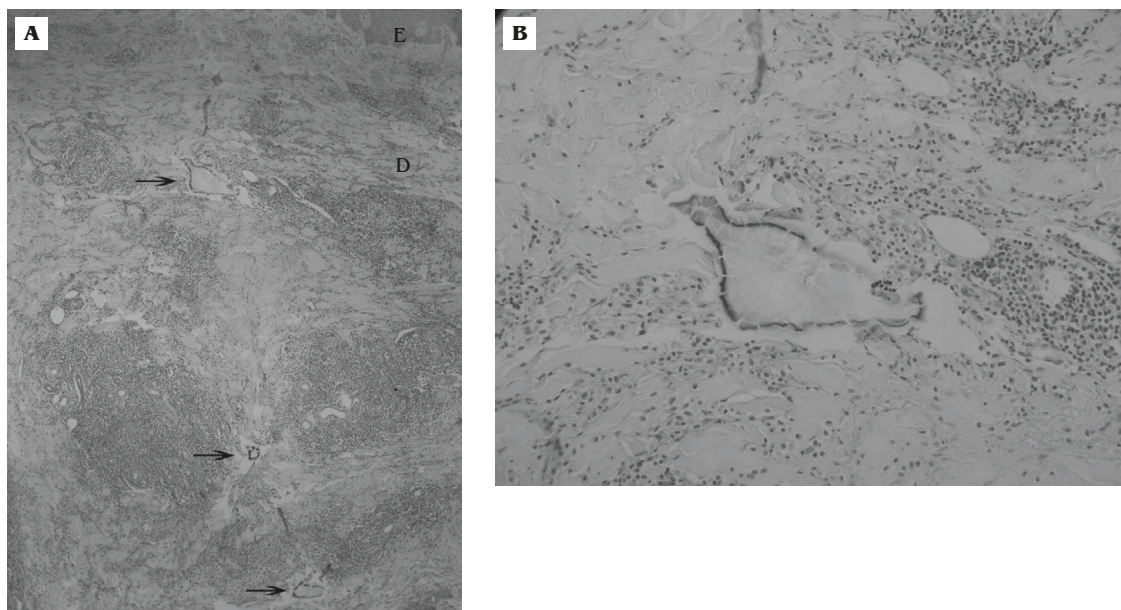


Fig. 2 — (A) Skin lesion pathology reveals dense eosinophil infiltration in the dermis and fragments of larva perpendicular to the skin surface (hematoxylin & eosin, 200 \times). E = epidermis; D = dermis. Arrows indicate the larva section. (B) Cercarial larvae are visible within the dermis (hematoxylin & eosin, 400 \times).

unable to reach the bloodstream to induce systemic infection (10). The parasites residing in dermis induce a type I hypersensitivity reaction and will finally die due to histolysis. The residual cercarial protein may stimulate a type IV hypersensitivity reaction and trigger diffuse skin eruptions as a result of repeated exposure (11). In the diagnosis of cercarial dermatitis, a history of exposure to the contaminated fresh water within 24 hours is the most useful clue and the skin lesions are characterized by pruritic, eruptive and monotonous papules or nodules on the cloth-uncovered area and by the complete termination of the pruritic lesions within 3 weeks with or without treatment. Laboratory examination, including antibody detection by enzyme-linked immunosorbent assay or antigen detection in serum, urine or breast milk, is not very supportive in the diagnosis of the accidental non-human schistosomiasis as with human visceral schistosomiasis (12). In previously published papers, the larvae have rarely shown up in skin biopsy pathological findings. When we first observed the slide, we could only identify eosinophil infiltration and some foreign bodies in the dermis, which were arranged perpendicular to the skin surface. After tracing the history of this patient's illness and having carried out a literature search on skin diseases caused by non-infectious coastal microorganisms, it seemed likely that cercariae were the most probable cause judging by the shape and the length of the "foreign bodies" and the way that they had entered the skin.

To treat cercarial dermatitis, topical steroid cream or oral antihistamines may be helpful and help to relieve the itch and erythema to some degree.

However, due to the histolysis of the parasite in the dermis, which usually occurs within 24–48 hours, most patients will recover completely after 3 weeks. Systemic treatment with ivermectin early in the disease has been proposed as a treatment consideration until the possible latent ramifications of this trematode infestation are elucidated (13). Prurigo nodularis or insect bites are the common differential diagnoses, but they are not triggered by water exposure and no foreign bodies would be identified in the skin biopsy.

In Taiwan, *Schistosoma japonicum* is the main cause of animal (cow, sheep, etc.) schistosomiasis in Yilan County and Changhua County. In terms of bird schistosomiasis, 12 species have been identified, including *Trichobilharzia* (9 species), *Gigantobilharzia* (2 species) and *Bilharzia polonica*. In Asia, *T. ocellata*, *T. paoi*, *T. gigantia* and *T. jianensis* are the more common species found in birds. Taiwan has many migratory birds and therefore the schistosomiasis species present in birds across Taiwan need further surveying. Water snails are the intermediate host. There have been sporadic reports of *T. ocellata* in the water snails of the Jinlun River in southeastern Taiwan (14). In Hualien County, there is, at present, no survey data for the Mu-Gua River.

To the best of our knowledge, this is the first report of cercarial dermatitis with pathology in Taiwan. We should remain aware of this relatively rare dermatosis in our modern society. The wearing of correct footwear will prevent direct contact with contaminated water during occupational and leisure activities and is thus advised.

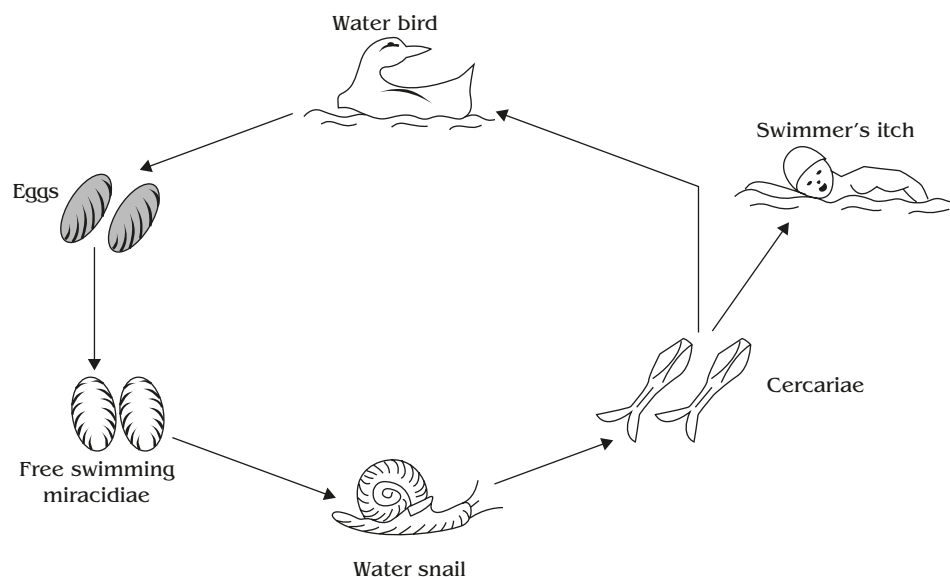


Fig. 3 — Lifecycle of non-human species of *Schistosoma*, modified from references 7 and 8.

Acknowledgments

We are indebted to June-Der Lee, master lecturer, Department of Parasitology, Kaohsiung Medical University, for helpful discussions and confirmation of the presence of the larvae in the section of dermis.

References

1. Hoeffler DF. "Swimmer's itch" (cercarial dermatitis). *Cutis* 1977;19:461-5, 467.
2. Mulvihill CA, Burnett JW. Swimmer's itch: a cercarial dermatitis. *Cutis* 1990;46:211-3.
3. Levesque B, Giovenazzo P, Guerrier P, Laverdiere D, Prud'Homme H. Investigation of an outbreak of cercarial dermatitis. *Epidemiol Infect* 2002;129:379-86.
4. Kullavanijaya P, Wongwaisayawan H. Outbreak of cercarial dermatitis in Thailand. *Int J Dermatol* 1993;32:113-5.
5. Verbrugge LM, Rainey JJ, Reimink RL, Blankespoor HO. Swimmer's itch: incidence and risk factors. *Am J Public Health* 2004;94:738-41.
6. Li C, Ma C, Gu J, Lu W. An epidemiological survey of schistosome cercarial dermatitis among the residents living along the banks of the Huaihe River system. *Zhongguo Ji Sheng Chong Xue Yu Ji Sheng Chong Bing Za Zhi* 1998;16:384-7.
7. Bastert J, Sing A, Wollenberg A, Korting HC. Aquarium dermatitis: cercarial dermatitis in an aquarist. *Dermatology* 1998;197:84-6.
8. Folster-Holst R, Disko R, Rowert J, Bockeler W, Kreiselmaier I, Christophers E. Cercarial dermatitis contracted via contact with an aquarium: case report and review. *Br J Dermatol* 2001;145:638-40.
9. Farahnak A, Essalat M. A study on cercarial dermatitis in Khuzestan province, south western Iran. *BMC Public Health* 2003;3:35.
10. Haas W, van de Roemer A. Invasion of the vertebrate skin by cercariae of *Trichobilharzia ocellata*: penetration processes and stimulating host signals. *Parasitol Res* 1998;84:787-95.
11. Kourilova P, Hogg KG, Kolarova L, Mountford AP. Cercarial dermatitis caused by bird schistosomes comprises both immediate and late phase cutaneous hypersensitivity reaction. *J Immunol* 2004;172:3766-74.
12. Scrimgeour EM, Daar AS. Schistosomiasis: clinical relevance to surgeons in Australasia and diagnostic update. *Aust N Z J Surg* 2000;70:157-61.
13. Burkhart CG, Burkhart CN. Swimmer's itch: an assessment proposing possible treatment with ivermectin. *Int J Dermatol* 2003;42:917-8.
14. Chen KJ, Soong K. *A Preliminary Study on the Reproductive Ecology of the Freshwater Snail Tarebia granifera (Lamarck, 1822) (Prosobranchia: Thiaridae) in Jinlun River, South Eastern Taiwan*. Master's thesis, National Sun Yat-Sen University, Kaohsiung, Taiwan.