



## Original Article

# Surgical outcomes of patients with primary aldosteronism lateralized with I-131-6 $\beta$ -iodomethyl-norcholesterol single photon emission/computed tomography without discontinuation or modification of antihypertensive medications

Chia-Hui Chang<sup>a</sup>, Stephen Shei-Dei Yang<sup>b</sup>, Yao-Chou Tsai<sup>b</sup>, Shi-Wen Kuo<sup>a</sup>, Shiou-Chi Cherng<sup>c</sup>, Ching-Chu Lu<sup>d</sup>, Ruoh-Fang Yen<sup>d</sup>, Vin-Cent Wu<sup>e</sup>, Ya-Hui Hu<sup>a\*</sup>

<sup>a</sup>Division of Endocrinology and Metabolism, Department of Internal Medicine, Taipei Tzu Chi Hospital, Buddhist Tzu Chi Medical Foundation, New Taipei, Taiwan, <sup>b</sup>Division of Urology, Department of Surgery, Taipei Tzu Chi Hospital, Buddhist Tzu Chi Medical Foundation, New Taipei, Taiwan, <sup>c</sup>Department of Nuclear Medicine, Taipei Tzu Chi Hospital, Buddhist Tzu Chi Medical Foundation, New Taipei, Taiwan, <sup>d</sup>Department of Nuclear Medicine, National Taiwan University Hospital and National Taiwan University College of Medicine, Taipei, Taiwan, <sup>e</sup>Department of Internal Medicine, National Taiwan University Hospital and National Taiwan University College of Medicine, Taipei, Taiwan

## ABSTRACT

**Objectives:** Adrenocortical scintigraphy for patients with primary aldosteronism (PA) without discontinuation or modification of antihypertensive medications is of concern because of drug interference with the renin–angiotensin–aldosterone system. We report the surgical outcomes of patients with PA lateralized with adrenocortical scintigraphy without drug discontinuation or modification. **Materials and Methods:** We retrospectively reviewed 34 patients with PA with computed tomography (CT)-documented adrenal tumors who had undergoing subsequent I-131-6  $\beta$ -iodomethyl-norcholesterol (NP-59) single photon emission CT (SPECT)/CT followed by unilateral adrenalectomy according to the results of NP-59 uptake between May 2005 and December 2014. All enrolled patients underwent standard confirmatory tests and lateralization with NP-59 SPECT/CT without discontinuation of existing antihypertensive medications, including spironolactone. The pathological findings, hypertension outcomes, and biochemical changes were reported. The accuracy of NP-59 SPECT/CT without drug discontinuation or modification was also evaluated. **Results:** None of the 34 enrolled patients (M:F = 16:18) had complications such as a hypertensive crisis, life-threatening hypokalemic event, or cardiac arrhythmia. Pathology disclosed 31 (91%) adenomas and three cases of hyperplasia. Hypertension cure and improvement were observed in 12 (35%) and 18 (53%) patients, respectively. All of the 30 patients (100%) without postoperative use of beta-blockers and with an available postoperative aldosterone/renin ratio achieved a biochemical cure. The positive predictive values of NP-59 SPECT/CT were 91%, 88%, and 100% for the pathological findings, hypertension outcomes, and biochemical changes, respectively. **Conclusion:** Noninvasive NP-59 SPECT/CT without discontinuation or modification of antihypertensive medications not only provided accurate lateralization and safety but also resulted in a high improvement rate for PA-associated hypertension.

**KEYWORDS:** Adrenocortical scintigraphy, Drug discontinuation, I-131-6  $\beta$ -iodomethyl-norcholesterol single photon emission computed tomography/computed tomography, Primary aldosteronism, Spironolactone

Received : 16-Aug-2017  
Revised : 13-Nov-2017  
Accepted : 01-Feb-2018

## INTRODUCTION

The prevalence of primary aldosteronism (PA) in the general hypertensive population is about 10%. The two most common etiologies of endocrine hypertension are aldosterone-producing adenoma (APA) and idiopathic hyperaldosteronism (IHA) [1,2]. Surgery is the standard treatment for unilateral adrenal diseases such as APA or unilateral adrenal hyperplasia [3-5], while mineralocorticoid receptor

antagonists (MRAs) are used for IHA [6]. Because prolonged exposure to excess aldosterone results in cardiovascular

## \*Address for correspondence:

Dr. Ya-Hui Hu,  
Division of Endocrinology and Metabolism, Department of Internal  
Medicine, Taipei Tzu Chi Hospital, Buddhist Tzu Chi Medical  
Foundation, 289, Jianguo Road, Xindian District, New Taipei, Taiwan.  
E-mail: huyahuihuyahui@hotmail.com

This is an open access journal, and articles are distributed under the terms of the Creative Commons Attribution-NonCommercial-ShareAlike 4.0 License, which allows others to remix, tweak, and build upon the work non-commercially, as long as appropriate credit is given and the new creations are licensed under the identical terms.

For reprints contact: [reprints@medknow.com](mailto:reprints@medknow.com)

**How to cite this article:** Chang CH, Yang SS, Tsai YC, Kuo SW, Cherng SC, Lu CC, et al. Surgical outcomes of patients with primary aldosteronism lateralized with I-131-6  $\beta$ -iodomethyl-norcholesterol single photon emission/computed tomography without discontinuation or modification of antihypertensive medications. Tzu Chi Med J 2018;30:169-75.

## Access this article online

## Quick Response Code:



Website: [www.tcmjmed.com](http://www.tcmjmed.com)

DOI: 10.4103/tcmj.tcmj\_106\_17

damage [7,8], early diagnosis of PA could change hypertension-related outcomes [9,10].

The accurate diagnosis of PA is based on screening tests, confirmatory tests, and subsequent lateralized studies [1]. In the initial screening tests for PA, continuing antihypertensive medications, except for spironolactone or other potassium-wasting diuretics, has been recommended in the American Endocrine Society Guidelines since 2008 [11]. However, in confirmatory tests and lateralization with adrenal venous sampling (AVS) or adrenocortical scintigraphy, antihypertensive medications should be discontinued or modified [1,12-14]. Discontinuing or modifying medications is potentially dangerous for a patient with severe refractory hypertension, hypokalemic paralysis, or cardiogenic arrhythmia. Only a few studies have assessed the influence of different classes of antihypertensive medications on AVS results or adrenocortical scintigraphy. In 2014, Haase *et al.* concluded that, in selected cases of PA, MRA therapy might be continued during AVS [15]. Nakahama *et al.* reported in 2003 that the discontinuation of antihypertensive medications was not necessary in 119 patients undergoing lateralization with adrenocortical scintigraphy [16]. Overall, studies supporting lateralization without drug discontinuation or modification in PA are insufficient.

AVS is the gold standard for localizing sources of excess aldosterone and distinguishing APA from IHA. AVS is an invasive technique that can be optimally performed only at experienced centers and is associated with a complication rate of 2.5%. Complications include failure of canalization of the right adrenal vein, hematoma, infarction, adrenal vein thrombosis, and perforation [13]. To avoid the aforementioned complications, I-131-6  $\beta$ -iodomethyl-norcholesterol (NP-59) single photon emission computed tomography (SPECT)/CT has been reported as a noninvasive alternative for the functional localization of PA [13,14,17-19].

Herein, we performed a retrospective study to report the outcomes of adrenalectomy in PA patients diagnosed without discontinuing or modifying antihypertensive medications in lateralization with adrenocortical scintigraphy.

## MATERIALS AND METHODS

### Ethics statement

This retrospective study was conducted in accordance with the Declaration of Helsinki and was approved by the local ethics committee of Taipei Tzu Chi Hospital (No. 04-X01-003). Informed written consent was waived because the study was a retrospective data analysis.

### Patient selection

We retrospectively reviewed consecutive patients diagnosed with PA with adrenalectomy between May 2005 and December 2014. PA was diagnosed based on a plasma aldosterone concentration (PAC) >15 ng/dL, suppressed plasma renin activity (PRA), and an aldosterone/renin ratio (ARR) >30 ng/dL per ng/mL/h with the use of antihypertensive medications, except for spironolactone or other potassium-wasting diuretics [1]. All enrolled patients were confirmed to have PA by a saline infusion test, angiotensin-converting enzyme

inhibitor, or angiotensin receptor blocker suppression test, and then by NP-59 SPECT/CT adrenocortical scintigraphy without the discontinuation of antihypertensive medications, including spironolactone. Patients with an incomplete history of antihypertensive medications, normotensive PA, PA combined with Cushing's syndrome, or a follow-up of <3 months were excluded from this study.

### Group classification and definitions

Based on the resolution of hypertension postoperatively, the patients were divided into three groups: (1) the cure group (all antihypertensive medications discontinued and blood pressure below 140/90 mmHg), (2) the improvement group (normotension with a decreased dosage, normotension with the need for an equal number of or fewer antihypertensive medications, or hypertension with fewer antihypertensive medications required for control), and (3) the refractory group (no change or increasing dosage of preoperative antihypertensive medications) [20]. Biochemical cure was defined as ARR <30 ng/dL/ng/mL/h in cases without the use of beta-blockers. We collected information on the following clinical parameters and laboratory data from medical records: age, gender, body mass index (BMI), comorbidities, tumor size on CT, systolic blood pressure (SBP), diastolic blood pressure (DBP), serum potassium levels, PAC, PRA, number of antihypertensive medications, and pathological findings. Blood pressure was measured using a sphygmomanometer during the initial evaluation of secondary hypertension in the outpatient department. Hypokalemia was defined as serum potassium <3.5 mmol/L. The preoperative plasma potassium level, PAC, PRA, and ARR were all obtained at the first positive screening tests. PA and the hypertension outcome after adrenalectomy were assessed after a follow-up of at least 3 months.

### Lateralizing techniques

After confirmatory tests, adrenal CT was performed in all patients. They underwent subsequent noninvasive NP-59 SPECT/CT adrenocortical scintigraphy after 8 mg of dexamethasone suppression daily for 1 week, 1 mL of diluted Lugol solution daily to protect the thyroid and bowel preparation to reduce intestinal background activity. The standard protocol for adrenocortical scintigraphy was similar to that described in a previous report [14]. However, patients taking any antihypertensive medication, including spironolactone, did not discontinue their medications for days to 4–6 weeks. Scanning was performed at 3–5 days after NP-59 injection [13,14,16]. If results between CT and NP-59 SPECT/CT were inconclusive, AVS with drug discontinuation was necessary for further differentiation. Those with negative NP-59 results preoperatively were treated medically and were not enrolled in the current study [14].

The standard protocol for AVS used in our affiliated hospitals was followed [14,21]. AVS was performed without adrenocorticotrophic hormone stimulation by experienced radiologists. Successful catheterization of each adrenal vein was confirmed based on a target to peripheral venous cortisol ratio >2. The adrenal vein aldosterone to cortisol ratio (A/C ratio) was used to verify unilateral aldosterone hypersecretion. If the A/C ratio between the lesioned and contralateral

sides was >2 with the phenomenon of contralateral suppression compared with the peripheral vein, unilateral localization was confirmed.

### Statistical analyses

All data are expressed as mean  $\pm$  standard deviation or median with interquartile ranges depending on their normal or nonnormal distribution. The NP-59-positive predictive value (PPV) was defined as true positive/(true positive + false positive)  $\times$  100%. To explore prognostic factors for cure of hypertension in APA patients, the study enrollees were classified into cure and noncure groups. The differences in the preoperative variables between the two groups were calculated using the Mann-Whitney U-test. The paired *t*-test was used to determine differences in variables before and after surgery as a whole. Binary logistic regression with a stepwise method was used to determine prognostic factors for a complete hypertension cure. Furthermore, following significant results in logistic regression, we adopted a generalized additive model (GAM) smoothing plot to show the relationship between the log odds ratio to predict cure of hypertension and possible prognostic factors with multivariate adjustments.

Statistical significance was defined as  $P < 0.05$ . All calculations were done using MedCalc Statistical Software version 16.8.4 (MedCalc Software bvba, Ostend, Belgium; <https://www.medcalc.org>; 2016) and R software, version 2.8.1 (Free Software Foundation, Inc., Boston, MA, USA).

### RESULTS

After three patients diagnosed with PA with Cushing's syndrome and one normotensive PA patient were excluded, a total of 72 patients (32 men and 40 women) clinically diagnosed with PA and undergoing adrenalectomy were assessed during the study period. These included 66 cases of APA and six cases of hyperplasia confirmed by pathology. Of these, seven patients had AVS and 32 had NP-59 SPECT/CT with standard drug discontinuation or modification. A total of 34 patients who underwent NP-59 SPECT/CT without drug discontinuation or modification were enrolled in this study.

Lesion characteristics and clinical results of the 34 enrolled patients (16 men and 18 women) are summarized in Supplemental Table 1. The mean age and BMI of the patients were  $51.9 \pm 12.2$  years and  $26.8 \pm 4.2$  kg/m<sup>2</sup>, respectively. One of the 34 patients (3%) had heart failure, two (6%)

had intracranial hemorrhage, six (18%) had chronic kidney disease (CKD), nine (26%) had diabetes mellitus (DM), and 30 (88%) had hypokalemia. No patients experienced complications, such as a hypertensive crisis, life-threatening hypokalemic event, or cardiogenic arrhythmia, in the screening tests or lateralization with adrenocortical scintigraphy. There were no surgery-related complications or postoperative adrenal insufficiency. The mean tumor size on CT was  $1.82 \pm 0.59$  cm, with a left to right ratio of 2.4 (24:10). The mean postoperative follow-up period was  $27.9 \pm 25.5$  months. Postoperatively, the mean SBP decreased from  $169 \pm 22$  to  $130 \pm 11$  mmHg ( $P < 0.001$ ) and DBP decreased from  $101 \pm 16$  to  $85 \pm 14$  mmHg ( $P < 0.001$ ). The mean PAC decreased from  $42.5 \pm 23.3$  to  $18.7 \pm 8.2$  ng/dL ( $P < 0.001$ ), and the mean ARR decreased from  $243.1 \pm 200.1$  to  $16.1 \pm 18.2$  ng/dL per ng/mL/h ( $P < 0.001$ ). The mean serum potassium level increased from  $2.6 \pm 0.7$  to  $4.2 \pm 0.4$  mmol/L ( $P < 0.001$ ). The patients took an average of  $3.2 \pm 1.1$  types of antihypertensive medications preoperatively and  $1.6 \pm 1.4$  postoperatively ( $P < 0.001$ ).

In our study, one patient (No. 6) had a unilateral left CT lesion and bilateral NP-59 uptake but with predominant uptake on the left side. The total counts were 50.16 on the right side and 70.75 on the left side [Figure 1]. Due to a history of acute myocardial infarction and CKD Stage 3, he was not a suitable candidate for standard AVS. After discussion and providing informed consent, the patient underwent left adrenalectomy under poorly controlled hypertension. Pathology revealed adrenocortical adenoma. Postoperatively, the patient showed improvement in hypertension and a biochemical cure. Patient 17 had a 1.4-cm tumor on the left side on CT; however, uptake was observed on the right side in NP-59 SPECT/CT [Figure 2]. After right adrenalectomy, pathology revealed microadenoma of 0.1 cm<sup>3</sup> (0.5 cm  $\times$  0.5 cm  $\times$  0.4 cm). She showed improvement in hypertension and experienced a biochemical cure after a follow-up of 28 months.

Of the 34 patients, there were 31 (91%) cases of unilateral APA and 3 (9%) patients with IHA. Postoperatively, 12 (35%) patients exhibited hypertension cure and 18 (53%) showed improvement. Biochemical improvement was observed postoperatively in four patients (No. 22, 24, 29, and 31) who had persistent postoperative use of beta-blockers and were excluded from the following analysis. All 30 patients without postoperative use of beta-blockers and with available postoperative ARR data experienced a biochemical cure. Thus, the PPV of

**Table 1: Logistic regression for prognostic factors for hypertension cure in 31 patients with aldosterone-producing adenoma**

Preoperative variables	Cure (n=12)	Noncure (n=19)	Man-Whitney U-test (P)	Logistic regression		
				OR	95% CI	P
Age (years)	44.5 (39.0-55.5)	57.0 (52.3-65.3)	0.014*			
Sex (female/male)	7/5	10/9	0.767			
BMI (kg/m <sup>2</sup> )	26.1 (24.7-28.5)	25.3 (22.8-28.6)	0.839			
MBP (mmHg)	121 (107-133)	118 (107-139)	0.792			
Number of antihypertensive drugs	3.0 (2.5-4.0)	4.0 (2.0-4.0)	0.967			
Duration of hypertension (years)	5.5 (2.5-10.5)	8.0 (3.3-11.5)	0.566			
PAC (ng/dL)	625.3 (292.7-796.8)	323.9 (236.5-438.1)	0.026*	0.994	0.989-0.999	0.016*
Serum potassium level (mmol/L)	2.2 (1.9-2.7)	2.8 (2.3-3.2)	0.168			

\* $P < 0.05$ . Data are reported as median (interquartile ranges). APA: Aldosterone-producing adenoma, BMI: Body mass index, CI: Confidence interval, MBP: Mean blood pressure, PAC: Plasma aldosterone concentration, OR: Odds ratio

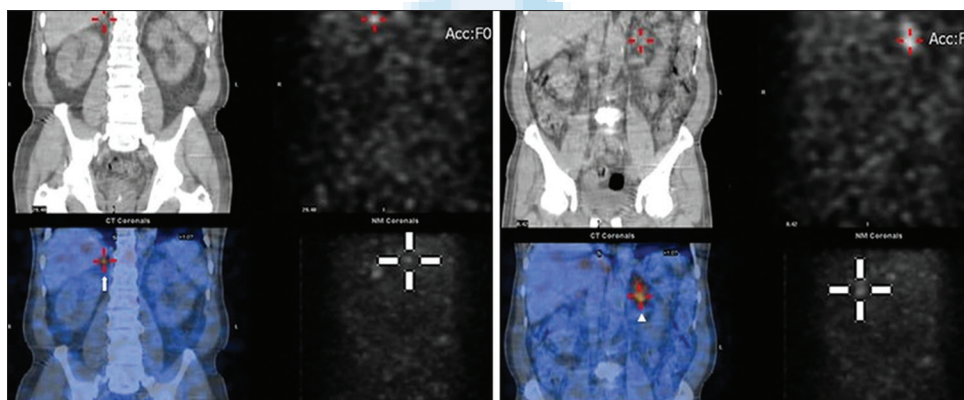
NP-59 SPECT/CT without drug discontinuation reached 91%, 88%, and 100% for the pathological findings, hypertension outcomes, and biochemical changes, respectively. In addition, 15 patients underwent NP-59 SPECT/CT with spironolactone in our study. Pathology revealed 14 APA cases and one patient with IHA. Among them, five (33%) showed a hypertension cure, nine (60%) had hypertension improvement, and one (7%) had refractory hypertension. Only 14 patients had available postoperative ARR data. All (100%) showed a biochemical cure. In contrast, of the 32 PA patients who underwent NP-59 SPECT/CT with drug discontinuation or modification, there were 30 (94%) cases of unilateral APA and 2 (6%) of IHA. Postoperatively, 12 (40%) patients exhibited hypertension cure and 16 (50%) showed improvement. All (100%) had a biochemical cure, the same as those who underwent NP-59 SPECT/CT without drug discontinuation or modification (data not shown). Compared with NP-59 SPECT/CT without drug discontinuation, the PPV of NP-59 SPECT/CT with drug discontinuation reached 94%, 90%, and 100% for the pathological findings, hypertension outcomes, and biochemical changes, respectively.

Table 1 shows the main characteristics of the 31 APA patients grouped by hypertension cure ( $n = 12$ ) and noncure ( $n = 19$ ) with logistic regression for the prognostic

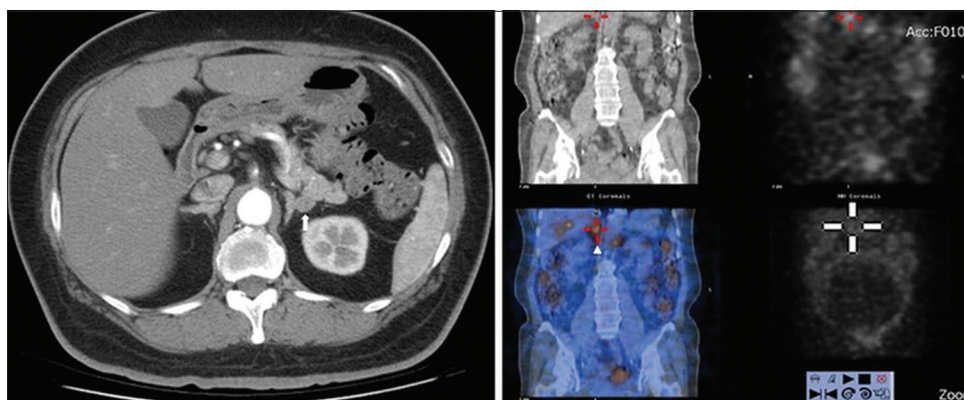
factors of hypertension cure. The results of the univariate comparison showed a significantly younger age ( $P = 0.014$ ) and higher preoperative PAC ( $P = 0.026$ ) in the cured group than in the noncured group. Logistic regression with multivariate adjustments showed that only higher PAC (odds ratio = 0.994, 95% confidence interval 0.989–0.999,  $P = 0.016$ ) was predictive of a better hypertension outcome. A similar result was noted in the 30 APA patients who underwent NP-59 SPECT/CT with drug discontinuation or modification [Supplemental Table 2]. In view of this, the GAM smoothing plot demonstrates that in 31 APA patients who underwent NP-59 SPECT/CT without drug discontinuation or modification, a higher preoperative PAC had a higher log odds ratio to predict hypertension cure after adrenalectomy [Figure 3]. Table 2 shows the DM outcome in nine APA patients who received adrenalectomy. Two patients (No. 9 and 34) showed remission of DM. Both had short durations of DM although no statistically significant differences in DM status were found before and after surgery.

### DISCUSSION

Noninvasive NP-59 SPECT/CT without drug discontinuation is a good imaging tool for the lateralization of adenoma in PA, with a PPV of 88%, which is comparable



**Figure 1:** I-131-6  $\beta$ -iodomethyl-norcholesterol single photon emission computed tomography/computed tomography of patient 6. Single photon emission computed tomography/computed tomography fusion images reveal increased I-131-6  $\beta$ -iodomethyl-norcholesterol uptake in the bilateral adrenal glands and predominance on the left side (white arrowhead). The total counts were 50.16 on the right side and 70.75 on the left side

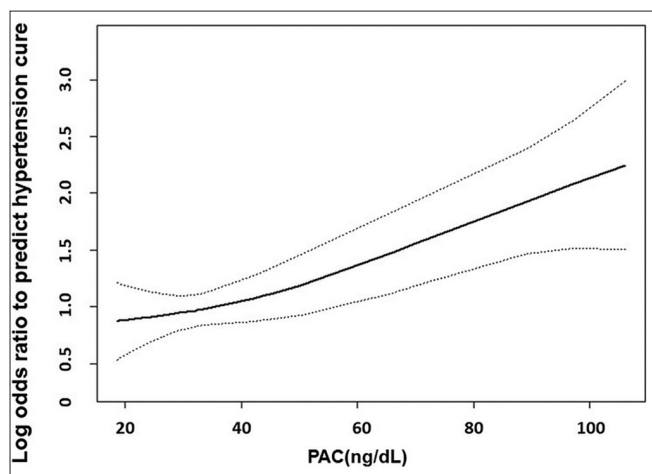


**Figure 2:** Adrenal computed tomography (left) and I-131-6  $\beta$ -iodomethyl-norcholesterol single photon emission computed tomography/computed tomography scan (right) of patient 17. A 1.4 cm tumor is seen in the left adrenal gland (white arrow) on computed tomography. I-131-6  $\beta$ -iodomethyl-norcholesterol single photon emission computed tomography/computed tomography, however, reveals increased tracer uptake on the contralateral side (white arrowhead)

**Table 2: Diabetes mellitus outcomes in 9 aldosterone-producing adenoma patients who underwent adrenalectomy**

Patient number	Preoperative				Postoperative				DM prognosis
	Duration of DM (years)	Glucose AC (mg/dl)	HbA1C (%)	Anti-DM meds (type)	Glucose AC (mg/dl)	HbA1C (%)	Anti-DM meds (type)	Follow-up interval (months)	
6	12	114	6.6	2	120	6.0	2	23	Nonimprovement
9	0.5	98	6.8	1	100	5.3	0	6	Improvement
11	3	192	6.5	2	155	7.1	3	12	Nonimprovement
12	4	142	6.1	2	101	5.3	3	12	Nonimprovement
14	10.5	142	7.8	3	143	6.7	3	7	Nonimprovement
17	14	112	6.5	1	125	6.9	1	28	Nonimprovement
21	10	172	8.8	3	149	8.7	4	6	Nonimprovement
22	10	128	6.8	3	176	8.7	4	6	Nonimprovement
34	0.13	129	6.6	2	113	6.0	0	83	Improvement

APA: Aldosterone-producing adenoma, Anti-DM meds: Anti-diabetes mellitus medications, DM: Diabetes mellitus, Glucose AC: Fasting plasma glucose, HbA1C: Glycated hemoglobin



**Figure 3:** Generalized additive model smoothing plot shows the log odds ratio to predict cure of hypertension with augmented PAC. aldosterone-producing adenoma patients with higher preoperative PAC had a higher log odds ratio to predict hypertension cure after adrenalectomy. PAC: plasma aldosterone concentration

to PPVs in studies with discontinuation of antihypertensive medications (85.7% to 100%) [14,16,22-24]. Continuing antihypertensive medications during NP-59 SPECT/CT avoided hypertension- and hypokalemia-related complications. Only one patient had symptomatic hyperglycemia secondary to dexamethasone suppression post-NP-59 injection. Although the association between hyperglycemia and steroids or NP-59 is uncertain, monitoring blood sugar is still necessary in patients at high risk of DM. Based on our results, adrenocortical scintigraphy without drug discontinuation has the following potential advantages: (1) avoidance of a hypertensive crisis or threat of hypokalemia, (2) reduced time to diagnosis (in the range of days to 4–6 weeks), and (3) avoidance of risks associated with invasive AVS.

Discontinuing spironolactone before NP-59 SPECT/CT may be not necessary. Fourteen of the 15 enrolled patients (93%) taking spironolactone during adrenocortical scintigraphy had APA and all exhibited meaningful NP-59 uptake with excellent postsurgical outcomes. It is recommended that spironolactone be discontinued for 4–6 weeks before adrenocortical scintigraphy due to its strong interference with the renin-angiotensin-aldosterone system [25,26]. However,

Nakahama *et al.* mentioned that although there was a tendency for a higher percentage of scintigraphy-positive patients to take spironolactone, no significant differences in antihypertensive medications were found [16]. Volpe *et al.* reported on a patient using a low dose (25 mg) of spironolactone during NP-59 SPECT scintigraphy, who showed lateralized uptake and was cured after adrenalectomy [22]. The continuing use of spironolactone could be considered in those PA patients who cannot discontinue the drug during adrenocortical scintigraphy.

Bilateral uptake during NP-59 scintigraphy (Patient 6) is a clinical dilemma. NP-59 scintigraphy can detect various degrees of excessive hormone production and provide stronger uptake in APA than in hyperplasia [14,17]. Patient 6 had significantly stronger uptake on the left than on the right side; thus, we suggested that the patient undergo left unilateral adrenalectomy. The patient achieved an excellent postsurgical outcome and clinical response. This highlights the efficacy of NP-59 SPECT/CT. Although lower sensitivity for small tumors is a concern in planar imaging, NP-59 SPECT/CT has proven useful for PA related to smaller adenomas. It can detect 0.8 mm adrenocortical microadenomas not apparent on CT [14,27]. Patient 17 had inconsistent results between CT and NP-59 SPECT/CT. She had NP-59 uptake on the right side and a left adrenal tumor (1.4 cm) on CT. AVS was performed and showed serum aldosterone overproduction on the right side. She underwent right adrenalectomy and pathology disclosed a 0.1 cm<sup>3</sup> microadenoma. NP-59 SPECT/CT successfully detected the right microadenoma, avoiding left adrenalectomy, while CT did not. This further confirms that NP-59 SPECT/CT is a reliable imaging tool for PA.

Hypertension cure or improvement in PA depends on many factors including age, gender, BMI, preoperative PAC, plasma renin, serum potassium levels, urinary aldosterone excretion, duration of hypertension, preoperative response to spironolactone, genotype, number of antihypertensive medications, tumor size, pathology findings, and family history [20,28]. In the current study, the hypertension cure and improvement rates were 35% and 53%, respectively. The current hypertension cure rate was comparable to published rates, which varied widely from 20% to 72% in a review of 16 published papers which included 2482 PA patients with drug discontinuation for lateralization. However, there was considerable variation in

the definition of hypertension outcomes in these papers [28]. Overall, the 88% hypertension response rate in this study is very impressive and meaningful. A high biochemical cure rate after adrenalectomy was achieved in PA patients without the discontinuation of antihypertensive medications. The definition of biochemical cure also varies between studies. We defined a postoperative ARR <30 ng/dL per ng/mL/h as indicating a cure, while others have used a postoperative decrease in PAC to 15 ng/dL or an unclear definition [29]. Some antihypertensive medications such as beta blockers may suppress the level of renin more than that of aldosterone, leading to a false-positive ARR result [1]. Our four patients who showed biochemical improvement with persistent postoperative beta-blocker use were excluded due to concerns regarding drug-related false-positive results. The remaining 30 (100%) patients with available ARR data experienced a biochemical cure, which is also compatible with published rates of 96%–100% in a review of seven studies which included 992 patients with drug discontinuation for lateralization [28]. In our study, we found that a higher preoperative PAC was associated with hypertension cure in the logistic regression model. Recent findings on *KCNJ5* somatic mutations in APA showed that carriers exhibited a higher PAC, had larger tumors, and had better hypertension prognosis after adrenalectomy than noncarriers [30,31]. The prevalence of *KCNJ5* somatic mutations is reported to be about 60% in the Taiwanese population [31,32]. Scholl *et al.* reported that tumors >17.4 mm in diameter and >201.6 mm<sup>2</sup> in area are more likely to harbor a *KCNJ5* mutation [33]. In our study population, there were 21 (68%) APA patients with large tumors >17 mm in diameter and 19 (61%) APAs >201.6 mm<sup>2</sup> in area (data not shown). It is rational to assume that most of our APA patients in this small series had *KCNJ5* mutations.

There is an association between glucose intolerance and PA. Many investigators have reported a prevalence of DM in PA patients of around 15%–25%. In control groups, this was about 10% [34-38]. However, the DM outcome in APA patients receiving adrenalectomy has been less frequently reported. In this study, we found that two (Patient 9 and 34) of the nine PA patients with DM went into remission after adrenalectomy. Of note, both had short durations of DM and the other seven patients all had DM for more than 3 years. It is possible that that long-term exposure to excess aldosterone or the natural course of DM results in permanently impaired beta cell function [39]. This result indicates that early surgery could provide the benefit of DM remission in APA patients.

One of the major limitations of the current study was the small study population. In addition, PA patients with negative NP-59 SPECT/CT were precluded from surgical intervention. Thus, there were no NP-59 true-negative and false-negative cases in this study. Third, the use of gene analysis was undeveloped during the study period, and we did not obtain complete genetic data.

## CONCLUSIONS

We conclude that NP-59 SPECT/CT without discontinuation or modification of antihypertensive medications is safe and results in a high positive prediction rate of adenoma,

hypertension improvement and biochemical cure in patients with PA. Before being widely applied in all patients with PA, large-scale randomized studies are required to confirm our observations.

## Acknowledgments

We would like to thank our cardiologists and urologists for providing patient care. We would also like to thank the radiologists and nuclear medicine physicians who provided updated information on imaging tools.

## Financial support and sponsorship

The study was partly funded by grants TCRD-TPE-104-RT-6 and TCRD-TPE-103-55 from Taipei Tzu Chi Hospital.

## Conflicts of interest

There is no conflict of interest.

## REFERENCES

- Funder JW, Carey RM, Mantero F, Murad MH, Reincke M, Shibata H, et al. The management of primary aldosteronism: Case detection, diagnosis, and treatment: An endocrine society clinical practice guideline. *J Clin Endocrinol Metab* 2016;101:1889-916.
- Rossi GP, Bernini G, Caliumi C, Desideri G, Fabris B, Ferri C, et al. A prospective study of the prevalence of primary aldosteronism in 1,125 hypertensive patients. *J Am Coll Cardiol* 2006;48:2293-300.
- Goh BK, Tan YH, Chang KT, Eng PH, Yip SK, Cheng CW, et al. Primary hyperaldosteronism secondary to unilateral adrenal hyperplasia: An unusual cause of surgically correctable hypertension. A review of 30 cases. *World J Surg* 2007;31:72-9.
- Volpe C, Hamberger B, Höög A, Mukai K, Calissendorff J, Wahrenberg H, et al. Primary aldosteronism: Functional histopathology and long-term follow-up after unilateral adrenalectomy. *Clin Endocrinol (Oxf)* 2015;82:639-47.
- Gioco F, Seccia TM, Gomez-Sanchez EP, Rossi GP, Gomez-Sanchez CE. Adrenal histopathology in primary aldosteronism: Is it time for a change? *Hypertension* 2015;66:724-30.
- Karashima S, Yoneda T, Kometani M, Ohe M, Mori S, Sawamura T, et al. Comparison of eplerenone and spironolactone for the treatment of primary aldosteronism. *Hypertens Res* 2016;39:133-7.
- Prejbisz A, Warchol-Celińska E, Lenders JW, Januszewicz A. Cardiovascular risk in primary hyperaldosteronism. *Horm Metab Res* 2015;47:973-80.
- Chou CH, Chen YH, Hung CS, Chang YY, Tzeng YL, Wu XM, et al. Aldosterone impairs vascular smooth muscle function: From clinical to bench research. *J Clin Endocrinol Metab* 2015;100:4339-47.
- Lin YH, Wu XM, Lee HH, Lee JK, Liu YC, Chang HW, et al. Adrenalectomy reverses myocardial fibrosis in patients with primary aldosteronism. *J Hypertens* 2012;30:1606-13.
- Strauch B, Petrák O, Zelinka T, Wichterle D, Holaj R, Kasalický M, et al. Adrenalectomy improves arterial stiffness in primary aldosteronism. *Am J Hypertens* 2008;21:1086-92.
- Funder JW, Carey RM, Fardella C, Gomez-Sanchez CE, Mantero F, Stowasser M, et al. Case detection, diagnosis, and treatment of patients with primary aldosteronism: An endocrine society clinical practice guideline. *J Clin Endocrinol Metab* 2008;93:3266-81.
- Chao CT, Wu VC, Kuo CC, Lin YH, Chang CC, Chueh SJ, et al. Diagnosis and management of primary aldosteronism: An updated review. *Ann Med* 2013;45:375-83.
- Spyridonidis TJ, Apostolopoulos DJ. Is there a role for nuclear medicine in diagnosis and management of patients with primary aldosteronism? *Hell J Nucl Med* 2013;16:134-9.
- Yen RF, Wu VC, Liu KL, Cheng MF, Wu YW, Chueh SC, et al.

- 131I-6beta-iodomethyl-19-norcholesterol SPECT/CT for primary aldosteronism patients with inconclusive adrenal venous sampling and CT results. *J Nucl Med* 2009;50:1631-7.
15. Haase M, Riestler A, Kröpil P, Hahner S, Degenhart C, Willenberg HS, et al. Outcome of adrenal vein sampling performed during concurrent mineralocorticoid receptor antagonist therapy. *J Clin Endocrinol Metab* 2014;99:4397-402.
16. Nakahama H, Fukuchi K, Yoshihara F, Nakamura S, Inenaga T, Takiuchi S, et al. Efficacy of screening for primary aldosteronism by adrenocortical scintigraphy without discontinuing antihypertensive medication. *Am J Hypertens* 2003;16:725-8.
17. Lu CC, Wu VC, Wu KD, Liu KL, Lin WC, Cheng MF, et al. Prognostic value of semiquantification NP-59 SPECT/CT in primary aldosteronism patients after adrenalectomy. *Eur J Nucl Med Mol Imaging* 2014;41:1375-84.
18. Chen YC, Su YC, Wei CK, Chiu JS, Tseng CE, Chen SJ, et al. Diagnostic value of I-131 NP-59 SPECT/CT scintigraphy in patients with subclinical or atypical features of primary aldosteronism. *J Biomed Biotechnol* 2011;2011:209787.
19. Chen YC, Wei CK, Chen PF, Tzeng JE, Chuang TL, Wang YF, et al. Seeking the invisible: I-131 NP-59 SPECT/CT for primary hyperaldosteronism. *Kidney Int* 2009;75:663.
20. Zhang X, Zhu Z, Xu T, Shen Z. Factors affecting complete hypertension cure after adrenalectomy for aldosterone-producing adenoma: Outcomes in a large series. *Urol Int* 2013;90:430-4.
21. Kuo CC, Wu VC, Huang KH, Wang SM, Chang CC, Lu CC, et al. Verification and evaluation of aldosteronism demographics in the Taiwan Primary Aldosteronism Investigation Group (TAIPAI Group). *J Renin Angiotensin Aldosterone Syst* 2011;12:348-57.
22. Volpe C, Enberg U, Sjögren A, Wahrenberg H, Jacobsson H, Törring O, et al. The role of adrenal scintigraphy in the preoperative management of primary aldosteronism. *Scand J Surg* 2008;97:248-53.
23. Simon DR, Palese MA. Noninvasive adrenal imaging in hyperaldosteronism. *Curr Urol Rep* 2008;9:80-7.
24. Citton M, Viel G, Rossi GP, Mantero F, Nitti D, Iacobone M, et al. Outcome of surgical treatment of primary aldosteronism. *Langenbecks Arch Surg* 2015;400:325-31.
25. Shapiro B, Grekin R, Gross MD, Freitas JE. Interference by spironolactone on adrenocortical scintigraphy and other pitfalls in the location of adrenal abnormalities in primary aldosteronism. *Clin Nucl Med* 1994;19:441-5.
26. Gross MD, Valk TW, Swanson DP, Thrall JH, Grekin RJ, Beierwaltes WH. The role of pharmacologic manipulation in adrenal cortical scintigraphy. *Semin Nucl Med* 1981;11:128-48.
27. Wong KK, Fig LM, Youssef E, Ferretti A, Rubello D, Gross MD, et al. Endocrine scintigraphy with hybrid SPECT/CT. *Endocr Rev* 2014;35:717-46.
28. Muth A, Ragnarsson O, Johannsson G, Wängberg B. Systematic review of surgery and outcomes in patients with primary aldosteronism. *Br J Surg* 2015;102:307-17.
29. Utsumi T, Kamiya N, Endo T, Yano M, Kamijima S, Kawamura K, et al. Development of a novel nomogram to predict hypertension cure after laparoscopic adrenalectomy in patients with primary aldosteronism. *World J Surg* 2014;38:2640-4.
30. Lenzini L, Rossitto G, Maiolino G, Letizia C, Funder JW, Rossi GP, et al. A meta-analysis of somatic KCNJ5 K(+) channel mutations in 1636 patients with an aldosterone-producing adenoma. *J Clin Endocrinol Metab* 2015;100:E1089-95.
31. Wu VC, Huang KH, Peng KY, Tsai YC, Wu CH, Wang SM, et al. Prevalence and clinical correlates of somatic mutation in aldosterone producing adenoma-Taiwanese population. *Sci Rep* 2015;5:11396.
32. Cheng CJ, Sung CC, Wu ST, Lin YC, Sytwu HK, Huang CL, et al. Novel KCNJ5 mutations in sporadic aldosterone-producing adenoma reduce Kir3.4 membrane abundance. *J Clin Endocrinol Metab* 2015;100:E155-63.
33. Scholl UI, Healy JM, Thiel A, Fonseca AL, Brown TC, Kunstman JW, et al. Novel somatic mutations in primary hyperaldosteronism are related to the clinical, radiological and pathological phenotype. *Clin Endocrinol (Oxf)* 2015;83:779-89.
34. Chen W, Li F, He C, Zhu Y, Tan W. Elevated prevalence of abnormal glucose metabolism in patients with primary aldosteronism: A meta-analysis. *Ir J Med Sci* 2014;183:283-91.
35. Reincke M, Meisinger C, Holle R, Quinkler M, Hahner S, Beuschlein F, et al. Is primary aldosteronism associated with diabetes mellitus? Results of the German Conn's registry. *Horm Metab Res* 2010;42:435-9.
36. Matrozkova J, Steichen O, Amar L, Zacharieva S, Jeunemaitre X, Plouin PF, et al. Fasting plasma glucose and serum lipids in patients with primary aldosteronism: A controlled cross-sectional study. *Hypertension* 2009;53:605-10.
37. Umpierrez GE, Cantey P, Smiley D, Palacio A, Temponi D, Luster K, et al. Primary aldosteronism in diabetic subjects with resistant hypertension. *Diabetes Care* 2007;30:1699-703.
38. Murase K, Nagaishi R, Takenoshita H, Nomiya T, Akehi Y, Yanase T, et al. Prevalence and clinical characteristics of primary aldosteronism in Japanese patients with type 2 diabetes mellitus and hypertension. *Endocr J* 2013;60:967-76.
39. Luther JM. Effects of aldosterone on insulin sensitivity and secretion. *Steroids* 2014;91:54-60.