



## Case Report

# Nonfatal pulmonary embolism associated with the use of compression stockings in the lithotomy position after spinal anesthesia

I-Wen Chen<sup>a</sup>, Cheuk-Kwan Sun<sup>b</sup>, Jen-Yin Chen<sup>c,d</sup>, Chien-Ming Lin<sup>a</sup>, Kuo-Chuan Hung<sup>c\*</sup>

<sup>a</sup>Department of Anesthesiology, E-Da Hospital, Kaohsiung, Taiwan, <sup>b</sup>Department of Emergency Medicine, E-Da Hospital and I-Shou University, Kaohsiung, Taiwan, <sup>c</sup>Department of Anesthesiology, Chi Mei Medical Center, Tainan, Taiwan, <sup>d</sup>Department of the Senior Citizen Service Management, Chia Nan University of Pharmacy and Science, Tainan, Taiwan

Received : 02-Mar-2017  
Revised : 18-Apr-2017  
Accepted : 08-Jun-2017

### ABSTRACT

A 73-year-old male (height, 156 cm; body weight, 51 kg), without a history of cardiovascular disease or thromboembolic events, was scheduled for transurethral resection of the prostate under spinal anesthesia. Spinal anesthesia was administered with hyperbaric bupivacaine, resulting in an upper anesthetic level of T6. Before surgery, compression stockings were applied to both lower limbs, and the patient was placed in the lithotomy position. Approximately 15 min later, he complained of intolerable chest tightness, followed by tachycardia (heart rate, 110 beats/min) and desaturation (oxygen saturation [SaO<sub>2</sub>], 90%). Tracheal intubation was performed immediately. The decrease in end-tidal partial pressure of carbon dioxide (EtCO<sub>2</sub>) with an increase in the arterial carbon dioxide partial pressure-EtCO<sub>2</sub> gradient (16 mmHg) suggested pulmonary embolism (PE), which may have been induced by leg manipulation. The patient developed transient hypotension after tracheal intubation; however, his hemodynamic profile stabilized after inotropes administration. Subsequent tests showed normal cardiac enzyme levels; however, his D-dimer levels increased significantly. Imaging confirmed deep vein thrombosis (DVT) and PE. Anticoagulation with warfarin was administered, and he was discharged on the postoperative day 11 without complications. In conclusion, DVT is often a cause of PE. Preoperative identification of DVT risk factors and respiratory symptoms as well as intraoperative monitoring of arterial SaO<sub>2</sub> are vital for timely diagnosis of PE, especially in patients receiving intraoperative lower limb manipulation.

**KEYWORDS:** *Compression stockings, Lithotomy position, Pulmonary embolism, Spinal anesthesia*

## INTRODUCTION

Pulmonary embolism (PE) is a relatively rare cardiovascular emergency and often occurs as a complication of deep venous thrombosis (DVT) [1]. Early diagnosis of PE is fundamental for the implementation of immediate, effective treatment to reduce mortality. However, PE continues to present a diagnostic challenge due to its nonspecific clinical presentation. Herein, we describe an episode of nonfatal PE associated with the use of compression stockings in the lithotomy position. The patient reviewed the Chinese translation of this article and gave written permission to publish the report.

## CASE REPORT

A 73-year-old male (the American Society of Anesthesiologists Class II; height, 156 cm; and body weight, 51 kg) was scheduled to undergo transurethral resection of the prostate due to prostate enlargement. He had no history of cardiovascular disease or thromboembolic events. He had received


spinal anesthesia 1 month ago for ureterorenoscopic stone manipulation (URSM), without complications. In his previous surgery, he did not have any hypersensitivity reaction to anesthetic agents (0.5% hyperbaric bupivacaine and midazolam) or antibiotics (cefazolin).

The preoperative fasting period was about 8 h. During the preoperative physical examination, there was no notable swelling or tenderness in the legs. The hemodynamic profiles revealed a blood pressure (BP) of 155/98 mmHg, heart rate (HR) of 66 beats/min, and respiratory rate of 12 breaths/min. The electrocardiography (ECG), chest radiography, and coagulation test results showed no remarkable features. After standard monitoring (ECG, capnography, pulse oximetry, and noninvasive BP monitoring) was applied, spinal anesthesia was performed,

\*Address for correspondence:

Dr. Kuo-Chuan Hung,  
Department of Anesthesiology, Chi Mei Medical Center, 901, Chung-Hwa Road, Yung Kung District, Tainan, Taiwan.  
E-mail: ed102605@gmail.com

### Access this article online

<b>Quick Response Code:</b> 	<b>Website:</b> <a href="http://www.tcmjmed.com">www.tcmjmed.com</a>
	<b>DOI:</b> 10.4103/tcmj.tcmj_81_17

This is an open access article distributed under the terms of the Creative Commons Attribution-NonCommercial-ShareAlike 3.0 License, which allows others to remix, tweak, and build upon the work non-commercially, as long as the author is credited and the new creations are licensed under the identical terms.

**For reprints contact:** [reprints@medknow.com](mailto:reprints@medknow.com)

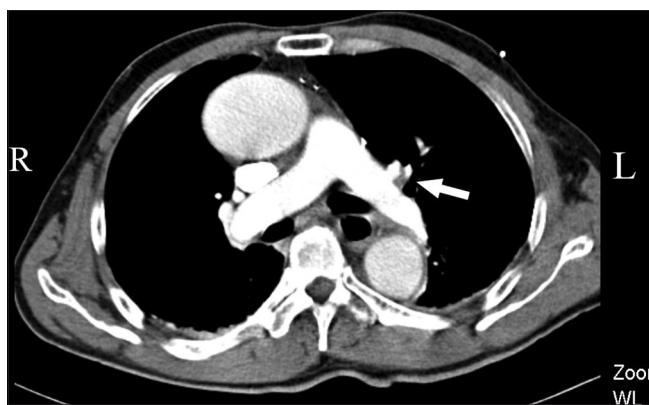**How to cite this article:** Chen IW, Sun CK, Chen JY, Lin CM, Hung KC. Nonfatal pulmonary embolism associated with the use of compression stockings in the lithotomy position after spinal anesthesia. *Tzu Chi Med J* 2017;29:228-31.

and 12 mg of 0.5% hyperbaric bupivacaine was administered slowly. The patient was then positioned supine, and a sensory block to T6 was confirmed by the pinprick test 10 min later. During spinal anesthesia, 400 mL of crystalloid solution was administered, and there were no significant changes in BP or HR. No sympathomimetic drugs, such as ephedrine or other sedatives, were given. Afterward, cefazolin was administered intravenously, and 6 L of 100% oxygen (O<sub>2</sub>) was administered through an oxygen mask in a routine manner.

Before surgery, the patient's lower limbs were fitted with compression stockings, and he was placed in the lithotomy position using a knee-crutch-type leg holder system. Approximately 15 min after leg manipulation, the patient complained of intolerable chest tightness and shortness of breath. On physical examination, bilateral breath sounds were clear, without wheezing or crackles, and his hemodynamic profile was stable (BP 132/85 mmHg and HR 62 beats/min). No flushing, urticaria, angioedema, or skin rash was found. The spinal anesthetic level was rechecked and confirmed to reach only the T5–T6 level. An initial diagnosis of acute myocardial infarction (MI) was made, and 3 mg morphine was administered for chest pain. Subsequent diagnostic workup included a 12-lead ECG, which did not reveal changes in the ischemic pattern, and analysis of cardiac enzyme levels.

The patient became progressively irritable, and his HR increased from 62 beats/min to 110 beats/min with a BP of 98/60 mmHg. Desaturation (oxygen saturation [SaO<sub>2</sub>], approximately 89%) was also noted. Tracheal intubation was immediately performed after intravenous administration of induction agents, including midazolam 10 mg, propofol 1 mg/kg, fentanyl 50 µg, and rocuronium 50 mg, followed by mechanical ventilation. At the onset of ventilation, the end-tidal partial pressure of carbon dioxide (EtCO<sub>2</sub>) was between 0 and 19 mmHg. Initial arterial blood gas analysis revealed a pH of 7.49, an arterial O<sub>2</sub> tension (PaO<sub>2</sub>) of 82.6 mmHg, and an arterial carbon dioxide (CO<sub>2</sub>) tension (arterial carbon dioxide partial pressure [PaCO<sub>2</sub>]) of 35.3 mmHg (fractional inspired O<sub>2</sub>, 1.0). PE was suspected due to the increased dead space (PaCO<sub>2</sub>-EtCO<sub>2</sub>, 16 mmHg). Transesophageal echocardiography (TEE) was performed, but there was no direct visualization of thromboemboli in the ventricles and no evidence of right ventricular dysfunction.

The patient's hemodynamic profile destabilized (BP 70/50 mmHg and HR 120 beats/min) after tracheal intubation, but improved after using an inotropic agent (dopamine 5 mcg/kg/min). The operative procedure was postponed, and the patient was transferred to the Intensive Care Unit (ICU) for monitoring and stabilization. A series of diagnostic workups revealed that the cardiac enzyme (creatinine kinase-MB and troponin I) levels were within normal ranges, whereas D-dimer levels were significantly increased (>35200 µg/L). Chest computed tomography (CT) scan confirmed embolism of the left pulmonary artery [Figure 1]. Impedance plethysmography was performed and the result indirectly indicated the presence of left lower leg venous thrombosis [Figure 2]. Considering his hemodynamic stability as well as the episodes of upper gastrointestinal bleeding and hematuria during his postoperative stay



**Figure 1:** Chest computed tomography scan revealed a filling defect in the apical posterior branch of the left pulmonary artery (arrow), indicating pulmonary thromboembolism

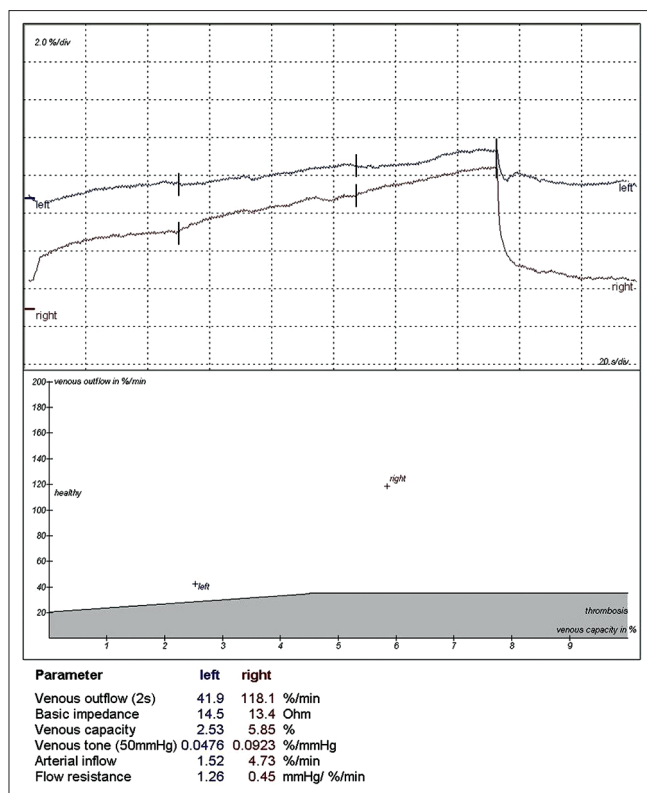
in the ICU, anticoagulants, such as unfractionated heparin or low molecular weight heparin, were not given immediately after diagnosis. Anticoagulant therapy with warfarin, which commenced in the ICU after the bleeding episodes were controlled, resulted in no complications. Tracheal extubation was performed on postoperative day 3, and the patient was discharged uneventfully on postoperative day 11. The patient recovered fully without notable sequelae after 4-month follow-up.

## DISCUSSION

DVT is often a cause of PE. In general, the predisposing factors for DVT include patient-related (such as heart failure and malignancy) and setting-related (such as major general surgery and trauma) risk factors [2,3]. Although identification of these predisposing factors may allow clinicians to maintain a high level of suspicion of DVT, nearly 50% of first venous thrombotic events are idiopathic, and some patients may be asymptomatic [4]. As shown in our patient, there was no notable swelling or tenderness in the legs during the pre-operative physical examination. The predisposing factor for DVT was old age, which is a weak factor according to previous reports [2,3]. Recent surgery is also one of the risk factors of DVT, but formation of DVT after URSM is very rare.

When cardiopulmonary distress occurs suddenly following spinal anesthesia, the differential diagnosis should include high sympathectomy from spinal anesthesia, anaphylaxis, MI, and PE. Sympathetic blockade from high spinal anesthesia often leads to bradycardia and hypotension [5]. In our case, bradycardia was not observed, so a high spinal anesthesia was unlikely. Antibiotics have been identified as a significant cause of anaphylaxis in the perioperative setting [6]. The patient received the same antibiotics (cefazolin) as in his previous surgery without developing a hypersensitivity reaction. There was also no urticaria or skin rash found; therefore, anaphylaxis was also unlikely. There have been several case reports of myocardial injury due to coronary artery spasm following the use of ephedrine during spinal anesthesia [7-9]. As ephedrine was not used, and our patient did not have a history of cardiovascular disease, this diagnosis of MI was also unlikely.

In most cases of PE, the clinical symptoms may include dyspnea, chest pain, and syncope, either individually or in



**Figure 2:** Impedance plethysmography revealed a relative decrease in venous outflow and venous capacity of the left lower leg, indirectly indicating the presence of left lower leg venous thrombosis

combination [2]. Cardiovascular collapse may occur immediately following massive PE. Smaller and distal emboli may cause areas of alveolar pulmonary hemorrhage, resulting in hemoptysis, pleuritis, and mild pleural effusion (pulmonary infarction syndrome) [2]. The effect of pulmonary infarction syndrome on the gas exchange is usually mild in patients without cardiorespiratory disease [10]. Pleuritic chest pain and dyspnea were the initial signs of PE in our patient in whom the left pulmonary artery was occluded. As these signs occurred following leg manipulations (using compression stockings and lithotomy), it is possible that the PE was attributable to pre-existing DVT of the left lower extremity that was dislodged by the compression stockings. This is supported by the results of impedance plethysmography that indirectly indicated the preoperative presence of venous thrombosis. The calf support used in lithotomy position may also have exerted external compression on the lower leg, [11] thereby further increasing the chance of embolus dislodgment. In contrast to sudden cardiovascular collapse following massive PE, pleuritic chest pain may not occur immediately after the pulmonary arterial bed is occluded by smaller emboli, which may have been the reason that these signs occurred 15 min after leg manipulations.

In a literature review by Desai *et al.*, they found that there were 14 cases of PE related to the use of Esmarch bandage or tourniquet inflation [12]. They suggested that an increase in compartment pressure in the limb caused by these medical devices could dislodge thrombi in the lower limbs and lead to massive PE. Most of these cases were reported in patients

undergoing fracture fixation after trauma, and immobilization from the time of injury to the surgical intervention may be an important factor for the development of DVT. Our report demonstrated that the use of compression stockings in the lithotomy position may be a possible precipitating factor of PE in patients with occult DVT. Although the association between compression stockings and PE may have been a clinical concern in our patient, compression stockings are often used as a prophylactic measure against DVT. Our report does not indicate or recommend that this prophylactic measure should be abandoned in surgical patients.

The typical presentation of PE includes cyanosis, hypoxemia, hypotension, pleuritic chest pain, and ECG abnormality (nonspecific ST segment or T-wave change). Pleuritic chest pain, with or without dyspnea, is one of the most frequent presentations of PE [13,14]. These characteristic signs and symptoms can be masked under general anesthesia, and the diagnosis of PE can be unrecognized clinically. The change in EtCO<sub>2</sub> indicates the possibility of PE, but this diagnostic tool is not specific [15]. Although regional anesthesia without sedation may also allow the clinician to detect the early signs of PE, it should be acknowledged that identification of DVT may be more important than paying attention to acute PE.

Patients with isolated subsegmental PE or incidental PE may have less severe clinical presentations compared to those with proximal PE. As anticoagulation therapy and/or thrombolysis may increase bleeding risk, there is still no evidence from randomized controlled trials supporting the effectiveness and safety of anticoagulation therapy and/or thrombolysis in patients with incidental subsegmental PE [16,17]. Our patient had episodes of upper gastrointestinal bleeding and hematuria during his stay in the ICU. Considering that he was hemodynamically stable, only warfarin was administered to prevent future recurrences, embolism, and thrombosis-related death.

The diagnostic tests for suspected PE include echocardiography, D-dimer, ventilation-perfusion scintigraphy, CT angiography, and pulmonary angiography [2]. When the results of other noninvasive imaging tests are equivocal, pulmonary angiography is a reliable test, but this test is invasive and poses hazards. Mortality due to pulmonary angiography was reported to be approximately 0.2% [2]. Emergency CT or bedside echocardiography is recommended for diagnostic purposes in patients with high-risk PE [2]. In our patient, both TEE and CT were performed to confirm the diagnosis.

There is a limitation to our report. Instead of invasive venography, only impedance plethysmography was performed in our patient to confirm the diagnosis of DVT. Therefore, the location of the thrombus could not be identified.

## CONCLUSION

For patients at low risk of PE/DVT, preoperative identification of DVT risk factors and possible precipitating factors as well as intraoperative monitoring of chest pain, dyspnea, and decreased SaO<sub>2</sub> is vital for timely diagnosis of PE, especially in patients receiving perioperative manipulation of the lower limb. Not only do patients with high risk for PE/DVT need

to be targeted for interview and physical examination of the lower legs but also further D-dimer examination and/or venous ultrasound should also be performed before the operation. Consultation with a cardiologist may be needed. As prevention is better than cure, thrombus identification is more important than paying attention to acute PE.

#### Acknowledgments

We thank the patient for providing written informed consent.

#### Declaration of patient consent

The authors certify that the patient has obtained appropriate patient consent form. In the form, the patient has given his consent for his images and other clinical information to be reported in the journal. The patient understands that his name and initial will not be published and due efforts will be made to conceal their identity, but anonymity cannot be guaranteed.

#### Financial support and sponsorship

Nil.

#### Conflicts of interest

There are no conflicts of interest.

#### REFERENCES

1. Sevitt S, Gallagher N. Venous thrombosis and pulmonary embolism. A clinico-pathological study in injured and burned patients. *Br J Surg* 1961;48:475-89.
2. Torbicki A, Perrier A, Konstantinides S, Agnelli G, Galiè N, Pruszczyk P, et al. Guidelines on the diagnosis and management of acute pulmonary embolism: The Task Force for the Diagnosis and Management of Acute Pulmonary Embolism of the European Society of Cardiology (ESC). *Eur Heart J* 2008;29:2276-315.
3. Anderson FA Jr, Spencer FA. Risk factors for venous thromboembolism. *Circulation* 2003;107:19-6.
4. Naess IA, Christiansen SC, Romundstad P, Cannegieter SC, Rosendaal FR, Hammerstrøm J, et al. Incidence and mortality of venous thrombosis: A population-based study. *J Thromb Haemost* 2007;5:692-9.
5. Pollard JB. Cardiac arrest during spinal anesthesia: Common mechanisms and strategies for prevention. *Anesth Analg* 2001;92:252-6.
6. Gonzalez-Estrada A, Pien LC, Zell K, Wang XF, Lang DM. Antibiotics are an important identifiable cause of perioperative anaphylaxis in the United States. *J Allergy Clin Immunol Pract* 2015;3:101-5.e1.
7. Khavandi A, Gatward JJ, Whitaker J, Walker P. Myocardial infarction associated with the administration of intravenous ephedrine and metaraminol for spinal-induced hypotension. *Anaesthesia* 2009;64:563-6.
8. Hirabayashi Y, Saitoh K, Fukuda H, Mitsuhashi H, Shimizu R. Coronary artery spasm after ephedrine in a patient with high spinal anesthesia. *Anesthesiology* 1996;84:221-4.
9. Wahl A, Eberli FR, Thomson DA, Luginbühl M. Coronary artery spasm and non-Q-wave myocardial infarction following intravenous ephedrine in two healthy women under spinal anaesthesia. *Br J Anaesth* 2002;89:519-23.
10. Stein PD, Henry JW. Clinical characteristics of patients with acute pulmonary embolism stratified according to their presenting syndromes. *Chest* 1997;112:974-9.
11. Mizuno J, Takahashi T. Male sex, height, weight, and body mass index can increase external pressure to calf region using knee-crutch-type leg holder system in lithotomy position. *Ther Clin Risk Manag* 2016;12:305-12.
12. Desai S, Prashantha PG, Torgal SV, Rao R. Fatal pulmonary embolism subsequent to the use of Esmarch bandage and tourniquet: A case report and review of literature. *Saudi J Anaesth* 2013;7:331-5.
13. Miniati M, Prediletto R, Formichi B, Marini C, Di Ricco G, Tonelli L, et al. Accuracy of clinical assessment in the diagnosis of pulmonary embolism. *Am J Respir Crit Care Med* 1999;159:864-71.
14. Stein PD, Saltzman HA, Weg JG. Clinical characteristics of patients with acute pulmonary embolism. *Am J Cardiol* 1991;68:1723-4.
15. Manara A, D'hoore W, Thys F. Capnography as a diagnostic tool for pulmonary embolism: A meta-analysis. *Ann Emerg Med* 2013;62:584-91.
16. Ikesaka R, Carrier M. Clinical significance and management of subsegmental pulmonary embolism. *J Thromb Thrombolysis* 2015;39:311-4.
17. Yoo HH, Queluz TH, El Dib R. Anticoagulant treatment for subsegmental pulmonary embolism. *Cochrane Database Syst Rev* 2014;4:CD010222.