



Treating intracranial dural arteriovenous fistulas with gamma knife radiosurgery: A single-center experience

Guan-Chyuan Wang^{a,b}, Kuan-Pin Chen^a, Tsung-Lang Chiu^{a,c}, Chain-Fa Su^{a,c*}

^aDepartment of Neurosurgery, Neuro-Medical Scientific Center, Buddhist Tzu Chi General Hospital, Hualien, Taiwan, ^bDepartment of Surgery, Buddhist Tzu Chi General Hospital, Hualien, Taiwan, ^cSchool of Medicine, Tzu Chi University, Hualien, Taiwan

ABSTRACT

Objective: We evaluated the effectiveness and safety of gamma knife radiosurgery (GKRS) for the treatment of intracranial dural arteriovenous fistulas (dural AVFs) over the past 10 years. **Materials and Methods:** The records of 21 patients diagnosed with dural AVFs between 2004 and 2014 and treated with GKRS were reviewed retrospectively. Complete obliteration (CO) was defined as total symptom relief plus confirmation through magnetic resonance imaging or conventional angiography. **Results:** The median follow-up was 70.5 months (range 3–136 months). Five patients underwent embolization (2 after GKRS). One patient underwent GKRS twice. The CO rate was 47%, and partial to CO rate was 88%. The complete symptom resolution rate was 77%, and all patients achieved partial to complete symptom resolution. The CO rates for Borden Type I and Type II/III dural AVFs were 66.7% and 25% ($P = 0.153$), respectively, and complete symptom-free rates were 76.9% and 75.0% ($P = 1.000\%$), respectively. The median duration between initial GKRS and complete symptom resolution was 14.3 months. The median treatment to image-free durations for Borden Type I and Type II/III dural AVFs were 25.9 and 60.4 months ($P = 0.028$), respectively, and treatment to symptom-free durations were 10.6 and 36.7 months ($P = 0.103$), respectively. One patient had a recurrent hemorrhage. Two patients experienced brain edema after stereotactic radiosurgery and one patient experienced cystic formation after GKRS. The morbidity rate was 19% (four patients) and there was no mortality. **Conclusion:** Treatment with GKRS for dural AVFs offers a favorable rate of obliteration. Patients with dural AVFs that are refractory or not amenable to endovascular or surgical therapy may be safely and effectively treated using GKRS.

KEYWORDS: Arteriovenous fistula, Dural arteriovenous fistula, Gamma knife, Stereotactic radiosurgery

Received : 05-08-2016
Revised : 08-10-2016
Accepted : 02-11-2016

INTRODUCTION

An intracranial dural arteriovenous fistula (dural AVF), also known as a dural arteriovenous malformation, is a type of intracranial vascular malformation. A dural AVF is a connection between an intracranial artery and a dural venous sinus. The current treatment strategies for dural AVFs include microsurgical ligation, transarterial or transvenous embolization, stereotactic radiosurgery (SRS), and various combinations of these options [1-3].

There are two major classification systems for dural AVFs according to the location and drainage of the

fistula, the Borden classification and the Cognard classification [4,5]. The Cognard classification can be merged with the Borden classification according to cortical venous drainage [Table 1] [6]. Carotid-cavernous (CC) fistulas, which connect the internal carotid artery and a cavernous sinus, have their own classification


*Address for correspondence:

Dr. Chain-Fa Su,
Department of Neurosurgery, Buddhist Tzu Chi
General Hospital, 707, Section 3, Chung-Yang Road,
Hualien, Taiwan.
E-mail: suchainfa@yahoo.com.tw

This is an open access article distributed under the terms of the Creative Commons Attribution-NonCommercial-ShareAlike 3.0 License, which allows others to remix, tweak, and build upon the work non-commercially, as long as the author is credited and the new creations are licensed under the identical terms.

For reprints contact: reprints@medknow.com

How to cite this article: Wang GC, Chen KP, Chiu TL, Su CF. Treating intracranial dural arteriovenous fistulas with gamma knife radiosurgery: A single-center experience. Tzu Chi Med J 2017;29:18-23.

Access this article online	
Quick Response Code: 	Website: www.tcmjmed.com
	DOI: 10.4103/tcmj.tcmj_4_17

system. These fistulas are classified using the Barrow classification according to high-direct fistula flow or low-indirect fistula flow and the location of the fistula [Table 2] [7]. Barrow Type A CC fistulas are defined as high flow, with direct drainage from the internal carotid artery to a cavernous sinus, and are related to trauma; this type of fistula is beyond the scope of this study.

In this article, we evaluate the initial presentation, clinical course, and outcome of dural AVFs at our hospital. Gamma knife radiosurgery (GKRS) is the major treatment modality for dural AVFs at our hospital because of patient preference, embolism technique limitations, and physician preference. Therefore, this article can serve as a reference for those interested in dural AVFs treated using GKRS and other SRS techniques.

MATERIALS AND METHODS

Study population

Patients enrolled in this study included those diagnosed with dural AVFs between 2004 and 2014 at Tzu Chi General Hospital, Hualien, Taiwan. Patients who did not have dural AVFs confirmed through angiography were excluded from the study. The study was conducted in accordance with the Declaration of Helsinki and was approved by the local ethics committee of Tzu Chi General Hospital, Hualien, Taiwan. (IRB 103-88-B) Informed written consent was waived because the study was a retrospective data analysis.

Data collection

The data collected included gender, age, initial symptoms, type of dural fistula, treatment strategy, radiosurgery dose, volume treated using GKRS, imaging results, length of

Table 1: Borden classification system of dural arteriovenous fistulas

Borden type	Description
I	Drainage into dural venous sinus or meningeal vein
II	Drainage into dural venous sinus and cortical venous drainage
III	Direct drainage into cortical vein

Table 2: Barrow classification system of carotid-cavernous fistulas

Barrow type	Description
A	Direct high flow shunts between internal carotid artery and cavernous sinus
B	Indirect low-flow shunts between meningeal branches of internal carotid artery and cavernous sinus
C	Indirect low-flow shunts between meningeal branches of external carotid artery and cavernous sinus
D	Indirect low-flow shunts between meningeal branches of both internal carotid artery and external carotid artery and cavernous sinus

patient follow-up, and outcome. Complete obliteration (CO) was defined as no dural AVFs observed on either magnetic resonance imaging (MRI) or angiography during follow-up. Partial obliteration was defined as regression or decreasing of dural AVFs nidus or venous drainage on MRI or angiography, mainly defined by the radiologist. Partial symptom resolution was defined as decreasing symptoms including tinnitus, proptosis, or chemosis according to patient report and physician observation. The treatment to image-free duration was defined as the duration between the patient receiving radiosurgery and CO confirmed through imaging. The treatment to symptom-free duration was defined as the duration between the patient receiving radiosurgery and the time at which the patient became symptom-free.

Radiosurgery methods

After local anesthesia had been applied, a Leksell stereotactic frame (Elekta Instrument AB, Stockholm, Sweden) was rigidly fixed on the patient's head, following which digital subtraction angiography images and contrast-enhanced brain MRI (1–2-mm thickness) were acquired. These images were sent to a GammaPlan computer (Elekta Instruments AB, Stockholm, Sweden) and the region of interest was planned [Figure 1]. A 201 cobalt-60 source gamma knife system (Model C, Elekta Instruments) was used. After complete planning, the patient's head and frame were fixed in a collimator helmet and the treatment was performed until the conformal field encompassed the treatment volume. For dural AVFs, the treatment dose ranged from 13 to 18 Gy at an isodose level of 50%. The dose was determined on the basis of the target volume (the larger the volume, the smaller the dose) and whether critical organs (e.g., optical apparatus or brain stem) were near the radiation target. For abnormal AVFs which drained into the sinus wall, the target was along the involved sinus wall [8]. Arterial feeders and cortical drainage veins were not considered treatment targets.

Statistical analysis

SPSS 18 (IBM Corporation, Armonk, NY, USA) was used as the statistical analysis tool. Univariate categorical analyses were conducted using the Pearson Chi-square and Fisher's exact test. Univariate continuous variable analyses were conducted using Student's *t*-test. Kaplan–Meier survival analysis was used to calculate the treatment to symptom-free and treatment to complete image-free durations. A value of $P < 0.05$ was considered statistically significant.

RESULTS

Margin dose and treated volume using gamma knife radiosurgery

The median follow-up was 70.5 months (range 3–136 months). Thirteen of the 21 patients treated had Borden Type I and 8 had Borden Type II/III dural AVFs

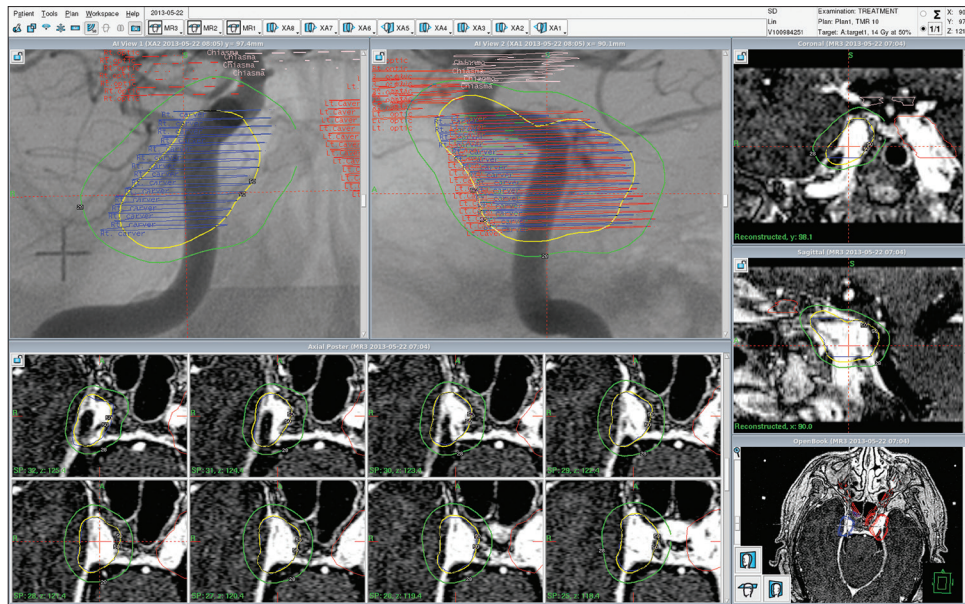


Figure 1: Digital subtraction angiogram superimposed on magnetic resonance images showing the dose planning for radiosurgery. The treating marginal dose level (inner isodose line) covers the border of the cavernous sinus

(Borden II =7; Borden III =1) [Table 3]. The cavernous sinus was the most common location of dural AVFs (13 patients), followed by the superior sagittal sinus and the transverse sinus [Table 4]. Thirteen patients had CC fistulas and eight patients had non-CC fistulas. The average dose applied was 15.8 Gy (range =13–18 Gy). The average treated volume was 9.76 mL. Patient’s age ranged from 14 to 79 years (mean: 56.3 years). A pulsatile bruit was the most common initial symptom [Table 5].

Treatment outcome

Five patients underwent embolization (2 after gamma knife) and one patient received a second radiosurgery [Table 6]. Four patients did not have follow-up images and thus were excluded from the CO rate calculation. The CO rate was 47%, and the partial to CO rate was 88%. The complete symptom resolution rate was 77%, and all patients achieved partial to complete resolution of their symptoms [Table 7]. The CO rates for non-CC fistulas and CC fistulas were 66.7% and 62.5% ($P = 0.347$), respectively. The CO rates for Borden Type I and Borden Type II/III dural AVFs were 66.7% and 25% ($P = 0.153$), respectively, and the complete symptom-free rates were 76.9% and 75.0% ($P = 1.000\%$), respectively. The median duration between initial GKRS and complete symptom resolution was 14.3 months. The median treatment to image-free durations for Borden Type I and Borden Type II/III dural AVFs were 25.9 and 60.4 months ($P = 0.028$), respectively, and the median treatment to symptom-free durations were 10.6 and 36.7 months ($P = 0.103$), respectively [Figure 2]. One patient had a recurrent hemorrhage. Two patients experienced brain edema after

Table 3: Borden type classification of the 21 patients

Borden type	Case number
I	13
II	7
III	1

Table 4: Locations of dural arteriovenous fistulas of the 21 patients

Locations	Number of patients
Cavernous sinus	13
Superior sagittal sinus	3
Transverse sinus	3
Vein of Labbe	1
Vein of Galen	1
Internal jugular vein	2

Table 5: Initial symptoms and presentations of the 21 dural arteriovenous fistulas patients

Symptoms	Patient number
Pulsatile bruit	10
Chemosis	8
Headache	6
Diplopia	4
Proptosis	5
Hemorrhage	1
Incidental	2

SRS and one patient experienced cystic formation after GKRS. The morbidity rate was 19% (four of 21 patients) and there was no mortality.

DISCUSSION

GKRS for dural AVFs has been shown to be effective in many studies [9-11]. In a recent systemic review [6] of 19 articles and 743 patients, the mean CO rate for dural AVFs after GKRS treatment was 63%. In our study, we had a CO rate of 47%. The short follow-up duration in the present study might have contributed to the inferior obliteration rate as endothelial proliferation in response to SRS might occur gradually. In one study, 41% of patients treated with SRS achieved CO after 21 months [12]. Therefore, if we exclude patients with <6 months of follow-up from

Table 6: Gamma knife radiosurgery margin dose and treated volume in 21 patients with dural arteriovenous fistulas

Variable	Value (range)
Mean age (range)	56.3 years (14-79)
Mean margin dose (range) at 50% isodose level	15.8 Gy (13-18)
Mean volumes (range)	9.76 ml (1.9-30.5)
Female:male	11:10
CC fistula group:non-CC fistula group	13:8
Embolization	5*
Second radiosurgery	1

*: 2 after GKRS. CC: Carotid-cavernous, GKRS: Gamma knife radiosurgery

Table 7: Treatment results of dural arteriovenous fistulas after stereotactic radiosurgery

Type of results	Ratio
Complete obliteration rate	8/17 (47%)
Complete obliteration rate for patients followed up >6 months	9/17 (53%)
Partial to complete obliteration rate	15/17 (88%)
Complete symptoms resolved	16/21 (77%)
Partial to complete symptoms resolved	21/21 (100%)

the present study, the CO rate was 53%. In addition, all 21 patients showed partial to complete symptom resolution, suggesting that SRS is effective in treating dural AVFs, especially with regard to symptom control.

Borden Type II/III AVFs have cortical venous drainage and are considered to carry a higher risk of hemorrhage and inferior GKRS treatment response [6,13-15]. Similar results were observed in our study. The CO rate for Borden Type I AVFs was 66.7% and that for Borden Type II/III AVFs was 25%, a nonsignificant difference ($P = 0.153$). Moreover, it took more time for Borden Type II/III AVFs to achieve CO (25.9 months for Borden Type I and 60.4 months for Borden Type II/III, $P = 0.028$). Only one patient who initially presented with hemorrhage in our study was classified as having Borden Type II AVFs in the transverse sinus. Although CO was not optimal after GKRS for Borden Type II/III dural AVFs, this treatment was effective in symptom resolution in both groups (76.9% complete symptom resolution for Borden Type I and 75.0% for Borden Type II/III, $P = 1.000$). In contrast, we found no difference in the CO rate between the CC fistula and non-CC fistula groups (66.7% vs. 62.5%, $P = 1.000$). Similar results were presented in another study [6]. The results might indicate that indirect type CC fistulas are dural AVFs that occur in the cavernous sinus.

Surgery for dural AVFs has been proven effective [16-18]. The evolving technique of endovascular embolism has been used both in combination with surgical treatment [12,19] and alone as a less invasive option. Recently, GKRS has been used to treat dural AVFs in combination with endovascular embolization [12,20,21]. Many have reported that GKRS alone is effective in treating dural AVFs, especially for controlling symptoms,

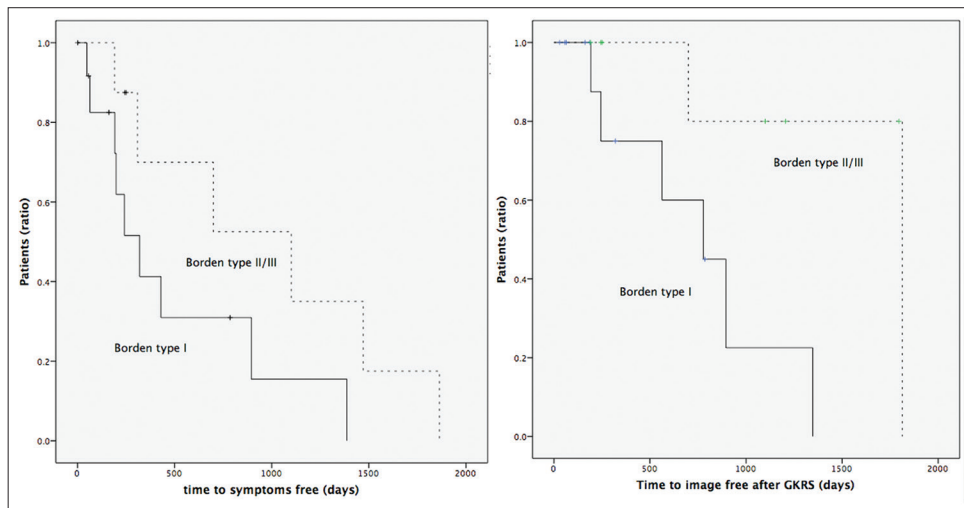


Figure 2: The left Kaplan–Meier curves showing the median treatment to symptom-free durations for Borden Type I and Borden Type II/III dural arteriovenous fistulas (10.6 vs. 36.7 months, $P = 0.103$). The right Kaplan–Meier curves showing the median treatment to image-free durations for Borden Type I and Borden Type II/III dural arteriovenous fistulas (25.9 vs. 60.4 months, $P = 0.028$)

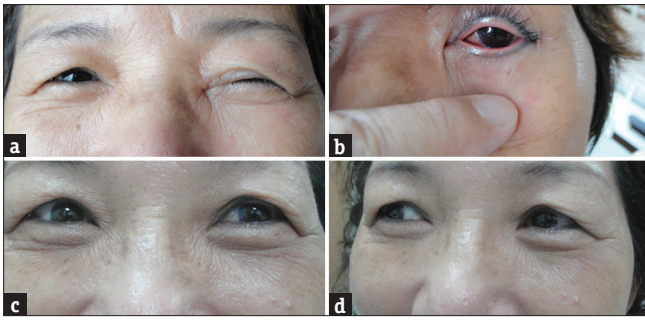


Figure 3: A 55-year-old woman with a left side indirect type carotid-cavernous fistula had chemosis and proptosis before gamma knife radiosurgery (a and b). Complete remission of the patient's symptoms and signs 2 years after gamma knife radiosurgery treatment (c and d)

and our experience showed the same results [6,9,22]. The major advantage of GKRS is that it is a relatively noninvasive procedure with a low risk of complications. However, the major concern with GKRS alone in treating dural AVFs is that it takes longer to achieve CO [12,23]. In our study, the median GKRS to image-free duration was 44.9 months and the median GKRS to symptom-free duration was 14.3 months. Many patients had significant clinical improvement in symptoms despite images that showed remaining dural AVFs. Figure 3 shows a patient who presented with chemosis and proptosis and had complete symptom relief 2 years after treatment. Figure 4 shows a patient who had Borden Type II dural AVFs in the sigmoid and sagittal sinus and achieved CO after treatment. For Borden Type II/III AVFs, which carry a higher risk of cerebral hemorrhage, endovascular embolization combined with GKRS might be a better choice in terms of immediate reduction in the rate of hemorrhage and improvement of clinical symptoms. This combined approach could also achieve long-term CO [9].

CONCLUSION

Gamma knife surgery alone for the treatment of dural AVFs is effective and safe. Dural AVFs with cortical venous drainage (Borden Type II/III) require more time to achieve a treatment response, a factor that strongly influences the CO rate. However, the rate of complete symptom relief was equally good in Borden Type I and Borden Type II/III dural AVFs.

Financial support and sponsorship

Nil.

Conflicts of interest

There are no conflicts of interest.

REFERENCES

1. Miller NR. Dural carotid-cavernous fistulas: Epidemiology, clinical presentation, and management. *Neurosurg Clin N Am* 2012;23:179-92.

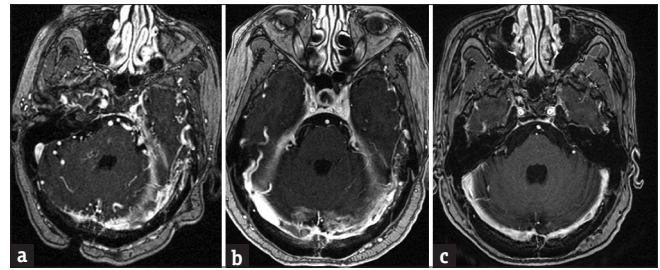


Figure 4: Contrast-enhanced magnetic resonance images from a 52-year-old woman with Borden Type II dural arteriovenous fistulas in the sigmoid and sagittal sinus. She received gamma knife radiosurgery in 2011 (a) and follow-up images showing gradual resolution of dural arteriovenous fistulas gamma knife radiosurgery 1 year (b) and 4 years (c) after treatment

2. Ellis JA, Goldstein H, Connolly ES Jr, Meyers PM. Carotid-cavernous fistulas. *Neurosurg Focus* 2012;32:E9.
3. Yang H, Kano H, Kondziolka D, Niranjan A, Flickinger JC, Horowitz MB, et al. Stereotactic radiosurgery with or without embolization for intracranial dural arteriovenous fistulas. *Prog Neurol Surg* 2010;27:195-204.
4. Borden JA, Wu JK, Shucart WA. A proposed classification for spinal and cranial dural arteriovenous fistulous malformations and implications for treatment. *J Neurosurg* 1995;82:166-79.
5. Cognard C, Gobin YP, Pierot L, Bailly AL, Houdart E, Casasco A, et al. Cerebral dural arteriovenous fistulas: Clinical and angiographic correlation with a revised classification of venous drainage. *Radiology* 1995;194:671-80.
6. Chen CJ, Lee CC, Ding D, Starke RM, Chivukula S, Yen CP, et al. Stereotactic radiosurgery for intracranial dural arteriovenous fistulas: A systematic review. *J Neurosurg* 2015;122:353-62.
7. Barrow DL, Spector RH, Braun IF, Landman JA, Tindall SC, Tindall GT. Classification and treatment of spontaneous carotid-cavernous sinus fistulas. *J Neurosurg* 1985;62:248-56.
8. Pan DH, Chung WY, Guo WY, Wu HM, Liu KD, Shiao CY, et al. Stereotactic radiosurgery for the treatment of dural arteriovenous fistulas involving the transverse-sigmoid sinus. *J Neurosurg* 2002;96:823-9.
9. Pan DH, Wu HM, Kuo YH, Chung WY, Lee CC, Guo WY. Intracranial dural arteriovenous fistulas: Natural history and rationale for treatment with stereotactic radiosurgery. *Prog Neurol Surg* 2013;27:176-94.
10. Söderman M, Edner G, Ericson K, Karlsson B, Rahn T, Ulfarsson E, et al. Gamma knife surgery for dural arteriovenous shunts: 25 years of experience. *J Neurosurg* 2006;104:867-75.
11. Oh JT, Chung SY, Lanzino G, Park KS, Kim SM, Park MS, et al. Intracranial dural arteriovenous fistulas: Clinical characteristics and management based on location and hemodynamics. *J Cerebrovasc Endovasc Neurosurg* 2012;14:192-202.
12. Friedman JA, Pollock BE, Nichols DA, Gorman DA, Foote RL, Stafford SL. Results of combined stereotactic radiosurgery and transarterial embolization for dural arteriovenous fistulas of the transverse and sigmoid sinuses. *J Neurosurg* 2001;94:886-91.
13. Söderman M, Pavic L, Edner G, Holmin S, Andersson T. Natural history of dural arteriovenous shunts. *Stroke* 2008;39:1735-9.
14. Strom RG, Botros JA, Refai D, Moran CJ, Cross DT 3rd, Chicoine MR, et al. Cranial dural arteriovenous fistulae: Asymptomatic cortical venous drainage portends less aggressive clinical course. *Neurosurgery* 2009;64:241-7.
15. Gross BA, Du R. The natural history of cerebral dural arteriovenous fistulae. *Neurosurgery* 2012;71:594-602.

16. Mabuchi S, Nakagawa Y, Abe H, Kinomoto H, Tsuru M. Surgical management of arteriovenous malformations in the posterior fossa. *No Shinkei Geka* 1983;11:883-9.
17. Malik GM, Pearce JE, Ausman JI, Mehta B. Dural arteriovenous malformations and intracranial hemorrhage. *Neurosurgery* 1984;15:332-9.
18. Sundt TM Jr., Piepgras DG. The surgical approach to arteriovenous malformations of the lateral and sigmoid dural sinuses. *J Neurosurg* 1983;59:32-9.
19. Barnwell SL, Halbach VV, Higashida RT, Hieshima G, Wilson CB. Complex dural arteriovenous fistulas. Results of combined endovascular and neurosurgical treatment in 16 patients. *J Neurosurg* 1989;71:352-8.
20. Link MJ, Coffey RJ, Nichols DA, Gorman DA. The role of radiosurgery and particulate embolization in the treatment of dural arteriovenous fistulas. *J Neurosurg* 1996;84:804-9.
21. Pan HC, Sun MH, Yang DY, Wang YC, Lee SD, Chen WH, et al. Multidisciplinary treatment of cavernous sinus dural arteriovenous fistulae with radiosurgery and embolization. *J Clin Neurosci* 2005;12:744-9.
22. Chandler HC Jr., Friedman WA. Successful radiosurgical treatment of a dural arteriovenous malformation: Case report. *Neurosurgery* 1993;33:139-41.
23. Lecavalier-Barsoum M, Roy D, Doucet R, Fortin B, Lambert C, Moundjian R, et al. Long-term results of radiosurgery for cerebral arteriovenous malformations. *Can J Neurol Sci* 2013;40:182-6.