



Original Article

A model of chlorhexidine digluconate-induced peritoneal fibrosis in rats

Ru-Ping Lee^a, Chung-Jen Lee^b, Yi-Maun Subeq^a, Bang-Gee Hsu^{c,d,*}^a Department of Nursing, Tzu Chi University, Hualien, Taiwan^b Department of Nursing, Tzu Chi College of Technology, Hualien, Taiwan^c School of Medicine, Tzu Chi University, Hualien, Taiwan^d Department of Nephrology, Buddhist Tzu Chi General Hospital, Hualien, Taiwan

ARTICLE INFO

Article history:

Received 7 May 2012

Received in revised form

28 May 2012

Accepted 27 June 2012

Keywords:

Chlorhexidine digluconate

Peritoneal fibrosis

Rat model

ABSTRACT

Objectives: Peritoneal fibrosis (PF) is a recognized complication of long term peritoneal dialysis (PD) and can lead to ultrafiltration failure. The most commonly used method to create a PF rat model is an intraperitoneal injection of 0.1% chlorhexidine gluconate with 15% ethanol. The aim of this study was to use chlorhexidine digluconate without ethanol, given via a PD catheter, to create a PF rat model.

Material and Methods: PF was induced in Sprague-Dawley rats by 0.5 mL 0.1% chlorhexidine digluconate in normal saline administered daily for 1 or 2 weeks via a PD catheter. Conventional 4.25% Dianeal dialysate solution, 30 mL, was administered via a PD catheter and the dwell time was 4 hours. Dialysate samples (0.5 mL) and blood samples (0.5 mL) were taken at 0 and 4 hours after the dialysate fluid had been infused to measure glucose and urea. At the end of dialysis, the rats were sacrificed; the parietal peritonea of the liver and anterior abdominal wall muscle were harvested. The peritoneum was analyzed by microscopic examination and immunohistochemistry for transforming growth factor- β 1 (TGF- β 1), α -smooth muscle actin (α -SMA), fibronectin, collagen, and vascular endothelial growth factor (VEGF).

Results: After 4 hours of PD, the D_4/D_0 glucose level was increased, the D_4/D_4 urea level was decreased, the liver and muscle peritoneum was markedly thicker, and expression of TGF- β 1, α -SMA, fibronectin, collagen, and VEGF-positive cells was increased in the PF groups compared with the vehicle groups, and also in the 2 week PF group compared with the 1 week PF group.

Conclusion: We developed a novel method of creating a PF rat model using chlorhexidine digluconate without ethanol via a PD catheter, which will be useful in the study of PF.

Copyright © 2012, Buddhist Compassion Relief Tzu Chi Foundation. Published by Elsevier Taiwan LLC. All rights reserved.

1. Introduction

Peritoneal fibrosis (PF) is one of the most serious complications of peritoneal dialysis (PD) [1,2]. PF is characterized by activation of the peritoneal resident cells, accumulation and deposition of excess matrix proteins within the interstitium, and neoangiogenesis and vasculopathy of the peritoneal microvasculature [3,4]. Studies have shown that the causes of these peritoneal changes include repeated episodes of infectious peritonitis, and low biocompatibility of PD solutions, particularly those which are hyperosmotic, and have a high glucose concentration, lactate content, low pH, glucose degradation products, and advanced glycation end-products [5,6]. To date, there are no randomized controlled trials to guide therapy for PF [2].

The most commonly used method to create a PF rat model is an intraperitoneal injection of 0.1% chlorhexidine gluconate with 15% ethanol [7,8]. Increased expression of transforming growth factor-beta 1 (TGF- β 1), alpha-smooth muscle actin (α -SMA), type I collagen (collagen) and vascular endothelial growth factor (VEGF) have been observed in the peritoneum of this model [9–12]. However, this technique is cumbersome and requires the use of 15% ethanol as a control. Another problem is intraperitoneal chlorhexidine gluconate administration in rats may unintentionally result in injection into the abdominal organs, which could have misleading effects on results. Previously, our studies used renin-angiotensin system inhibitors (aliskiren, valsartan, enalapril) to ameliorate chlorhexidine digluconate-induced liver PF in rats [13–15]. These papers used chlorhexidine digluconate without ethanol for 7 days and did not show the change of anterior abdominal wall muscle peritoneum histopathology [13–15]. In this study, chlorhexidine digluconate without ethanol was used for 7 or 14 days and further studied in the anterior abdominal wall muscle peritoneum histopathology. The aim of this study was to use chlorhexidine

* Corresponding author. Department of Nephrology, Buddhist Tzu Chi General Hospital, 707, Section 3, Chung-Yang Road, Hualien, Taiwan. Tel.: +886 3 8561825; fax: +886 3 8577161.

E-mail address: gee.lily@tzuchi.com.tw (B.-G. Hsu).

digluconate without ethanol given via a PD catheter, to create a PF rat model for 1 or 2 weeks, and to investigate the peritoneal function, liver and anterior abdominal wall muscle peritoneum histopathology, and TGF- β 1, α -SMA, fibronectin, collagen, and VEGF immunohistochemistry (IHC) in the liver peritoneum.

2. Material and methods

2.1. Preparation of animals and peritoneal tube insertion

Thirty-two male Sprague-Dawley rats weighing 280–300 g were purchased from the National Animal Center (Taipei, Taiwan) and housed in the university animal center in a controlled environment at a temperature of $22 \pm 1^\circ\text{C}$ with a 12 hour light/dark cycle. Food and water were given *ad libitum*. The experimental protocol was approved by the Animal Care and Use Committee of Tzu Chi University. These animals were anesthetized with halothane inhalation for about 15 minutes. During anesthesia, the fur over the abdominal wall was closely shaved. A polyethylene catheter (PE-240; PD catheter), about 30 cm long, was inserted about 4 cm into the peritoneal cavity through a midline incision below the xiphoid process. Then the catheter was tunneled subcutaneously to the right inguinal area. All procedures were carried out in sterile conditions. Sterilized stainless steel covers were used to cover the PD catheter to prevent the rats from biting and dislocating the catheters. After the operation, the animals were placed in a conscious rat metabolic cage (Mike Biological Technologies, Hualien, Taiwan). Rats awakened soon after the operation and PF was induced 24 hours later, with the rats in a conscious state [13–15].

2.2. Peritoneal fibrosis (PF)

PF was induced by 0.5 mL 0.1% chlorhexidine digluconate (Sigma-Aldrich, St. Louis, MO, USA) in normal saline administered via a PD catheter followed by 1 mL of normal saline daily [13–15].

2.3. Experimental design

The experimental rats were randomly divided into four groups. The 1 week vehicle group ($n = 8$) and 2 week vehicle group ($n = 8$) received 0.5 mL normal saline via a PD catheter followed by 1 mL of normal saline daily for 1 week and 2 weeks, respectively. The 1 week PF group ($n = 8$) and 2 week PF group ($n = 8$) received 0.5 mL 0.1% chlorhexidine digluconate in normal saline, followed by 1 mL of normal saline via the PD catheter daily for 1 week and 2 weeks, respectively.

2.4. Peritoneal dialysis

After the end of PF (7 days or 14 days later), these animals were anesthetized with ether inhalation for about 15 minutes. After anesthesia, a polyethylene catheter (PE-50) was inserted into the right femoral artery for blood sampling. The operation was completed within 15 minutes, leaving a small wound ($<0.5\text{ cm}^2$). Sterilized stainless steel covers were used to cover the femoral vein PE catheters to prevent the rats from biting and dislocating the catheters. After the operation, the animals were placed in a conscious rat metabolic cage. Rats awakened soon after the operation and peritoneal dialysis was induced 24 hours later, with the rats in a conscious state [13–15]. Rats were given conventional 4.25% glucose-containing peritoneal fluid (Dianeal; Baxter Healthcare SA, Singapore Branch, Singapore) 30 mL via the PD catheter to the rat peritoneal cavity and the dwell time was 4 hours. After 4 hours PD, the animals were sacrificed for pathology.

2.5. Blood and dialysate fluid sample analysis

Blood and dialysate fluid samples (0.5 mL) were collected for measurement of glucose and urea at 0, and 4 hours after PD. Part of the blood and dialysate fluid samples was immediately centrifuged at 3000 g for 10 minutes within 1 hour after collection for biochemical analysis. Serum and dialysate fluid levels of glucose and urea were measured with an autoanalyzer (COBAS Integra C111, Roche Diagnostics, Basel, Switzerland) to obtain various biochemical data [13–15]. The other part of the serum collected at 4 hours after PD, was stored at -80°C for later measurement of TGF- β 1 concentrations.

2.6. Serum and dialysate TGF- β 1 measurement by ELISA

At 4 hours of PD, TGF- β 1 concentrations in the blood and dialysate samples were measured separately by antibody enzyme-linked immunosorbent assay (ELISA) with commercial antibody pairs, recombinant standards, and a biotin-streptavidin-peroxidase detection system (Assay Designs, Ann Arbor, Michigan, USA) as described previously [13–15]. All reagents, samples, and working standards were brought to room temperature and prepared according to the manufacturer's directions. Reactions were quantified by optical density using an automated ELISA reader (Sunrise, Tecan Co., Grödingen, Austria) at a 450/540 nm wavelength.

2.7. Peritoneal solutes transport analysis

Peritoneal solute transport was calculated from the dialysate concentration relative to its concentration in the initial infused dialysis solution (D_4/D_0 glucose) for glucose, and the dialysate-to-plasma concentration ratio (D_4/P_4 urea) at 4 hours for urea [11,13–15].

2.8. Histological assessment

The anterior abdominal wall muscle peritoneum and liver peritoneum were fixed overnight in 4% buffered formaldehyde, processed by standard methods, and stained with hematoxylin and eosin. Both parietal and visceral peritoneal surfaces were evaluated by morphometry and IHC. Thickening of the muscle peritoneum and liver peritoneum was defined from the abdominal muscular surface or the liver surface to the peritoneal cavity. Quantification of the liver and muscle peritoneum was performed on paraffin-embedded tissue sections and was counted digitally using a 200 \times objective lens via a computer imaging analysis system (Image-Pro Plus 4.5, Media Cybernetics, Bethesda, MD, USA) as described previously [11,13–15]. Briefly, the thickness of the muscle peritoneum and liver peritoneum was measured at 10 points in each rat.

2.9. Immunohistochemistry (IHC)

For IHC of the liver peritoneum, serial 4 μm sections were deparaffinized, rehydrated, and incubated with different mouse monoclonal antibodies at 4°C overnight according to the manufacturer's directions. Antigen retrieval was used for TGF- β 1 (Abcam, Cambridge, MA, USA), fibronectin, collagen (Rockland Immunochemicals Inc., Gilbertsville, PA, USA), VEGF and α -SMA (Bio SB, Santa Barbara, CA, USA). Dilutions were 1 in 100 for all five immunohistochemical factors. After incubation, tissue sections were covered with biotinylated goat anti-mouse polyvalent secondary antibody and incubated at room temperature for 10 minutes. After washing, the slides were incubated in peroxidase conjugated streptavidin-biotin complex (Dako, Copenhagen, Denmark) for 10 minutes. The cells positive for TGF- β 1, α -SMA,

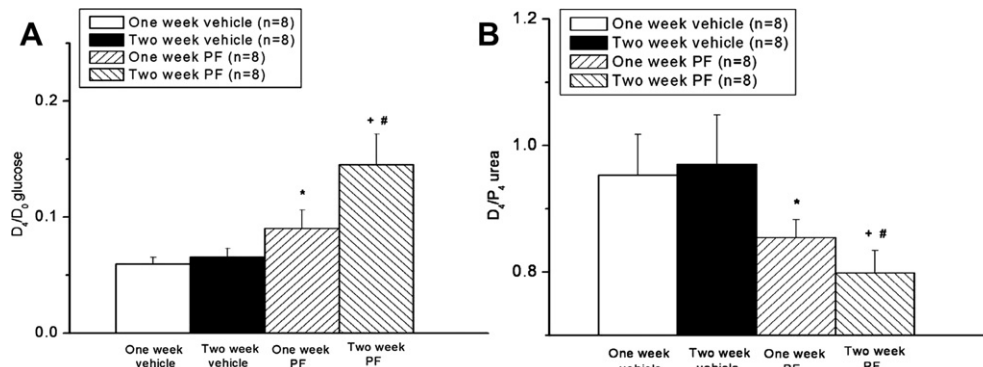


Fig. 1. The D_4/D_0 glucose level (A) and D_4/P_4 urea level (B) in chlorhexidine digluconate-induced peritoneal fibrosis (PF). * $p < 0.05$ for the 1 week PF group compared with the 1 week vehicle group. * $p < 0.05$ for the 2 week PF group compared with the 2 week vehicle group. # $p < 0.05$ for the 2 week PF group compared with the 1 week PF group.

fibronectin, collagen and VEGF from a 0.01 mm^2 area ($\times 200$ magnification field; 0.1 mm width $\times 0.1 \text{ mm}$ height) were evaluated for four fields, and were counted digitally via a computer imaging analysis system (Image-Pro Plus 4.5); results are reported as the percentage of positive cells/ mm^2 of peritoneal tissue [13–15]. All scoring was performed in a blinded manner on coded slides.

2.10. Statistical analysis

Data were expressed as mean \pm SD. Statistical comparisons between different groups at corresponding time points were made by repeated measures two-way ANOVA followed by a *post hoc* test (Bonferroni's method). Histological scores were analyzed by the Kruskal-Wallis test followed by the Mann-Whitney U test. A p value < 0.05 was considered statistically significant.

3. Results

3.1. Peritoneal function

All rats survived during the procedure for administration of 0.5 mL normal saline or 0.5 mL 0.1% chlorhexidine digluconate. The D_4/D_0 glucose level was significantly higher, and D_4/P_4 urea level was significantly lower in the 1 week PF group compared with the 1 week vehicle group (* $p < 0.05$; Fig. 1A and B) and in the 2 week PF group compared with the 2 week vehicle group (+ $p < 0.05$; Fig. 1A and B). The D_4/D_0 glucose level was significantly higher, and D_4/P_4 urea level was significantly lower in the 2 week PF group than in the 1 week PF group (# $p < 0.05$; Fig. 1A and B).

3.2. Serum and dialysate TGF- $\beta 1$ level

PF greatly elevated the serum and dialysate TGF- $\beta 1$ levels compared with the vehicle groups (Fig. 2A and B). The serum and dialysate TGF- $\beta 1$ levels in the 1 week PF group were higher than those in the 1 week vehicle group (* $p < 0.05$; Fig. 2A and B), and those in the 2 week PF group were higher than those in the 2 week vehicle group (+ $p < 0.05$; Fig. 2A and B). Moreover, the serum and dialysate TGF- $\beta 1$ levels were higher in the 2 week PF group than those in the 1 week PF group (# $p < 0.05$; Fig. 2A and B).

3.3. Histopathology of liver and muscle peritoneum

Daily administration of chlorhexidine digluconate induced thickness of the liver and muscle peritoneum (Figs. 3C, 3D, 4C, and 4D). The liver peritoneum and muscle peritoneum were thicker in the 1 week PF group than in the 1 week vehicle group (* $p < 0.05$; Figs. 3E and 4E), in the 2 week PF group than in the 2 week vehicle group (+ $p < 0.05$; Figs. 3E and 4E), and in the 2 week PF group than in the 1 week PF group (# $p < 0.05$; Figs. 3E and 4E).

3.4. IHC of liver peritoneum

The numbers of TGF- $\beta 1$ -positive, α -SMA-positive, fibronectin-positive, collagen-positive, and VEGF-positive cells in the same square area were increased in the chlorhexidine digluconate-induced PF groups compared with the vehicle groups (Fig. 5). More cells were positive for all five of these immunohistochemical factors in the 1 week PF group than in the 1 week vehicle group (* $p < 0.05$; Fig. 6A–E), in the 2 week vehicle group than in the

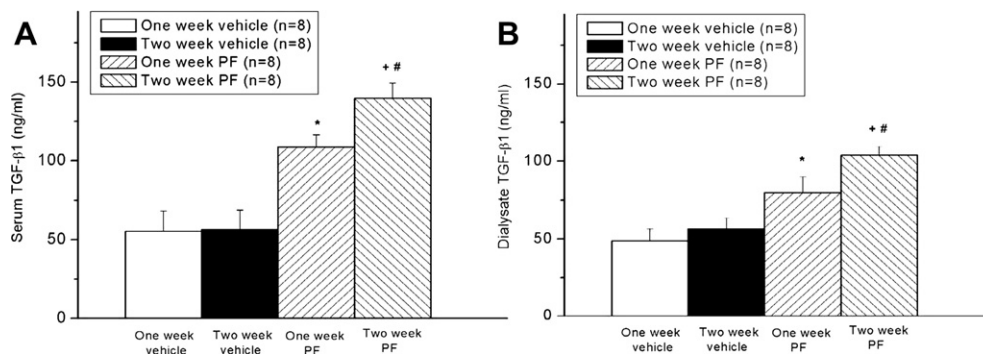


Fig. 2. Serum (A) and dialysate (B) transforming growth factor-beta 1 (TGF- $\beta 1$) levels after chlorhexidine digluconate-induced peritoneal fibrosis (PF) in rats. * $p < 0.05$ for the 1 week PF group compared with the 1 week vehicle group. * $p < 0.05$ for the 2 week PF group compared with the 2 week vehicle group. # $p < 0.05$ for the 2 week PF group compared with the 1 week PF group.

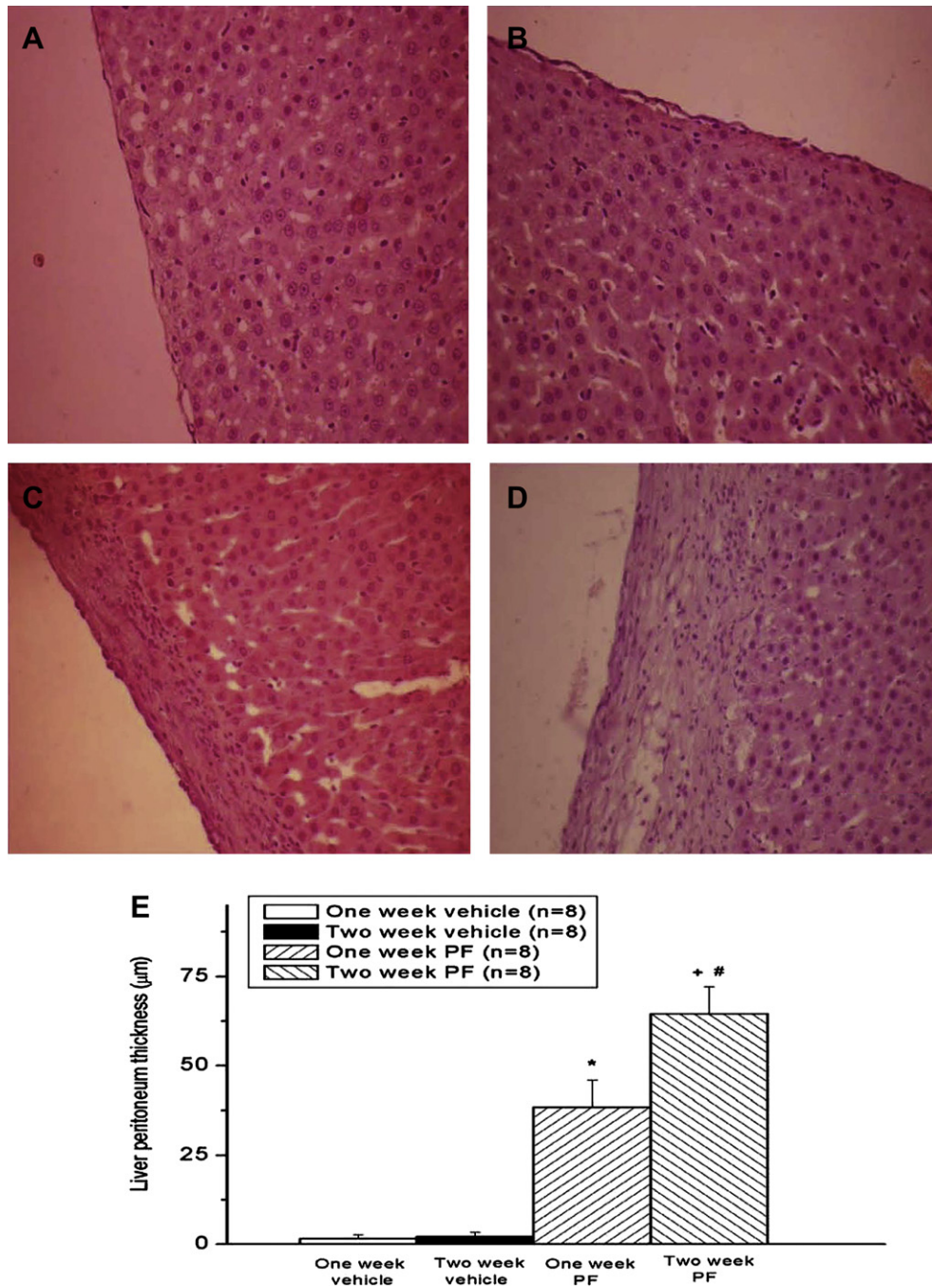


Fig. 3. Hematoxylin and eosin staining of the liver peritoneum. Histologic sections from the 1 week vehicle group (A), 2 week vehicle group (B), 1 week peritoneal fibrosis (PF) group (C), and 2 week PF group (D) (magnification $\times 200$). Thickness of the liver peritoneum after chlorhexidine digluconate-induced PF in rats (E). * $p < 0.05$ for the 1 week PF group compared with the 1 week vehicle group. # $p < 0.05$ for the 2 week PF group compared with the 2 week vehicle group. + $p < 0.05$ for the 2 week PF group compared with the 1 week PF group. Bar = 40 μm .

2 week vehicle group (+ $p < 0.05$; Fig. 6A–E), and in the 2 week PF group than in the 1 week PF group (# $p < 0.05$; Fig. 6A–E).

4. Discussion

The availability of adequate experimental models of PF is essential to the development and testing of therapeutic approaches for patients with PF. In this study, 0.5 mL 0.1% chlorhexidine digluconate without ethanol administered daily via a PD catheter resulted in significantly thicker liver and muscle peritoneum, and

significantly increased expression of TGF- $\beta 1$, α -SMA, fibronectin, collagen, and VEGF-positive cells compared with vehicle administration. Moreover, the 2 week PF group had more severe PF than the 1 week PF group.

PF is one of the most serious complications of long-term PD [8]. Studies of PF in rats have focused on chronic exposure to chlorhexidine gluconate, acid glucose solution, and povidone iodine, and have demonstrated chemical irritation, sterile peritonitis, and chronic inflammation [1,8]. The most commonly used method to create the PF rat model is intraperitoneal injection of 0.1%

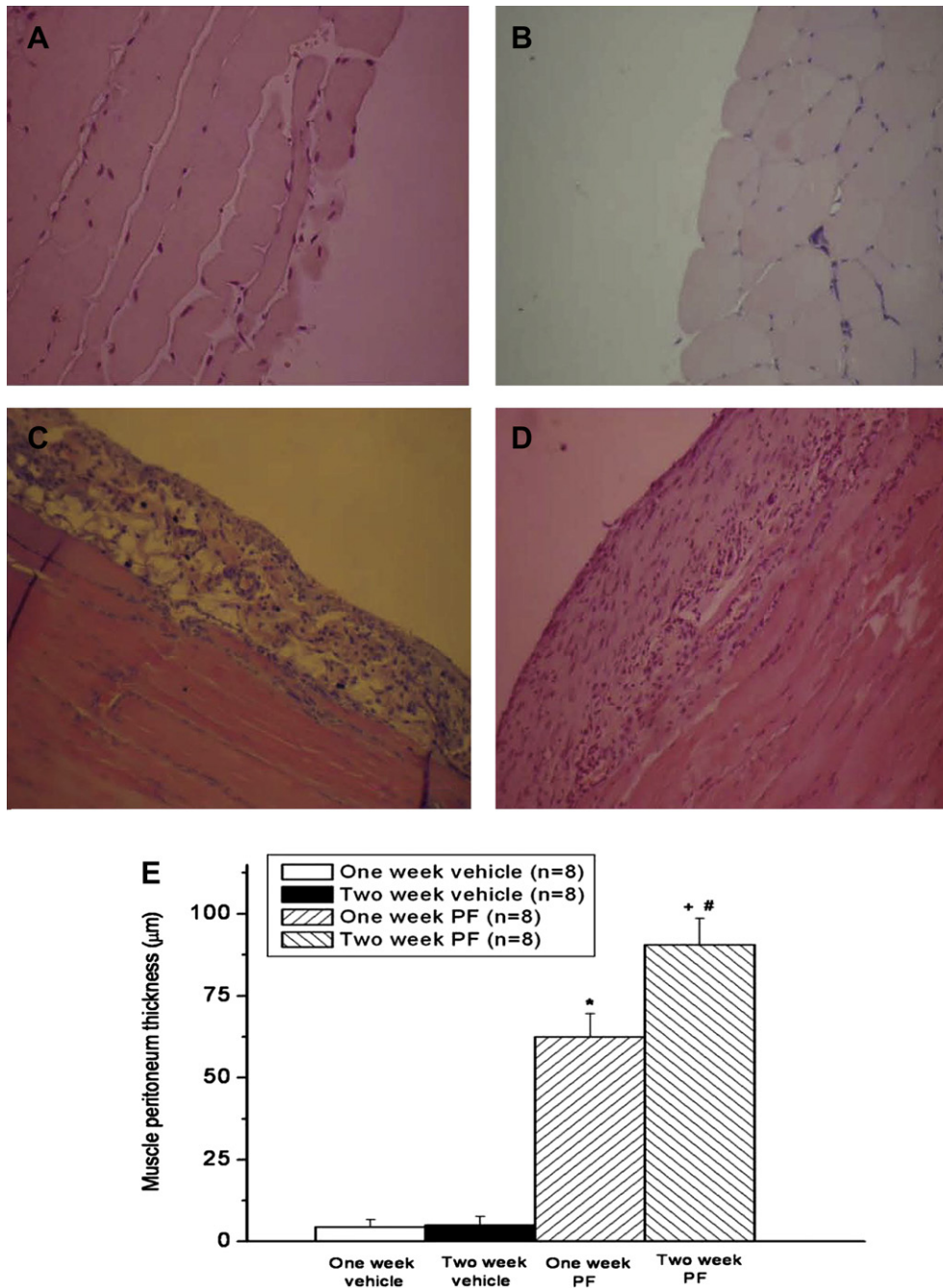


Fig. 4. Hematoxylin and eosin staining of the muscle peritoneum. Histologic sections from the 1 week vehicle group (A), 2 week vehicle group (B), 1 week peritoneal fibrosis (PF) group (C), and 2 week PF group (D) (magnification $\times 200$). Thickness of the muscle peritoneum after chlorhexidine digluconate-induced PF in rats (E). * $p < 0.05$ for the 1 week PF group compared with the 1 week vehicle group. # $p < 0.05$ for the 2 week PF group compared with the 2 week vehicle group. + $p < 0.05$ for the 2 week PF group compared with the 1 week PF group. Bar = 40 μm .

chlorhexidine gluconate with 15% ethanol three times a week or daily injections for 3 weeks [7,8,16,17]. Acetaldehyde, the first metabolite of ethanol, can affect collagen I production by upregulating the synthesis of TGF- $\beta 1$ [18]. Acetaldehyde also induces rat hepatic stellate cells to increase α -SMA and TGF- $\beta 1$ production [19]. Ethanol elevates the activities of VEGF and TGF- $\beta 1$ [20]. Our model is different, because chlorhexidine digluconate was used as a chemical irritant to induce PF and ethanol was not used as a control solution, which avoids the effects of ethanol on the synthesis of TGF- $\beta 1$. A PD catheter was used instead of intraperitoneal injections, to avoid administration into the abdominal

organs. Another advantage of our PF model is that chlorhexidine digluconate was administered for only 7 days and it could still induce significant PF in rats.

In long-term PD, morphological and functional changes in the peritoneal membrane are common. Submesothelial fibrosis, angiogenesis, vasculopathy, and collagen deposition are typical histomorphological alterations in the peritoneal membrane [3,6,21]. Major pathways of PF are most likely related to TGF- β and VEGF, which can stimulate transformation of mesothelial cells to myofibroblasts and initiate PF [1,8]. Repeated injuries to the peritoneum from chemical irritants lead to denudation of

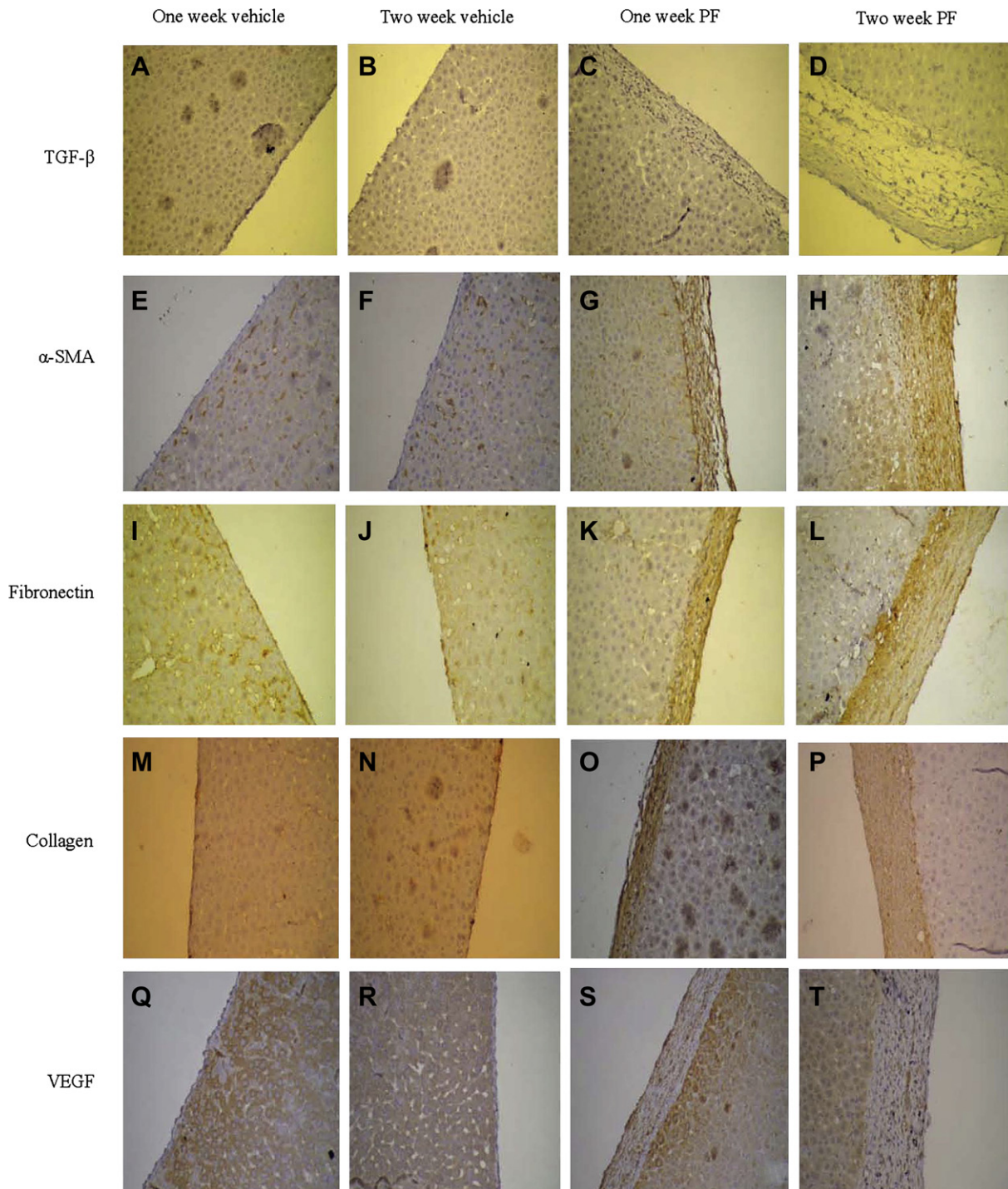


Fig. 5. Immunohistochemical staining for (TGF- β 1; A, B, C, D), alpha-smooth muscle actin (α -SMA; E, F, G, H), fibronectin (I, J, K, L), collagen (M, N, O, P), and vascular endothelial growth factor (VEGF; Q, R, S, T) in the liver peritoneum. Histological sections from the 1 week vehicle group (A, E, I, M, Q), 2 week vehicle group (B, F, J, N, R), 1 week peritoneal fibrosis (PF) group (C, G, K, O, S), and 2 week PF group (D, H, L, P, T) (magnification \times 200) after chlorhexidine digluconate-induced peritoneal fibrosis in rats.

mesothelial cells and inflammation by recruitment of macrophages and mononuclear cells and promotion of epithelial-to-mesenchymal transition, which provides more activated fibroblasts, progressing later to collagen deposition and fibrosis [2,8,22]. Our study noted the increased thickening of the liver and muscle peritoneum, and increased expression of TGF- β 1, α -SMA, fibronectin, collagen, and VEGF-positive cells in the PF

group. Moreover, the 2 week PF group had more severe PF than the 1 week PF group.

The peritoneal function test is a semiquantitative assessment of the transport capacity of the peritoneal membrane determined by the speed of equilibration of the concentrations of a solute between the plasma and the dialysis solution [23]. The concentration ratio between dialysate and plasma (D/P) of a given solute,

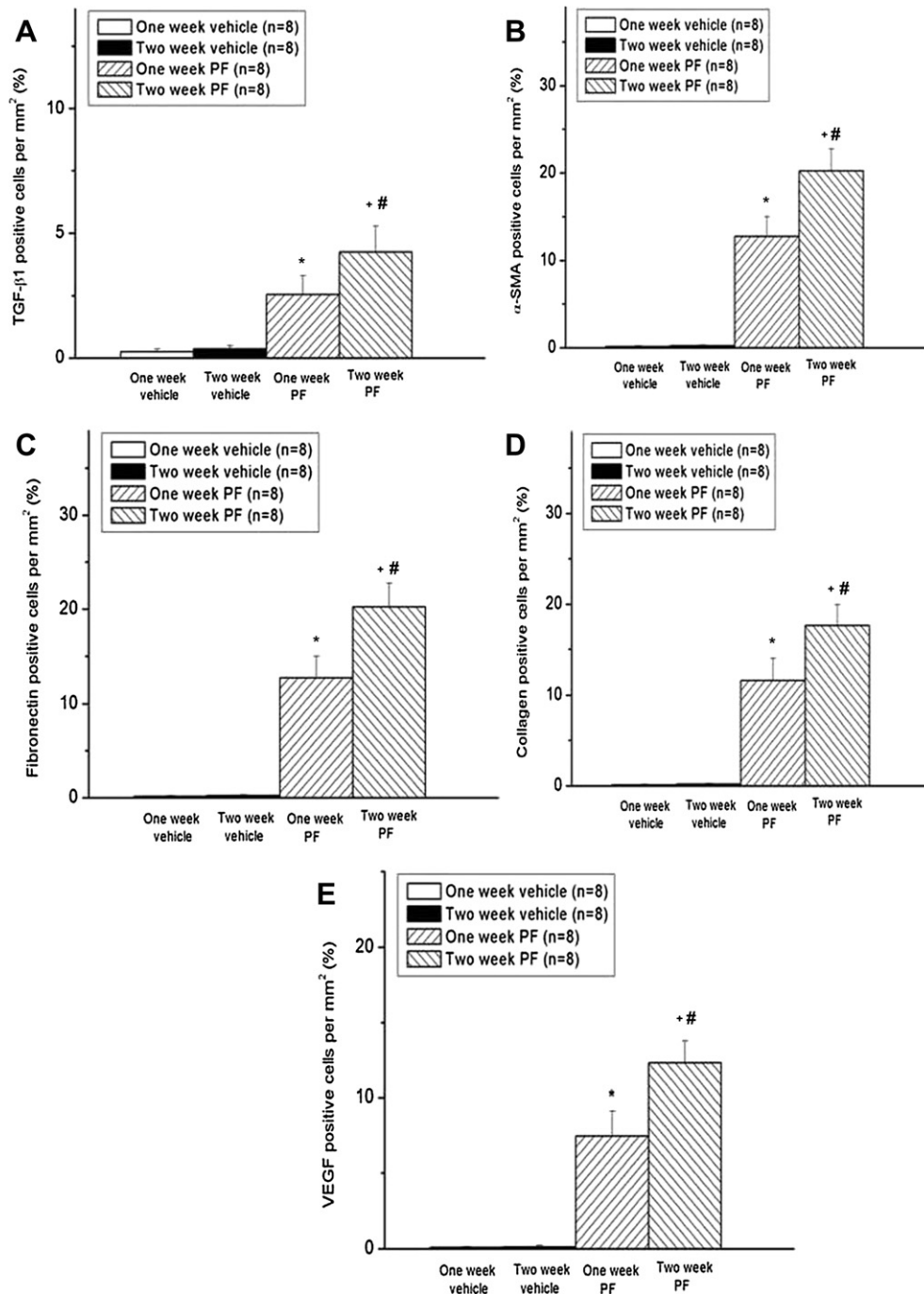


Fig. 6. The percentages of transforming growth factor-beta 1 (TGF- β 1)-positive cells: (A) alpha-smooth muscle actin (α -SMA)-positive cells; (B) fibronectin-positive cells (C) collagen-positive cells (D), and vascular endothelial growth factor (VEGF)-positive cells score (E) in the liver peritoneum after chlorhexidine digluconate-induced (PF) in rats. * $p < 0.05$ for the 1 week PF group compared with the 1 week vehicle group. # $p < 0.05$ for the 2 week PF group compared with the 2 week vehicle group. * $p < 0.05$ for the 2 week PF group compared with the 1 week PF group.

after a specified time, indicates the speed of equilibration between the concentrations. A high solute D/P means that the balance between dialysate and plasma is reached quickly, and therefore the peritoneal permeability for the solute is high. In our study, the D_4/P_4 urea level was significantly lower in the 1 week PF group than in the 1 week vehicle group, and in the 2 week PF group than in the 2 week vehicle group. Moreover, the D_4/P_4 urea level was significantly lower in the 2 week PF group than in the 1 week PF group. This means that PF-induced plasma urea could not transport to the

dialysate and the peritoneal permeability for the urea was low. The ratio between the concentration of glucose in the dialysate after a certain time (t) and the concentration of glucose in the dialysate at the beginning of the test (D_t/D_0) is also used [23]. In our study, the D_4/D_0 glucose level was significantly higher in the 1 week PF group than in the 1 week vehicle group, in the 2 week PF group than in the 2 week vehicle group, and in the 2 week PF group than in the 1 week PF group. This means that PF-induced dialysate glucose could not penetrate to the plasma and the peritoneal permeability

for the glucose was low. So, in this model, peritoneal solute transport was impaired by PF induced by chlorhexidine digluconate without ethanol.

The advantages of our PF model are the use of a PD catheter to administer a chemical irritant, no use of ethanol as a control solution, and daily administration of chlorhexidine digluconate for 7 days to induce significant PF. In the conscious rat model in our previous studies, a PD catheter was inserted to peritoneal cavity and a PE-50 catheter was inserted into the femoral artery for blood samples, and to record the arterial pressure and heart rate and another PE-50 catheter was inserted into the femoral vein for intravenous administration of drugs or fluid [13–15]. Our model can further study a drug's effects on PF and allow blood data and hemodynamic changes to be monitored over a time course without anesthesia.

Acknowledgments

This work was supported by a grant from Buddhist Tzu Chi General Hospital (TCRD 98-02) in Hualien, Taiwan.

References

- [1] Schmidt DW, Flessner MF. Pathogenesis and treatment of encapsulating peritoneal sclerosis: basic and translational research. *Perit Dial Int* 2008;28(Suppl. 5):S10–5.
- [2] Augustine T, Brown PW, Davies SD, Summers AM, Wilkie ME. Encapsulating peritoneal sclerosis: clinical significance and implications. *Nephron Clin Pract* 2009;111:c149–54.
- [3] Fusshoeller A. Histomorphological and functional changes of the peritoneal membrane during long-term peritoneal dialysis. *Pediatr Nephrol* 2008;23:19–25.
- [4] Di Paolo N, Nicolai GA, Garosi G. The peritoneum: from histological studies to mesothelial transplant through animal experimentation. *Perit Dial Int* 2008;28(Suppl. 5):S5–9.
- [5] Ito T, Yorioka N. Peritoneal damage by peritoneal dialysis solutions. *Clin Exp Nephrol* 2008;12:243–9.
- [6] Goffin E. Peritoneal membrane structural and functional changes during peritoneal dialysis. *Semin Dial* 2008;21:258–65.
- [7] Suga H, Teraoka S, Ota K, Komemushi S, Furutani S, Yamauchi S, et al. Preventive effect of pirfenidone against experimental sclerosing peritonitis in rats. *Exp Toxicol Pathol* 1995;47:287–91.
- [8] Park SH, Kim YL, Lindholm B. Experimental encapsulating peritoneal sclerosis models: pathogenesis and treatment. *Perit Dial Int* 2008;28(Suppl. 5):S21–8.
- [9] Nishino T, Miyazaki M, Abe K, Furusu A, Mishima Y, Harada T, et al. Antisense oligonucleotides against collagen-binding stress protein HSP47 suppress peritoneal fibrosis in rats. *Kidney Int* 2003;64:887–96.
- [10] Io H, Hamada C, Ro Y, Ito Y, Hirahara I, Tomino Y. Morphologic changes of peritoneum and expression of VEGF in encapsulated peritoneal sclerosis rat models. *Kidney Int* 2004;65:1927–36.
- [11] Ro Y, Hamada C, Inaba M, Io H, Kaneko K, Tomino Y. Inhibitory effects of matrix metalloproteinase inhibitor ONO-4817 on morphological alterations in chlorhexidine gluconate-induced peritoneal sclerosis rats. *Nephrol Dial Transplant* 2007;22:2838–48.
- [12] Saito H, Kitamoto M, Kato K, Liu N, Kitamura H, Uemura K, et al. Tissue factor and factor v involvement in rat peritoneal fibrosis. *Perit Dial Int* 2009;29:340–51.
- [13] Ke CY, Lee CC, Lee CJ, Subeq YM, Lee RP, Hsu BG. Aliskiren ameliorates chlorhexidine digluconate-induced peritoneal fibrosis in rats. *Eur J Clin Invest* 2010;40:301–9.
- [14] Subeq YM, Ke CY, Lin NT, Lee CJ, Chiu YH, Hsu BG. Valsartan decreases TGF- β 1 production and protects against chlorhexidine digluconate-induced liver peritoneal fibrosis in rats. *Cytokine* 2011;53:223–30.
- [15] Lee CJ, Subeq YM, Lee RP, Ke CY, Lin NT, Hsu BG. Beneficial effects of enalapril on chlorhexidine digluconate-induced liver peritoneal fibrosis in rats. *Chin J Physiol* 2011;54:225–34.
- [16] Ceri M, Unverdi S, Dogan M, Unverdi H, Karaca G, Kocak G, et al. Effect of sirolimus on the regression of peritoneal sclerosis in an experimental rat model. *Int Urol Nephrol* 2012;44:977–82.
- [17] Koçak G, Azak A, Astarçı HM, Huddam B, Karaca G, Ceri M, et al. Effects of renin-angiotensin-aldosterone system blockade on chlorhexidine gluconate-induced sclerosing encapsulated peritonitis in rats. *Ther Apher Dial* 2012;16:75–80.
- [18] Purohit V, Brenner DA. Mechanisms of alcohol-induced hepatic fibrosis: a summary of the Ron Thurman Symposium. *Hepatology* 2006;43:872–8.
- [19] Szuster-Ciesielska A, Plewka K, Kandfer-Szerszeń M. Betulin, betulinic acid and butein are inhibitors of acetaldehyde-induced activation of liver stellate cells. *Pharmacol Rep* 2011;63:1109–23.
- [20] Das SK, Mukherjee S. Biochemical and immunological basis of silymarin effect, a milk thistle (*Silybum marianum*) against ethanol-induced oxidative damage. *Toxicol Mech Methods* 2012;22:409–13.
- [21] Komatsu H, Uchiyama K, Tsuchida M, Itoyama N, Matsumura M, Hara T, et al. Development of a peritoneal sclerosis rat model using a continuous-infusion pump. *Perit Dial Int* 2008;28:641–7.
- [22] Summers AM, Hoff CM, Topley N. How can genetic advances impact on experimental models of encapsulating peritoneal sclerosis? *Perit Dial Int* 2008;28(Suppl. 5):S16–20.
- [23] La Milia V. Peritoneal transport testing. *J Nephrol* 2010;23:633–47.