



Case Report

Cystic Lung Changes in a Patient With Pulmonary Tuberculosis

Kun-Eng Lim^{1}, Yav-Kuang Wu², Shiu-Feng Huang³, Yuan-Yu Hsu¹, Cheng-Yi Chan¹, Yueh-Hua Tsai¹, Hsu-Chao Chang¹, Hsiu-Wen Kuo¹*

¹Department of Medical Imaging, Buddhist Tzu Chi General Hospital, Taipei Branch, Taipei, Taiwan

²Department of Pulmonary Medicine, Buddhist Tzu Chi General Hospital, Taipei Branch, Taipei, Taiwan

³Department of Pathology, Buddhist Tzu Chi General Hospital, Taipei Branch, Taipei, Taiwan

Article info

Article history:

Received: May 11, 2009

Revised: June 22, 2009

Accepted: April 6, 2010

Keywords:

Computed tomography

Cystic lesions

Lung

Tuberculosis

Abstract

A 32-year-old male had complained of a dry cough on and off for 1 year. Chest radiography revealed reticular infiltration of bilateral lungs. Chest computed tomography showed multiple thin-walled cystic lesions of bilateral lungs with a scattered tree-in-bud appearance. Histological diagnosis obtained via a video-assisted thoracoscopic lung biopsy indicated pulmonary tuberculosis. The cystic lesions regressed after antituberculous chemotherapy. Active pulmonary tuberculosis presenting as multiple cystic lung lesions on computed tomography is very rare. Here, we report the computed tomographic findings for this patient and review the literature. (*Tzu Chi Med J* 2010;22(2):111–114)

*Corresponding author. Department of Medical Imaging, Buddhist Tzu Chi General Hospital, Taipei Branch, 289, Jianguo Road, Jindian, Taipei, Taiwan.
E-mail address: kevinblueski@yahoo.com.tw

1. Introduction

Pulmonary tuberculosis (PTB) is a common worldwide lung infection. There is a wide range of usual and unusual computed tomographic (CT) findings associated with active PTB. Approximately 8% of PTB cases were found to be associated with unusual radiographic findings in one report (1), but several other published articles suggest that unusual PTB radiographic findings may be seen in up to one-third of cases of adult-onset PTB (2–5). Unusual CT findings include single or multiple nodules or masses, miliary nodules with diffuse bilateral ground-glass opacity, and reversible lung cysts. However, active PTB presenting as multiple cystic lung lesions on CT is very rare (6–9). Recently, we found an

adult-onset patient with active PTB who presented with multiple cystic lung lesions on CT. We report this rare CT finding and review the literature.

2. Case report

A 32-year-old immunocompetent man had complained of dry cough on and off for more than 1 year. He had smoked two packs of cigarettes per day for more than 10 years. His physical examination was unremarkable. Routine blood biochemistry and urine tests were normal. The results of a sputum smear and culture were negative for acid-fast bacilli. Cytological examination of the sputum revealed no malignant cells.

Chest radiography showed reticular infiltration of bilateral lungs (Fig. 1). After symptomatic treatment with medication for 1 week, the patient's condition had not improved. Chest CT was performed and showed irregular and thin-walled cystic lesions in both lungs with a scattered tree-in-bud appearance. Moreover, there was a poorly defined cluster of nodules in the superior segment of the left lower lobe (Fig. 2). Test for human immunodeficiency virus was negative. The results of autoimmune tests (rheumatoid factor, anti-nuclear antibodies including anti-double stranded DNA, anti-neutrophil cytoplasmic antibodies (ANCA) including c-ANCA and p-ANCA and anti-extractable nuclear antibodies) were all negative.

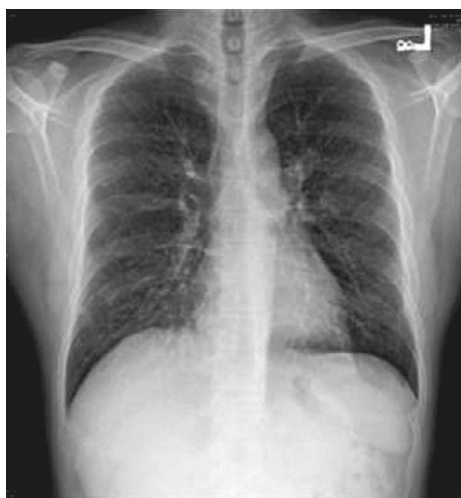

Fig. 1 — Chest radiograph shows reticular infiltration of bilateral lungs.

Under the impression of an unusual infection, possibly tuberculosis, a fiberoptic bronchoscopic examination was performed and showed chronic inflammatory changes to bilateral endobronchial mucosa. The patient's bronchoalveolar lavage fluid was unremarkable. No definite diagnosis could be made at this point based on all the aforementioned tests; therefore, video-assisted thoracoscopic lung biopsy was performed to provide a histopathological diagnosis. The biopsy specimen was obtained from a lesion in the superior segment of the left lower lobe. During surgery, an indurated nodule about 2 cm in diameter was found; the overlying pleural surface was uneven and had multiple shallow sulci. These findings suggested early fibrotic change.

Microscopic examination of the sample demonstrated abundant caseous-like necrosis surrounded by granulomatous inflammation, which was scattered across the lung parenchyma (Fig. 3). The nodular lesion had larger granuloma and abundant necrosis, while the smaller lesions showed less necrosis but had active granulomatous inflammation including many Langhans giant cells and scattered stellate-shaped scarring fibrosis. These findings suggested a diagnosis of active tuberculosis with chronic caseating granulomatous inflammation.

Antituberculous chemotherapy (Rifater five tablets per day and ethambutol three tablets per day for 3 months, which was then changed to isoniazid (100 mg/tab) two tablets per day, rifampicin (300 mg/tab) two tablets per day and ethambutol (400 mg/tab) three tablets per day for 4 months) was given. Follow-up CT performed 28 weeks after the chemotherapy showed regression of the cystic lesions in the lungs (Fig. 4). Serial follow-up chest radiographs showed regression

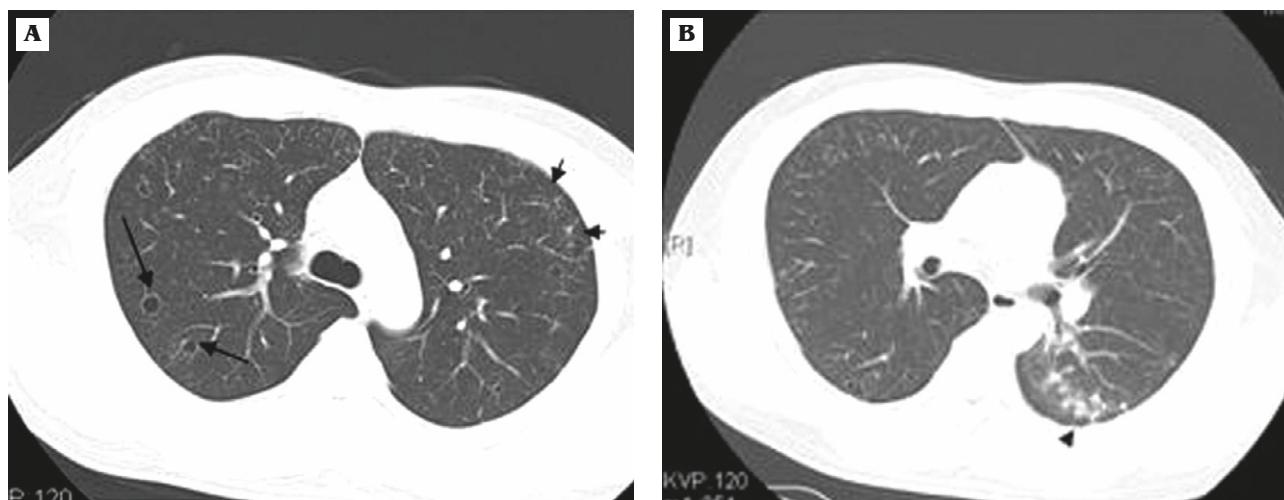


Fig. 2 — Thin-section (1.25-mm thick) computed tomography scans obtained at the level of the aortic arch and of the carina show (A) thin-walled cystic lesions (long arrows) in both lungs with a scattered tree-in-bud appearance (short arrows) together with a (B) cluster of poorly defined nodules (arrowhead) in the superior segment of the left lower lobe.

of the reticular infiltration. The patient recovered gradually, but antituberculous chemotherapy was still continuing at the time of this report.

3. Discussion

PTB is a common lung infection worldwide and causes significant morbidity and mortality, especially in developing countries. Early diagnosis and treatment of PTB patients are important in order to reduce the morbidity and mortality associated with the illness.

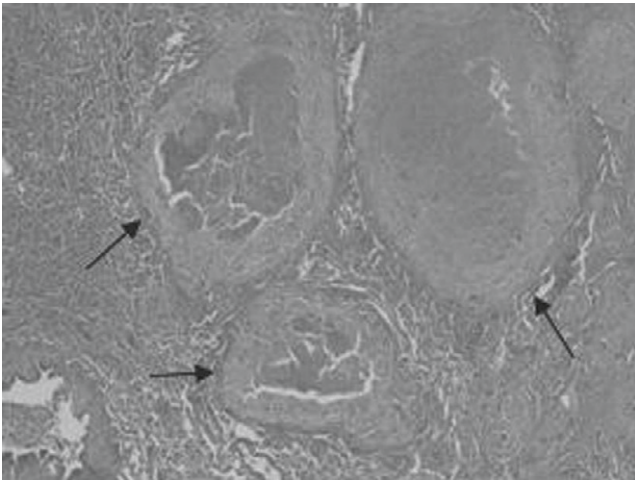


Fig. 3 — Histopathological examination of the lung tissue reveals multiple large granulomas with abundant central caseous necrosis surrounded by granulomatous inflammation (arrows). The adjacent lung tissue reveals mild interstitial chronic inflammation (hematoxylin & eosin, 40 \times).

Although routine chest radiography is usually the initial screening method when there is suspicion of PTB, CT is a more accurate diagnostic tool when the chest radiographs are normal or inconclusive and also provides valuable information about the extent and distribution of the disease. There is a wide range of usual and unusual CT findings for PTB. Unusual CT findings for PTB frequently occur in certain groups of patients, such as those with autoimmune deficiency syndrome, the elderly, alcoholics, patients who are immunocompromised, those who are malnourished or those who have diabetes mellitus.

To our knowledge, there are only a few reports of CT findings for PTB that describe patients who have presented with multiple cystic lung lesions (6–9). Ko et al reported three immunocompetent women with PTB who presented with acute respiratory failure and showed diffuse bilateral pulmonary opacity on initial chest radiography and CT, as well as the presence of multiple cystic lung lesions on follow-up CT; these disappeared almost completely after antituberculous chemotherapy (6). The initial chest radiograph and CT scan in our case were somewhat different from those reported by Ko et al (6). In their study, chest radiography showed diffuse bilateral areas of consolidation in both lungs in all three cases, whereas there was only reticular infiltration of bilateral lungs on the chest radiograph in our case. In Ko et al's cases, the initial CT showed bilateral areas of consolidation and/or ground-glass attenuation with poorly defined micronodules, whereas no areas of consolidation or ground-glass attenuation were present in our case. In Ko et al's cases, follow-up CT showed that the cystic lesions were predominantly in the upper and middle lung zones, whereas the cystic lesions were randomly distributed throughout the bilateral lungs in our case. In addition to

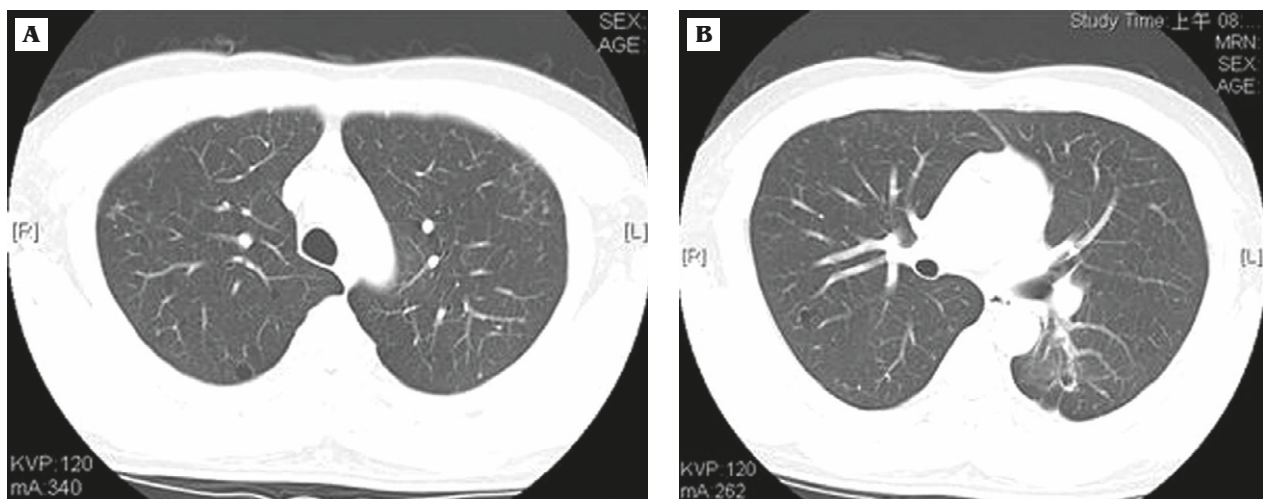


Fig. 4 — Computed tomography scans (at levels similar to Fig. 2) obtained 8 months after the start of antituberculous chemotherapy show regression of the thin-walled cystic lesions in both lungs.

this report, there have been reported cases of cystic lesions that have occurred after isoniazid treatment (7,8). However, in our case, the cystic lesions appeared before treatment rather than during or after treatment. Blosset reported cystic lung lesions (which resembled subpleural paraseptal emphysema) in children with PTB (10), which is different from the cystic lesions in our case and other reported cases (6–9).

Three pathological mechanisms can be suggested to explain the formation of cystic lung lesions (6). First, the formation of cystic lesions (subpleural emphysema) in a few studies of PTB has been suggested to be caused by interstitial air leakage with tubercle rupture and caseation necrosis (10,11). Second, the cystic lesions might represent areas of dilated bronchioles in a similar way to the cystic lesions in Langerhans cell histiocytosis. Chronic granulomatous inflammation in PTB is usually present in the bronchiolar walls and is associated with intraluminal caseous material. These granulomatous lesions in the bronchiolar walls may induce peribronchiolar fibrosis, which would result in cyst formation. Third, cystic lesions may be formed due to poor drainage of necrotic lung parenchyma in areas of consolidation, which are always coupled with bronchiolar obstruction caused by edematous luminal narrowing and mural inflammation of the involved bronchiole.

Multiple cystic lesions are commonly encountered in various cystic lung diseases, especially emphysema, cystic bronchiectasis, desquamative interstitial pneumonia, lymphocytic interstitial pneumonia, usual interstitial pneumonia, lymphangioleiomyomatosis, Langerhans cell histiocytosis, *Pneumocystis carinii* pneumonia, and septic pulmonary emboli (12,13). Therefore, PTB with cystic lung lesions needs to be differentiated from the aforementioned lung diseases. In a proper clinical setting, PTB with cystic lung lesions associated with other unusual CT findings, such as centrilobular nodules and linear branching opacities, may help distinguish PTB from other cystic lung diseases. The aforementioned lung diseases have certain characteristic CT findings that also help to distinguish them from PTB with multiple cystic lung lesions. For example, high-resolution CT findings in patients with lymphangioleiomyomatosis show multiple thin-walled cysts distributed diffusely through the lungs with normal lung parenchyma intervening and no sparing of any particular lung zones. Another example is Langerhans cell histiocytosis, which presents with

diffuse irregular and complex cystic airspaces with intervening nodules and reticular densities on high-resolution CT.

In summary, a case of active PTB appearing as multiple cystic lung lesions together with centrilobular nodules and branching opacities on CT was reported here. Cystic lung lesions are a rare manifestation of PTB, and when this type of imaging finding is found on CT, PTB should be considered as part of the differential diagnosis, especially in epidemic tuberculosis regions.

References

1. Hadlock HP, Park SK, Awe RJ, Rivera M. Unusual radiographic findings in adult pulmonary tuberculosis. *AJR Am J Roentgenol* 1980;134:1015–8.
2. Miller WT, Macgregor RR. Tuberculosis: frequency of unusual radiographic findings. *AJR Am J Roentgenol* 1978;130:867–75.
3. Lee KS, Song KS, Lim TH, Kim Y II, Kim PN, Lee BH. Adult-onset pulmonary tuberculosis: findings on chest radiographs and CT scans. *AJR Am J Roentgenol* 1993;160:753–8.
4. Palmar PES. Pulmonary tuberculosis: usual and unusual radiographic presentations. *Semin Roentgenol* 1979;14:204–43.
5. Lee JY, Lee KS, Jung KJ, et al. Pulmonary tuberculosis: CT and pathologic correlation. *J Comput Assist Tomogr* 2000;24:691–8.
6. Ko KS, Lee KS, Kim Y, Kim SJ, Kwon OJ, Kim JS. Reversible cystic disease associated with pulmonary tuberculosis: radiologic findings. *Radiology* 1997;204:165–9.
7. Singh HK, Mital OP. The radiological appearance of isoniazid cysts. *Indian J Chest Dis Allied Sci* 1968;10:208–10.
8. Fernandez A, Shah MD, Buhariwalla RJ. Multiple isoniazid cysts in a child with chronic pulmonary tuberculosis. *Indian Pediatr* 1972;9:49–50.
9. Takemura T, Aklyama O, Yanagawa T, Ikushima S, Ando T, Oritsu M. Pulmonary tuberculosis with unusual cystic change in an immunocompromised host. *Pathol Int* 2000;50:672–7.
10. Blosset CF. Subpleural emphysema complicating staphylococcal and other pneumonias. *J Pediatr* 1972;81:259–66.
11. Amitar I, Molge P, Godfrey S, Aviad I. Pneumatocele in infants and children. *Clin Pediatr* 1983;22:420–2.
12. Koyama M, Johkoh T, Honda O, et al. Chronic cystic lung disease: diagnostic accuracy of high-resolution CT in 92 patients. *AJR Am J Roentgenol* 2003;180:827–35.
13. Lee KH, Lee JS, Lynch DA, Song KS, Lim TH. The radiologic differential diagnosis of diffuse lung diseases characterized by multiple cysts or cavities. *J Comput Assist Tomogr* 2002;26:5–12.