



## Case Report

## Malakoplakia of Ipsilateral Kidney, Ureter and Bladder

Yung-Chih Chen, Hann-Chorng Kuo\*

Department of Urology, Buddhist Tzu Chi General Hospital and Tzu Chi University, Hualien, Taiwan

### Article info

#### Article history:

Received: April 17, 2009

Revised: April 21, 2009

Accepted: May 5, 2009

#### Keywords:

Malakoplakia

Michaelis-Gutmann bodies

Nephrectomy

### Abstract

Malakoplakia is a rare chronic inflammatory disease of the urinary tract, usually caused by *Escherichia coli* infection. We report a 75-year-old woman who presented with hydronephrosis and pyuria associated with *E. coli* infection. Abdominal computed tomography revealed several renal stones and severe hydronephrosis of the right kidney. Biopsies of the urinary bladder and ureter revealed erosion and acute inflammation. According to a culture sensitivity test, antimicrobial treatment was prescribed with cephadrine 500mg every 6 hours and amoxicillin-clavulanic acid 100mg twice daily for 1 month. Because of the advanced hydronephrosis with impaired renal function, a right nephroureterectomy was performed. Malakoplakia of the right kidney, ureter and urinary bladder was confirmed by pathology with Michaelis-Gutmann bodies present in the surgical specimen. The patient tolerated the operation well. She regained a good health status and was regularly followed-up in the urologic department. (*Tzu Chi Med J* 2010;22(2):103–105)

\*Corresponding author. Department of Urology, Buddhist Tzu Chi General Hospital, 707, Section 3, Chung-Yang Road, Hualien, Taiwan.  
E-mail address: hck@tzuchi.com.tw

## 1. Introduction

Malakoplakia is a rare chronic inflammatory process in the urinary tract, usually caused by *Escherichia coli* infection. Michaelis and Gutmann first described it in 1902 (1). Malakoplakia usually affects the urinary tract, commonly the bladder (40%), renal parenchyma (16%) and rarely the ureter (11%) (2). However, the clinical diagnosis of urinary tract malakoplakia is very difficult. It is usually proved by a well-trained pathologist who identifies macrophages containing intracellular concentrically laminated calcified inclusions termed Michaelis-Gutmann bodies after nephrectomy. There have been no case reports of malakoplakia

involving the ipsilateral kidney, ureter and bladder in Taiwan.

We present a 75-year-old woman who had malakoplakia diagnosed after nephrectomy. To the best of our knowledge, this is the first reported case of malakoplakia involving the bladder and unilateral kidney and ureter in Taiwan.

## 2. Case report

A 75-year-old retired female farmer presented with general malaise, non-localized abdominal pain, poor appetite and body weight loss of 10kg over 2 months.

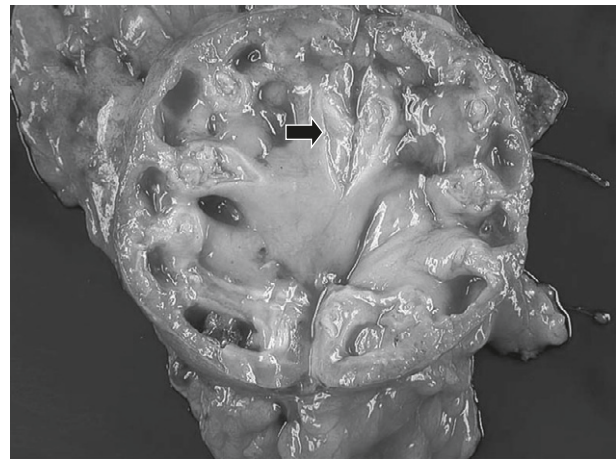
Turbid urine had been noted for 3 months. There was no fever or chills during this period. She had no history of diabetes mellitus, hypertension, recurrent urinary tract infection or significant trauma.

On examination, she appeared to be rather weak. Body temperature was 36.5°C, blood pressure was 130/82 mmHg, pulse rate was 70 beats per minute, and respiratory rate was 17 breaths per minute. Mild right costovertebral angle knocking pain was noted without any other remarkable findings. Abnormal laboratory tests included hemoglobin 10.1 g/dL, albumin 2.7 g/dL, globulin 5.3 g/dL, blood urea nitrogen 26 mg/dL, creatinine 1.7 mg/dL, fasting blood glucose 139 mg/dL and sodium 123 mmol/L. Urinalysis revealed pyuria (numerous white blood cells per high-powered field (HPF)) and microscopic hematuria (numerous red blood cells/HPF). Urine culture grew *E. coli* which was resistant to ampicillin, gentamicin and sulfamethoxazole.

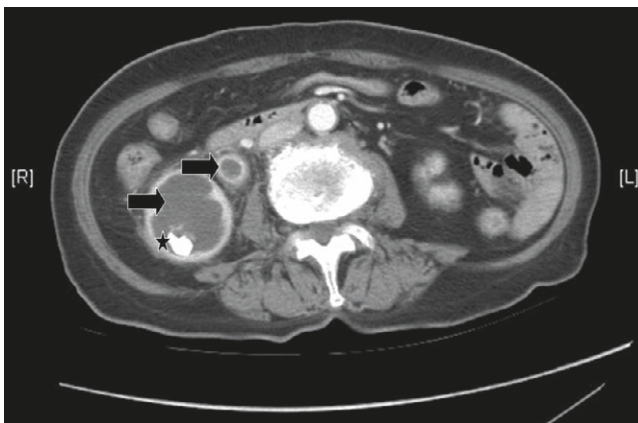
Renal ultrasonography displayed marked right hydronephrosis. Abdominal computed tomography (CT) showed several stones in the right kidney with severe hydronephrosis and segmental soft tissue density in the distal third of the ureter (Fig. 1). On endoscopic examination, multiple sessile and necrotic lesions with erythematous changes were found in the bladder, and multiple necrotic brush-like lesions with easy bleeding were noted in the ureter. Percutaneous nephrostomy was performed and turbid, foul-smelling fluid was drained. Cytology of the drained pus disclosed neutrophils without malignant cells. Biopsies of the urinary bladder and ureter revealed erosion and acute inflammation. According to the culture and sensitivity test, antimicrobial treatment with cephadrine (500 mg every 6 hours) followed by amoxicillin-clavulanic acid (100 mg twice daily) was given for 1 month.

Right nephrectomy was performed subsequently under the impression of poor right renal function with

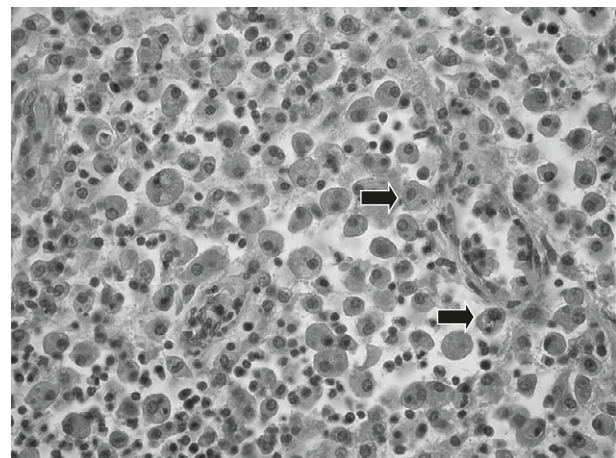
infection. Grossly, the external surface of the kidney was mildly contracted. On the cut surface, the pelvis and calyces were dilated. Two stones measuring up to 1.5 cm in diameter were noted in the lower calyces. Multiple irregular soft yellowish plaques were noted in the calyces and renal pelvis (Fig. 2). Microscopically, the kidney and ureter showed malakoplakia presenting with classic Michaelis-Gutmann inclusion bodies in the collecting system. The malakoplakia was filled with foamy histiocytes admixed with dense infiltration of acute and chronic inflammatory cells in a background of granulation tissue (Fig. 3). The renal parenchyma showed interstitial fibrosis and tubular atrophy with thyroidization. The Michaelis-Gutmann bodies stained positively with periodic acid-Schiff stain for iron (Fig. 4) and von Kossa stain for calcium (Fig. 5).



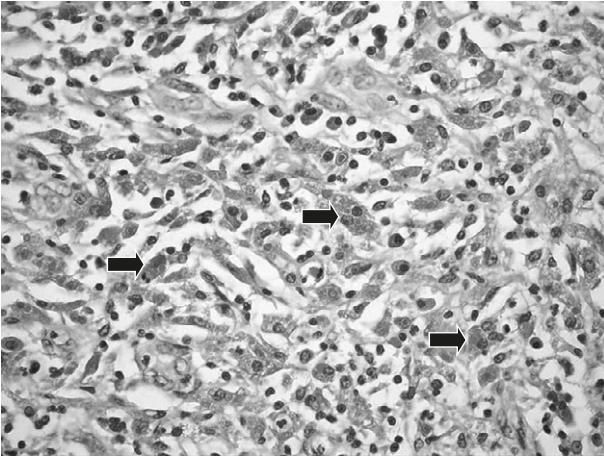
**Fig. 2** — Soft yellowish plaques (arrow) are seen in the nephrectomized kidney.



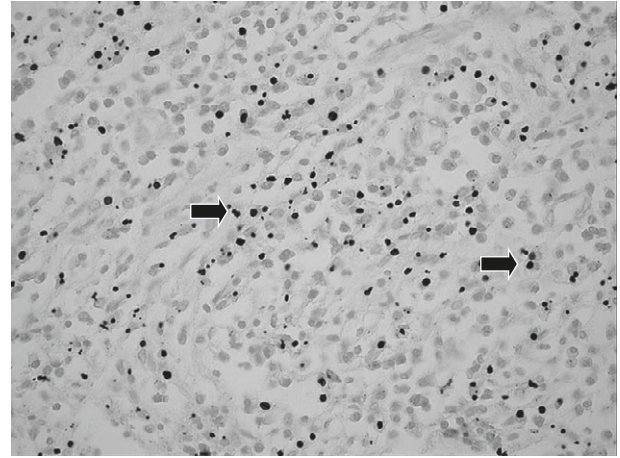
**Fig. 1** — Abdominal computed tomography reveals severe right hydronephrosis and hydroureter (arrows) with a renal stone (asterisk).



**Fig. 3** — Michaelis-Gutmann bodies (arrows) are remarkable in malakoplakia (hematoxylin & eosin, 200×).



**Fig. 4 — Periodic Acid-Schiff stain shows Michaelis-Gutmann bodies (arrows) (200×).**



**Fig. 5 — Von Kossa stain shows Michaelis-Gutmann bodies (arrows) (200×).**

The patient tolerated the operation well and regained her good health status progressively. She was regularly followed-up at the urologic outpatient department of Hualien Tzu Chi Hospital.

### 3. Discussion

The first human case of malakoplakia was reported by von Hansemann in 1901. The term malakoplakia was coined by von Hansemann in 1903 and is derived from the Greek words malakos (soft) and plakos (plaque) (3).

Malakoplakia is a rare inflammatory disorder seen mostly in the genitourinary tract, especially the bladder, among patients over the age of 50 years, and is usually associated with coliform infection. It has also been described in the colon, lungs, bones, brain, conjunctiva, pancreas, skin, tonsils, and adrenal gland. Urinary tract malakoplakia affects females four times as frequently as males, but extraurinary tract malakoplakia is more common in males (2).

The symptoms of malakoplakia depend largely on the organ involved. Bladder malakoplakia presents with irritative voiding symptoms and hematuria. Ureteral malakoplakia can cause stricture and obstruction. Renal parenchymal malakoplakia presents with fever, flank pain or a mass (4).

Numerous theories have been proposed to explain the pathogenesis of malakoplakia. Infection, immunosuppressed state, a neoplasm, systemic disorder, and even genetic alterations have been postulated. The right renal stone might have been the infectious origin of the malakoplakia in our patient. Cases of malakoplakia have been found to be related to diabetes mellitus (5,6). The urine culture in our patient grew *E. coli* and, interestingly, resistance to antimicrobials in this patient was also seen, as in a

previously reported case (6). Could malakoplakia be induced by an unusual strain of *E. coli*? The question needs further study to answer.

The antimicrobial treatment for this patient was determined by the culture and sensitivity test. Cephradine and amoxicillin-clavulanic acid were used. The fluoroquinolones appear to be potentially successful in managing this disorder because of high uptake by macrophages (7). In combination with medical management, this treatment can be curative. Surgery is restricted to situations where conservative management proves to be ineffective. Nephrectomy is required in cases of unilateral advanced disease in which the general condition of the patient is poor (8).

### References

1. Michaelis L, Gutmann C. Ueber eischlüsse in blasentumoren. *Z Klin Med* 1902;47:208.
2. Stanton MJ, Waxted W. Malacoplakia: a study of the literature and current concepts of pathogenesis, diagnosis and treatment. *J Urol* 1981;125:139-46.
3. von Hansemann D. Uber malakoplakie der harnblase. *Virch Arch Path Anat* 1903;173:302-8.
4. Dhabalia JV, Nelivigi GG, Jain NK, Suryavanshi M, Kakkattil S. Malakoplakia of the ureter: an unusual case. *Indian J Urol* 2008;24:261-2.
5. Chung HM, Yu TJ, Eng HL, Lin JW. Renal parenchymal malakoplakia presented as a refractory urinary tract infection and a renal tumor—a case report and review. *JTUA* 1998; 9:45-9.
6. Chen DY, Hsu YS. Renal malacoplakia associated with diabetes mellitus. *JTUA* 2004;15:70-4.
7. Dohle G, Zwartendijk J, Van Krierken JH. Urogenital malakoplakia treated with fluoroquinolones. *J Urol* 1993;150: 1518-20.
8. Velásquez López JG, Vélez Hoyos A, Uribe Arcila JF. Malakoplakia in urology: six cases and review of the literature. *Actas Urol Esp* 2006;30:610-8.