



Case Report

Delayed Diagnosis of Complete Tracheal Transection After Blunt Neck Trauma

Shih-Hsuan Hsiao¹, Bing-Shuo Chen², Tsan-Mu Lee², Szu-Yi Hsu², Yu-Yung Lai^{2*}

¹Department of Otolaryngology and Head and Neck Surgery, Buddhist Dalin Tzu Chi General Hospital, Chiayi, Taiwan

²Department of Anesthesiology, Buddhist Dalin Tzu Chi General Hospital, Chiayi, Taiwan

Article info

Article history:

Received: January 24, 2008

Revised: February 11, 2008

Accepted: May 27, 2008

Keywords:

Blunt injury

Bronchoscopy

Trachea

Tracheal transection

Abstract

The clinical features of tracheal injury include hoarseness, subcutaneous emphysema and edema, and bruising of the neck. Patients with tracheal injury may present with minimal signs that are easily overlooked. The priority in treating such patients is to appropriately identify the tracheal anatomy before further treatment is administered. In this case, a male patient aged 17 years was injured over the first tracheal ring while riding a motorcycle. His stable condition obscured pathognomonic signs of complete cervical tracheal transection, which caused an unnecessary delay in treatment. In a case such as ours, the application of high resolution computed tomography (CT), as an adjuvant to bronchoscopy is important. If tracheal transection is suspected, the proximal and distal ends of the trachea might be not on the same axis and traditional laryngoscopy should not be performed in haste. A CT virtual bronchoscopic evaluation can provide great accuracy when analyzing the central and segmental bronchi, and can prevent a delayed diagnosis of complete tracheal transection. If the diagnosis is still not definite, then diagnostic bronchoscopy and intubation at the operating room is recommended. (*Tzu Chi Med J* 2009;21(1):77–80)

*Corresponding author. Department of Anesthesiology, Buddhist Dalin Tzu Chi General Hospital, 2, Min-Sheng Road, Dalin, Chiayi, Taiwan.

E-mail address: YuhYeong_Lai@tzuchi.com.tw

1. Introduction

Tracheobronchial transection after blunt cervical trauma is rare and its diagnosis is easily delayed because the clinical findings may be subtle and non-specific (1). Demetriades et al reported that 68% of 223 patients with penetrating neck trauma were awake, alert and asymptomatic for injuries to the aerodigestive tract (2).

In such patients, intubation by direct laryngoscopy may be difficult and high risk. Cricothyroidotomy

does not always provide a stable airway because the distal transected segment may be below the incision site (3). Early diagnosis and treatment of tracheobronchial transection lead to the best outcome (1,4,5). Radiography, computed tomography (CT), barium swallow studies and endoscopic evaluations are the recommended options for evaluating such injuries (1,4). Bronchoscopy-assisted diagnosis and intubation are the most important tools when managing patients with/without C-spine fractures (1,3–11). Here, we describe the successful restoration of the airway tract

in a patient with complete tracheal transection. This case demonstrates the value of trauma images and why laryngoscopy may be ill advised.

2. Case report

A male adolescent aged 17 years was injured driving his motorcycle into an electrical cable. At the emergency room, the patient was conscious. His body temperature was 36.8°C, his pulse was 96 bpm, his respiratory rate was 18 breaths per minute and his blood pressure was 136/86 mmHg. Neck radiography showed bilateral cervical emphysema (Fig. 1). A barium swallow did not reveal any pharyngeal or esophageal perforation. He was admitted because there was swelling of his neck in association with subcutaneous emphysema, stridor and hoarseness. He was later transferred to the ward with stable vital signs.

A CT scan obtained after admission revealed pneumomediastinum, cervical emphysema and subcutaneous emphysema over the right axillary area and right maxillary sinusitis with fluid collection. The radiologist did not recognize the tracheal injury, but the thoracic surgeon and the otolaryngologist suspected it on the basis of the patient's clinical presentation. He was first treated with prophylactic antibiotics and steroids conservatively and then, at a later date, there was further evaluation of the sore throat.

After 2 days of treatment, the patient's hoarseness persisted. He felt pain when swallowing and had mild dyspnea. After close coordination between the otolaryngologist, chest surgeon and anesthesiologist, we agreed that a flexible bronchoscopic exam should be performed and that we should be fully prepared to secure the patent airway during this procedure.

For safety reasons, the flexible bronchoscopy examination was carried out in the operating room and was scheduled to prevent acute deterioration or loss of the patient's airway. On arrival, he was alert and oriented but presented with hoarseness during the preanesthesia assessment; an obvious abrasion was noted over the patient's neck, but there were no other associated major injuries (Fig. 2).

In the operating room, the patient's vital signs and hemodynamics were stable. Five puff sprays of 10% lidocaine were used to lubricate the lumen of a Parker tube (inner diameter 6.5 mm) through which an appropriate fiberoptic bronchoscope (an Olympus BF P40: O.D. 5.0 mm) with an attached video camera (Karl Storz) was inserted, allowing the larynx to be viewed on a monitor by the entire medical team. Intravenous ketamine (25 mg) was then administered to the patient. The distal half of the endotracheal tube was lubricated by spraying 10% lidocaine. Surprising images of the upper and lower airways were recorded. Initially we could not localize the distal segment of trachea in

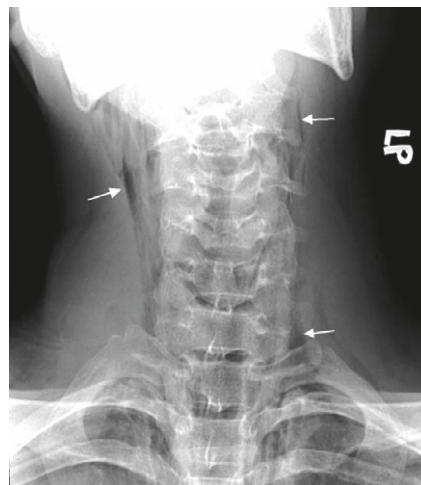


Fig. 1 — Radiograph of the cervical spine shows air in the soft tissues of the neck.

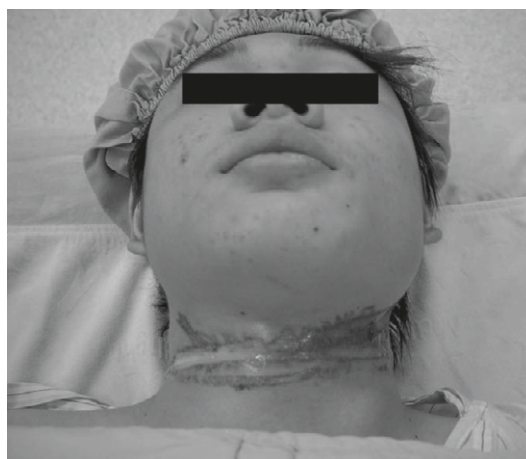

Fig. 2 — Abrasions are clearly present on the front of the patient's neck.

the central field (Fig. 3B). After careful tracing of the anatomy, the distal lumen of trachea was found to have deviated to the left and upper range of the bronchoscope's field of vision (Fig. 3C). After the scope had entered the distal segment of the trachea, the endotracheal tube was passed over the scope. Thiopental (5 mg/kg) and succinylcholine (2 mg/kg) were given as soon as the carina was visualized in the fiberoptic bronchoscope. Tearing of the subglottic mucosa and bleeding were noted during a follow-up viewing through the second nostril (Fig. 3D).

An anterior cervical incision was made and this revealed complete tracheal transection at the level of the first tracheal ring. The distal segment of the trachea had retracted 3.5 cm toward the sternum. Primary repair was undertaken. A 5-mm endotracheal

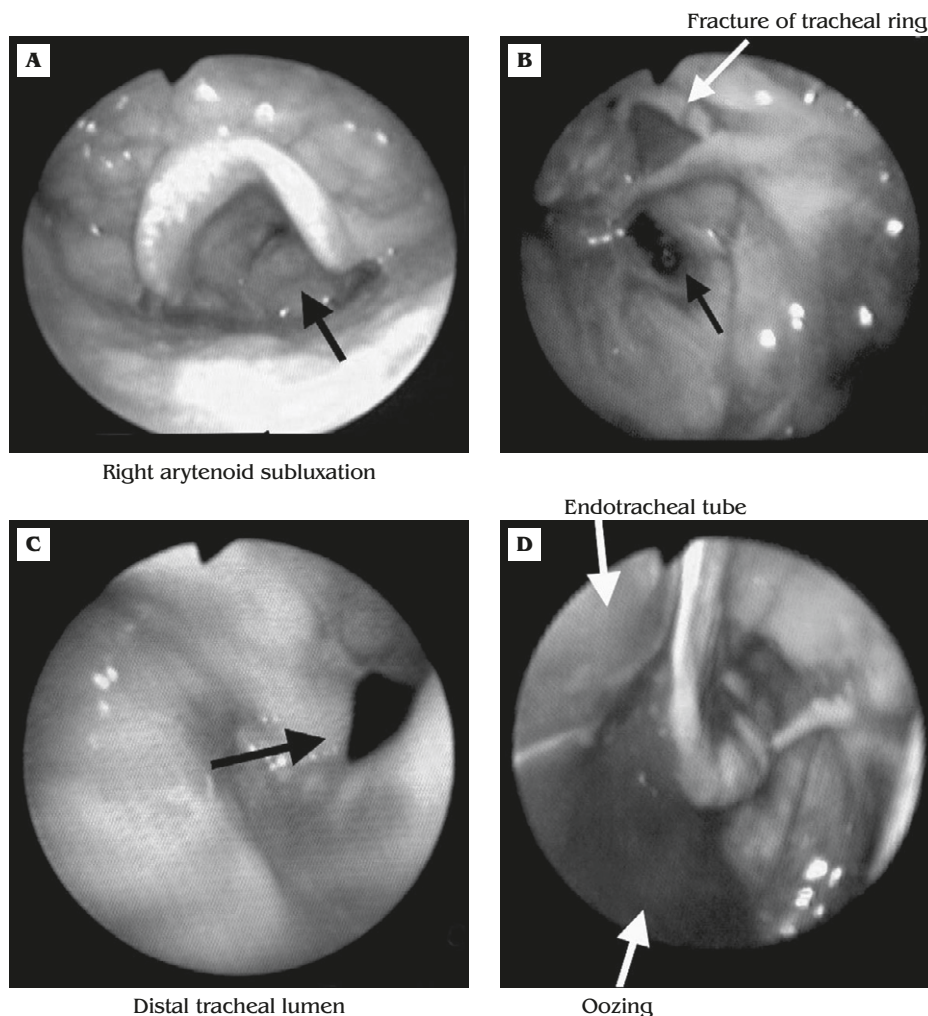


Fig. 3 — Video-bronchoscopic images of the trachea show: (A) patent upper airway with subluxation of the right arytenoid (arrow); (B) the distal segment of the trachea is invisible in the central field (black arrow indicates a blood clot); (C) the lumen has deviated to one side of the distal trachea (arrow); (D) a follow-up examination via the second nostril.

tube was inserted into the distal trachea to facilitate closure of the posterior tracheal wall.

On day 50 after suturing, the patient presented with stenosis, which was treated with dilation. This was followed by thyroplasty to improve phonation. He is now able to cope with his job and take care of his daily life activities.

3. Discussion

Traumatic tracheal injury after blunt neck trauma is rare, but its mortality rate is fairly high (12). In a prospective study of 223 patients with penetrating neck injuries, 14 (6.3%) had injuries to the aerodigestive track (13). In a retrospective study of 104 tracheal and bronchial injuries, about 80% of related deaths occurred before patients were admitted to the hospital (14).

Isolated tracheal disruption in association blunt injuries can occur in traffic accidents, especially motorcycle accidents (1,3–7,9,15–17). Most reported patients are awake, alert and oriented on arrival at the hospital and because they have no obvious symptoms of aerodigestive injuries, physicians need to maintain a high index of suspicion related to nonspecific signs such as dyspnea, cough, subcutaneous emphysema and hemoptysis. If the patient is conscious, the mechanism of injury and vocal changes are important clues. The alert patient with total tracheal transection, such as ours, may have little respiratory distress because the peritracheal fascial sleeves and other soft tissues serve as an airway. Such injuries might be tolerated for 1–2 days. Our patient developed dyspnea 2 days after he was admitted.

Chest and neck radiography is the standard investigation of choice, but initial chest radiographs are frequently normal. Subcutaneous emphysema of the

neck is the most consistent radiographic finding. As we have shown, a patient with an obvious neck injury on physical examination and air in the paratracheal soft tissue on anterior-posterior cervical spine radiograph should be treated as a significant tracheal injury until proven otherwise. Lim et al suggested that three-dimensional CT could be used as a screening test to efficiently obtain diagnostic information (4). The CT scan data can also be reformatted to create a virtual bronchoscopy that closely resembles the images obtained from a flexible bronchoscopy. Fiberoptic bronchoscopy enables further evaluation of the location of injury, dynamic vocal cords movement and any other associated airway injury (Fig. 3A). Furthermore, fiberoptic bronchoscopy can be used to guide endotracheal intubation if the patient's airway is deteriorating. The importance of fiberoptic bronchoscopy has been discussed in previous articles. These reports agreed that there is a slight possibility that airway problems could be missed and therefore repeat video-bronchoscopic follow-up should be performed if the clinical situation suggests an abnormality (8,10).

In patients such as ours, direct intubation with a laryngoscope may be difficult and may pose a high risk if, for example, the laryngoscope enters the soft issue (18). Case reports have shown that complete disruption or obstruction can occur during intubation or tracheostomy procedures (1,16). Intubation over a fiberoptic bronchoscope has been advocated as an aid when managing upper-airway injuries (1,8). In our case, it would have been impossible to insert an endotracheal tube into the distal part of trachea without the fiberoptic guide because the two parts of transected trachea were not in the same axis (Fig. 3B).

Tracheal transection after blunt trauma to the neck has been discussed in many previous reports, but diagnosis of this condition is still difficult (1-9,11,14-18). Although some have suggested that the multirow-detector CT scanners might provide useful diagnostic information of the upper, central and segmental airways within a short acquisition time, no method is more reliable than bronchoscopy for directly visualizing the trauma site inside the trachea (4,10). Traditional laryngoscopic intubation is not recommended, even in patients without acute respiratory distress, because failed attempts may produce airway obstruction and cause further damage.

We emphasize that although the airway might be stable in clinical presentation, the central airway may not be essentially normal. In cases with suspected tracheal injury, patients should undergo high-resolution CT at an early stage (19). If intubation seems to be necessary, patients should be taken to the operating room for performance of a well-prepared video-bronchoscopy controlled by an available surgeon (18).

References

- Hosny A, Bhendwal S, Hosni A. Transection of cervical trachea following blunt trauma. *J Laryngol Otol* 1995;109:250-1.
- Demetriades D, Velmahos GG, Asensio JA. Cervical pharyngoesophageal and laryngotracheal injuries. *World J Surg* 2001;25:1044-8.
- Norwood SH, McAuley CE, Vallina VL, Berne JD, Moore WL. Complete cervical tracheal transection from blunt trauma. *J Trauma* 2001;51:568-71.
- Lim KE, Liu YC, Hsu YY. Tracheal injury diagnosed with three-dimensional imaging using multidetector row computed tomography. *Changgen Yi Xue Za Zhi* 2004;27:217-21.
- Hsu IL, Fong Y. Complete cricotracheal disruption following blunt trauma to the neck. *Formosa J Surg* 2003;36:220-5.
- Kawaguchi T, Kushibe K, Takahama M, Taniguchi S. Bluntly traumatic tracheal transection: usefulness of percutaneous cardiopulmonary support for maintenance of gas exchange. *Eur J Cardiothorac Surg* 2005;27:523-5.
- Bowley DM, Plani F, Murillo D, Smith M, Degiannis E. Intubated, ventilating patients with complete tracheal transection: a diagnostic challenge. *Ann R Coll Surg Engl* 2003;85:245-7.
- Baumgartner FJ, Ayres B, Theuer C. Danger of false intubation after traumatic tracheal transection. *Ann Thorac Surg* 1997;63:227-8.
- Waldron RJ, Young RJ. Traumatic tracheal transection. *Anaesth Intensive Care* 1993;21:105-7.
- Hara KS, Prakash UB. Fiberoptic bronchoscopy in the evaluation of acute chest and upper airway trauma. *Chest* 1989;96:627-30.
- Roberge RJ, Squyres NS, Demetropoulos S, McAuliffe M, Vukich D. Tracheal transection following blunt trauma. *Ann Emerg Med* 1988;17:47-52.
- Cicala RS, Kudsk KA, Butts A, Nguyen H, Fabian TC. Initial evaluation and management of upper airway injuries in trauma patients. *J Clin Anesth* 1991;3:91-8.
- Demetriades D, Theodorou D, Cornwell E, et al. Evaluation of penetrating injuries of the neck: prospective study of 223 patients. *World J Surg* 1997;21:41-8.
- Ecker RR, Libertini RV, Rea WJ, Sugg WL, Webb WR. Injuries of the trachea and bronchi. *Ann Thorac Surg* 1971;11:289-98.
- Goldfaden D, Seifert P, Milloy F, Thomas P, Levitsky S. Combined tracheal transection and innominate artery disruption from blunt chest trauma. *Ann Thorac Surg* 1986;41:213-5.
- Lawhorne TW, Jeyasingham K, Kieffer RF. Transection of the trachea secondary to blunt trauma. *Br J Surg* 1978;65:176-8.
- Chow JL, Coady MA, Varner J, Cannon W, Spain D, Brock-Utne JG. Management of acute complete tracheal transection caused by nonpenetrating trauma: report of a case and review of the literature. *J Cardiothorac Vasc Anesth* 2004;18:475-8.
- O'Connor PJ, Russell JD, Moriarty DC. Anesthetic implications of laryngeal trauma. *Anesth Analg* 1998;87:1283-4.
- Hoppe H, Dinkel HP, Walder B. Grading airway stenosis down to the segmental level using virtual bronchoscopy. *Chest* 2004;125:704-11.