



Case Report

Tricuspid Valve Replacement Using Right Heart Bypass Without Cardiac and Pulmonary Ischemia

Rousei Rim*

Department of Cardiovascular Surgery, Buddhist Dalin Tzu Chi General Hospital, Chiayi, Taiwan

Article info

Article history:

Received: December 27, 2007

Revised: January 30, 2008

Accepted: February 25, 2008

Keywords:

Right heart bypass

Tricuspid valve endocarditis

Tricuspid valve replacement

Abstract

Tricuspid valve (TV) surgery is conventionally performed using total cardiopulmonary bypass (CPB) under cardiac arrest. It is inevitably associated with detrimental effects on the heart and lungs because of ischemia in these organs during CPB. A 30-year-old man with TV endocarditis underwent TV replacement using only right heart bypass with continuous pulmonary perfusion and with the heart beating. He recovered rapidly and was discharged from the hospital after a 4-week course of antibiotic therapy. (*Tzu Chi Med J* 2008;20(4):318–321)

*Corresponding author. Department of Cardiovascular Surgery, Buddhist Dalin Tzu Chi General Hospital, 2, Min-Sheng Road, Dalin, Chiayi, Taiwan.
E-mail address: rsr@tzuchi.com.tw

1. Introduction

For patients with tricuspid valve (TV) endocarditis complicated by refractory sepsis and/or right heart failure, TV surgery is indicated and conventionally performed using total cardiopulmonary bypass (CPB) under cardiac standstill. However, CPB may cause a variable degree of cardiac and pulmonary dysfunction (1,2). These detrimental effects can be avoided using right heart bypass (RHB) during TV surgery with continuous pulmonary perfusion and a beating heart.

2. Case report

Four days before admission, a 30-year-old man, an intravenous drug abuser, completed a 6-week course of antibiotic therapy for *Staphylococcus aureus* TV endocarditis at a regional hospital. He came to our emergency department (ED) with a recurrent high fever of up to 39°C and shortness of breath for 2 days.

The hemogram showed marked leukocytosis ($15.75 \times 10^3/\mu\text{L}$) with segments dominating (90%) and thrombocytopenia ($93 \times 10^3/\mu\text{L}$). Chest radiography disclosed cardiomegaly, right heart enlargement, and pulmonary artery engorgement (Fig. 1). Echocardiography revealed large vegetations ($1.7 \times 0.8 \text{ cm}$) on the TV with severe tricuspid regurgitation (Fig. 2). His arterial blood pressure fluctuated, and then decreased to a systolic pressure of 75 mmHg soon after arrival. Under the diagnosis of TV endocarditis with relapsing sepsis and shock, he underwent immediate surgical intervention for TV endocarditis after measures to stabilize his vital signs in the ED.

2.1. Surgical technique and bypass circuit

Under endotracheal general anesthesia, a median sternotomy was made. The superior and inferior venae cavae were cannulated separately after low dose intravenous heparinization (1.5 mg/kg) to keep

the activated clotting time at 200–300 seconds. A 21-F arterial cannula was inserted into the main pulmonary artery (MPA). The bypass circuit consisted of only short heparin bonded tubing and a centrifugal pump (Biopump; Medtronic, Santa Rosa, CA, USA) (Fig. 3). Coronary sinus blood was retrieved with an autologous cell saver (Autolog; Medtronic).

During RHB, the pump flow was adjusted to maintain the systolic blood pressure above 100 mmHg; the body was kept nearly normothermic (36–37°C) with a thermal blanket and warmed infused fluid/blood; the heart was not clamped and remained beating. The lungs were normally ventilated at a tidal

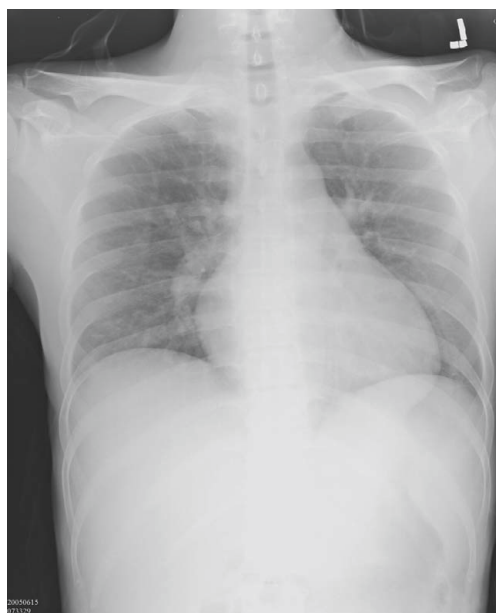

Fig. 1 — Preoperative chest radiography depicts cardiomegaly and engorged pulmonary arteries.

volume of 10–12 mL/kg as in regular endotracheal general anesthesia. Through a right atriotomy, the severely destroyed TV and vegetations were completely debrided and replaced with a 31-mm St. Jude mechanical valve (St. Jude Medical Company, St. Paul, MN, USA). The right atrium was closed, the patient was weaned from RHB, and all cannulae were removed. Heparin was reversed with protamine sulfate. The total RHB time was 70 minutes. After wound closure, the patient was transferred to the surgical intensive care unit for postoperative care.

Hemodynamic and arterial blood gas data are shown in Table 1. Both cardiac and pulmonary function improved postoperatively.

The patient recovered rapidly and was extubated 5 hours after the operation. The amount of chest

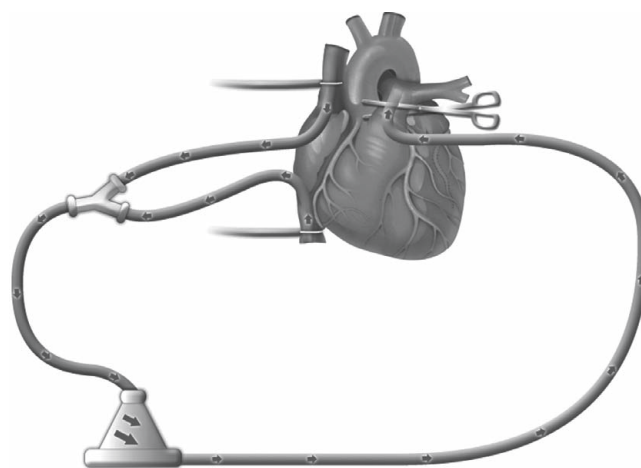


Fig. 3 — Right heart bypass setting depicts drained venous blood that is pumped back into the main pulmonary artery (MPA) by a centrifugal pump. The MPA may be clamped to prevent air embolism.

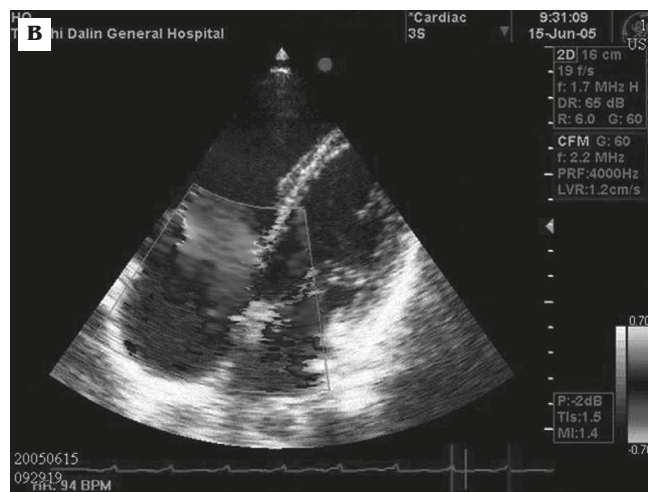
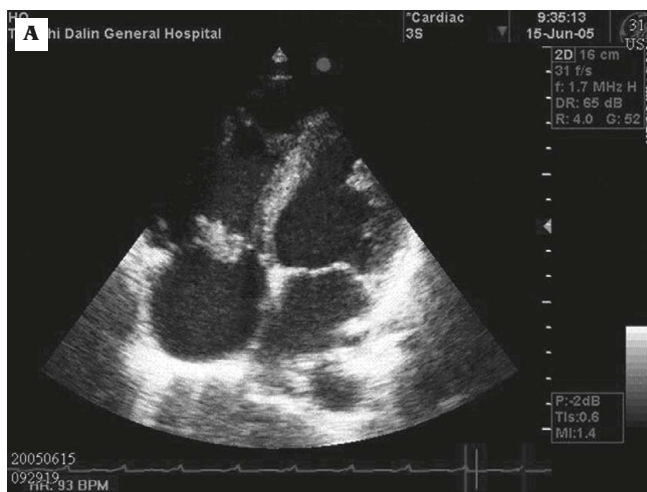
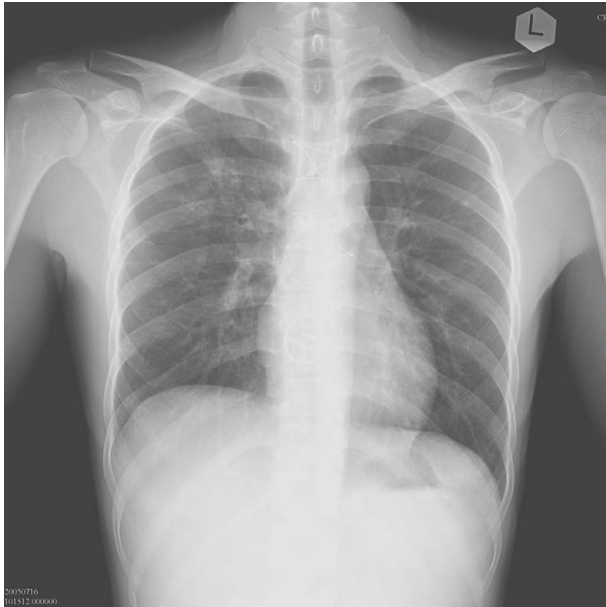

Fig. 2 — Preoperative echocardiography depicting: (A) large vegetations adhering to the tricuspid valve; and (B) severe tricuspid regurgitation.

Table 1 — Perioperative hemodynamics and arterial blood gas (ABP)

	ABP (mmHg)	pH	PaO ₂ /FiO ₂	PCO ₂	O ₂ saturation (%)
Preoperative	75/63	7.50	200	35.4	98
Right heart bypass	110/50	7.35	350	33.0	99
Postoperative	120/50	7.47	300	36.2	99

ABP = arterial blood pressure.

**Fig. 4 — Postoperative chest radiography depicts a normal heart size and clear lung fields.**

drainage was small, and the chest tubes were removed 2 days later. Follow-up chest radiography showed a normal heart size and clear lungs (Fig. 4). Blood cultures grew oxacillin-sensitive *S. aureus*. He received a 4-week course of antibiotic therapy and was discharged from hospital with discharge medications that consisted only of warfarin for anticoagulation of the mechanical TV.

The patient is alive and well and has had regular follow-up for 1 year after surgery.

3. Discussion

Total CPB with cardiac arrest remains the standard technique for TV replacement. Although this technique can offer a bloodless and motionless surgical field, it is associated with systemic inflammatory responses (SIR) (3) and deranged function of the heart, lung and kidney (4). The SIR are mainly due to contact between blood and the oxygenator with ensuing activation of complement, the kallikrein-bradykinin system, neutrophils, platelets, coagulation factors, and other mediators of inflammation (5–11).

In the English literature, there are few reports of TV replacement without CPB. Lee and colleagues (12) presented a case report on TV replacement without regular CPB for a patient with TV endocarditis. However, their patient was on venovenous extracorporeal membrane oxygenation during the main operative procedure, which cannot prevent oxygenator-related SIR (5–11). In addition, the patient's venous blood was drained into the main pulmonary trunk by gravity only without using a pump, which could cause incomplete venous drainage and ensuing systemic venous hypertension. Uchida and colleagues presented a similar report in Japanese (13) on TV replacement with RHB. But their bypass circuit and a membranous oxygenator were self designed, which increased the complexity and cost of their procedure.

In this report, the advantages of dispensing with the oxygenator are suggested by the minimal postoperative SIR and rapid recovery, although inflammatory mediators were not measured. Continuous cardiopulmonary perfusion and ventilation during RHB are very important for a smooth postoperative course. Without intraoperative myocardial ischemia, postoperative myocardial depression is almost negligible. Maintaining lung perfusion and using the patient's own lungs as an oxygenator not only prevents ischemia-reperfusion lung injury (14) and improves postoperative lung function (15), but also preserves the function of the lungs as bacterial and gas filters (16) and as a degradation site for norepinephrine and bradykinin (17,18). In addition, there are substantial cost savings by using RHB without an oxygenator and by avoiding the use of additional bypass tubing and equipment.

In conclusion, RHB with the heart beating is a simple, safe, cost-effective, and easily reproducible technique for performing TV replacement. It is believed to be less invasive physiologically, and, particularly, more beneficial to patients with preoperative sepsis and marginal cardiopulmonary function.

References

1. Hennein HA, Ebba H, Rodriguez JL, et al. Relationship of the proinflammatory cytokines to myocardial ischemia and dysfunction after uncomplicated coronary revascularization. *J Thorac Cardiovasc Surg* 1994;108:626–35.
2. Messent M, Sullivan K, Keogh BF, Morgan CJ, Evans TW. Adult respiratory syndrome following cardiopulmonary

- bypass: incidence and prediction. *Anaesthesia* 1992;47:267-8.
3. Butler J, Rocker GM, Westaby S. Inflammatory response to cardiopulmonary bypass. *Ann Thorac Surg* 1993;55:552-9.
 4. Chenoweth DE, Cooper SW, Hugh TE, Stewart RW, Blackstone EH, Kirklin JW. Complement activation during cardiopulmonary bypass: evidence for generation of C3a and C5a anaphylatoxins. *N Engl J Med* 1981;304:497-503.
 5. Quiroga MM, Miyagishima R, Haendschen LC, Glovsky M, Martin BA, Hogg JC. The effect of body temperature on leukocyte kinetics during cardiopulmonary bypass. *J Thorac Cardiovasc Surg* 1985;90:91-6.
 6. Riegel W, Spillner G, Schlosser V, Horl WH. Plasma levels of main granulocyte components during cardiopulmonary bypass. *J Thorac Cardiovasc Surg* 1988;95:1014-9.
 7. Zilla P, Fasol R, Groscurth P, Klepetko W, Reichenspurner H, Wolner E. Blood platelets in cardiopulmonary bypass operations. Recovery occurs after initial stimulation, rather than continual activation. *J Thorac Cardiovasc Surg* 1989;97:379-88.
 8. Hammerschmidt DE, Stroncek DF, Bowers TK, et al. Complement activation and neutropenia occurring during cardiopulmonary bypass. *J Thorac Cardiovasc Surg* 1981;81:370-7.
 9. Ellison N, Behar M, MacVaugh H 3rd, Marshall BE. Bradykinin, plasma protein fraction and hypotension. *Ann Thorac Surg* 1980;29:15-9.
 10. Dybdahl B, Wahba A, Lien E, et al. Inflammatory response after open heart surgery: release of heat-shock protein 70 and signaling through toll-like receptor 4. *Circulation* 2002;105:685-90.
 11. Jacobs LA, Klopp EH, Seamone SR, Topaz W, Gott VL. Improved organ function during cardiac bypass with a roller pump modified to deliver pulsatile flow. *J Thorac Cardiovasc Surg* 1969;58:703-12.
 12. Lee KK, Yu HY, Chen YS, Chi NH, Chang CI, Wang SS. Off-pump tricuspid valve replacement for severe infective endocarditis. *Ann Thorac Surg* 2007;84:309-11.
 13. Uchida T, Sasako Y, Kobayashi J, et al. Tricuspid valve replacement using right heart bypass in patient with liver cirrhosis. *Japanese Kyobu Geka* 2001;54:132-5.
 14. Kuratani T, Matsuda H, Sawa Y, Kaneko M, Nakano S, Kawashima Y. Experimental study in a rabbit model of ischemia-reperfusion lung injury during cardiopulmonary bypass. *J Thorac Cardiovasc Surg* 1992;103:564-8.
 15. Richter JA, Meisner H, Tassani P, Barankay A, Dietrich W, Braun SL. Drew-Anderson technique attenuates systemic inflammatory response syndrome and improves respiratory function after coronary artery bypass grafting. *Ann Thorac Surg* 2000;69:77-85.
 16. Glenville B, Ross D. Coronary artery surgery with patient's lungs as oxygenator. *Lancet* 1986;2:1005-6.
 17. Gillis CN, Greene NM, Cronau LH, Hammond GL. Pulmonary extraction of 5-hydroxytryptamine and norepinephrine before and after cardiopulmonary bypass in man. *Circ Res* 1972;30:666-74.
 18. Friedli B, Kent G, Olley PM. Inactivation of bradykinin in the pulmonary vascular bed of newborn and fetal lambs. *Circ Res* 1973;33:421-7.