



Case Report

Hepatocellular Carcinoma Metastatic to the Palatine Tonsil

Yu-Hsuan Wen¹, Rong-Hsing Yang¹, Pei-Rong Chen^{1,2},
Tzung-Shiahn Sheen³, Hung-Pin Wu^{2,4,5*}

¹Department of Otolaryngology, Buddhist Tzu Chi General Hospital, Hualien, Taiwan

²School of Medicine, College of Medicine, Tzu Chi University, Hualien, Taiwan

³Department of Otolaryngology, National Taiwan University Hospital, Taipei, Taiwan

⁴Department of Otolaryngology, Buddhist Tzu Chi General Hospital, Taipei Branch, Taipei, Taiwan

⁵Institute of Occupational Medicine and Industrial Hygiene, National Taiwan University, Taipei, Taiwan

Article info

Article history:

Received: November 13, 2007

Revised: December 3, 2007

Accepted: December 17, 2007

Keywords:

Hepatocellular carcinoma

Metastatic cancer

Palatine tonsil

Abstract

Metastatic cancer to the palatine tonsil is extremely rare. We describe a 66-year-old man who was diagnosed with hepatocellular carcinoma 2 years previously and who had the sensation of having a lump in his throat for 1 month before presentation. One reddish-blue, ulcerated, granular tumor was found at his right tonsillar fossa. After tonsillectomy, pathology showed metastatic hepatocellular carcinoma. The patient died from sepsis and hepatic failure 9 months later. (*Tzu Chi Med J* 2008;20(3):221–222)

*Corresponding author. Department of Otolaryngology, Buddhist Tzu Chi General Hospital, 289, Jianguo Road, Taipei, Taiwan.

E-mail address: hungpin_wu@yahoo.com.tw

1. Introduction

Metastatic cancer to the palatine tonsil is extremely rare. This report documents a histopathologically confirmed metastatic hepatocellular carcinoma (HCC) to the palatine tonsil. To our knowledge, only one such case has been previously reported (1).

2. Case report

A 66-year-old male patient was referred to our ENT clinic in November 1997 because of a progressively enlarging right palatine tonsil. Two years previously, he had been diagnosed with HCC with the initial presentation of abdominal fullness for 3 months. Computed tomography had shown multiple hepatic tumors,

mainly at the right lobe. He underwent right hepatic lobectomy and was regularly followed-up.

Owing to progressive sensation of having a lump in the throat for 1 month, he was transferred to our ENT clinic for further investigation. Neither obvious dysphagia nor odynophagia was mentioned then. Physical examination found a reddish-blue, ulcerated, granular tumor at the right tonsillar fossa (Fig. 1). Several ulcerated skin lesions were also noted on the lower limbs. He underwent tonsillectomy via general anesthesia. Microscopically, the neoplasm showed tumor cells with prominent nuclei and nucleoli, and basophilic cytoplasm arranged in a trabecular growth pattern. Bile lakes (Fig. 2) were occasionally seen. The tumor cells were negative for S-100 and HMB-45. *In situ* hybridization of EBER-1 was also negative. Metastatic HCC was thus diagnosed. Nine months after

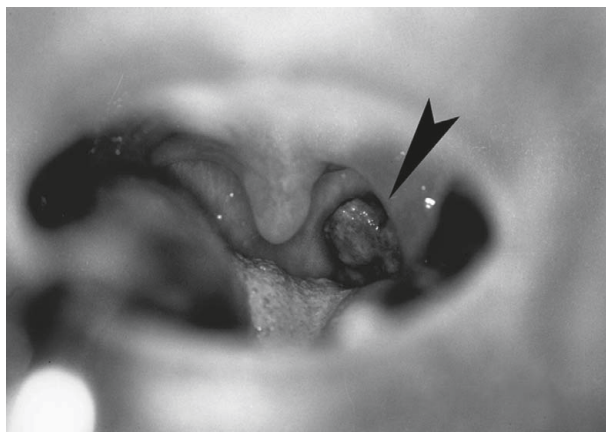


Fig. 1 — Ulcerated granular tumor at the right tonsillar fossa (arrow).

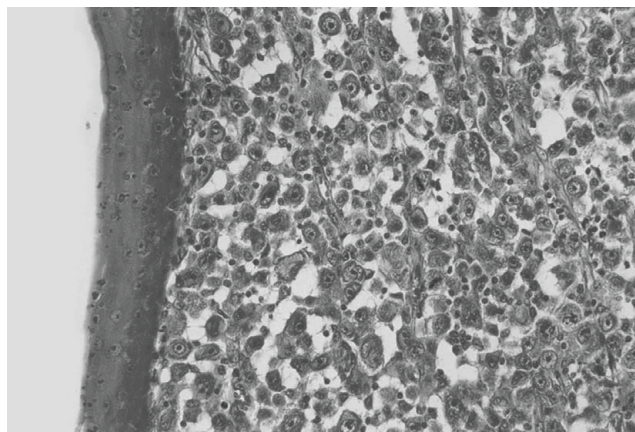


Fig. 2 — Histopathology shows hepatocellular carcinoma cell nests with the presence of bile lakes beneath the unremarkable tonsillar squamous epithelium (hematoxylin & eosin; original magnification, 66 \times).

tonsillectomy, the patient died of hepatic failure and sepsis.

3. Discussion

Malignant neoplasms of the palatine tonsil are not unusual. Of them, less than 1% is metastatic (2). The low incidence of tonsillar metastasis is probably based on its unique lymphatic system. Anatomically, the palatine tonsil is between the anterior and posterior pillars. It contains efferent lymphatic drainage only, without an afferent one. Owing to this characteristic lymphatic system, determination of the route of metastasis to the tonsil was difficult in our patient. The cancer cells probably seeded to the palatine tonsil via a retrograde route. The other possible route of metastasis is hematogenous spread through the paravertebral plexus (3). In this patient, metastasis over the skin of his lower limbs supports the likelihood of hematogenous spread.

HCC is a highly malignant disease with extremely poor outcome. The most common site of metastasis

by HCC is the lung, followed by the abdominal organs, distant lymph nodes, diaphragm, adrenals and bone (4). Metastasis to the palatine tonsil is very rare and only one case has been previously documented in the literature (1). The prognosis of HCC with palatine tonsillar metastasis is grave. This patient and the previously reported case lived for less than 1 year after diagnosis despite aggressive treatment.

References

1. Lianes F, Sanz-Ortega J, Suarez B, et al. Hepatocellular carcinomas diagnosed following metastasis to the oral cavity. Report of 2 cases. *J Periodontol* 1996;67:717-9.
2. Crawford BE, Callihan MD, Corio RL, et al. Symposium on malignant disease of the oral cavity and related structures. *Otolaryngol Clin North Am* 1979;12:29-43.
3. Batson OV. The role of the vertebral veins in metastatic process. *Ann Intern Med* 1942;16:38-45.
4. MacDonald RA. Primary carcinoma of the liver. *Arch Intern Med* 1957;99:266-79.