



Case Report

Blastic Natural Killer-Cell Lymphoma Presenting in the Skin

Jeng-Wei Tjiu^{1*}, Cheng-Hsiang Hsiao²

¹Department of Dermatology, National Taiwan University Hospital, Taipei, Taiwan

²Department of Pathology, National Taiwan University Hospital, Taipei, Taiwan

Article info

Article history:

Received: May 1, 2007

Revised: May 14, 2007

Accepted: May 19, 2007

Keywords:

Blastic natural killer-cell lymphoma

CD56

Leukemia

Prognosis

Treatment

Abstract

Blastic natural killer (NK)-cell lymphoma is a clinically aggressive hematologic neoplasm with a high incidence of cutaneous involvement. We report a 19-year-old man who presented with asymptomatic, erythematous, infiltrated bean plaques and nodules of various sizes, scattered over the face, trunk and extremities. A skin biopsy specimen revealed diffuse dermal infiltration of medium-sized pleomorphic cells with a blastic appearance. Immunohistochemical studies showed that the tumor cells were positive for CD56, CD43, CD123, and terminal deoxynucleotidyl transferase (TdT). The neoplastic cells were negative for B-cell, T-cell, and myeloid cell markers. *In situ* hybridization for Epstein-Barr virus encoded RNA (EBER) gave a negative result. Flow cytometric analysis of bone marrow aspirate demonstrated a CD56 positive population of blastic cells. A diagnosis of blastic NK-cell lymphoma was made and the skin lesions regressed after treatment with L-asparaginase-based chemotherapy (L-asparaginase, cyclophosphamide, etoposide). The skin lesions regressed after two sessions of chemotherapy. (*Tzu Chi Med J* 2007;19(3):173–178)

*Corresponding author. Department of Dermatology, National Taiwan University Hospital, 7 Chung Shan South Road, Taipei, Taiwan.

E-mail address: jengweitjiu@gmail.com

1. Introduction

Blastic NK-cell lymphoma is an aggressive malignancy and often has cutaneous lesions at initial manifestation. About half of patients have nodal or bone marrow involvement at presentation (1–3). Most patients with only skin involvement at the beginning rapidly develop bone marrow, peripheral blood, and lymph node involvement. Histologically, blastic NK-cell lymphoma shows monocytic infiltrates of medium sized

cells resembling lymphoblasts or myeloblasts with CD56 immunoreactivity (1,4–6). There are about 150 well-documented cases of blastic NK-cell lymphoma in the literature with several large series representing more than half of published cases (2,6–8). Suzuki et al reported 47 patients with blastic NK-cell lymphoma collected from a nationwide survey in a Japanese NK-cell tumor study group from 1994–1998 (8). Petrella et al showed a series of 30 cases from a French study group on cutaneous lymphoma (6). Bekkenk et al from

the Netherlands reported an analysis of 11 new cases and reviewed 52 cases from the literature (2). Massone et al from Austria reported 12 cases of blastic NK-cell lymphoma in their series (7). Blastic NK-cell lymphoma represented 0.7% of the primary cutaneous lymphoma registered by the French Study Group on Cutaneous Lymphomas (6). Due to the rarity of this entity, we herein report a case of blastic NK-cell lymphoma.

2. Case report

A 19-year-old man presented with many erythematous nodules and plaques on the face, trunk and extremities. The nodules and plaques developed rapidly over 1 month. The patient did not complain of any systemic symptoms. Physical examination did not reveal any abnormality. Dermatological examination showed many bean-sized infiltrative, erythematous, non-tender nodules or plaques located on the face, neck, trunk, and extremities (Fig. 1). A skin biopsy specimen taken from the back showed infiltration of medium-sized blastic cells in the dermis and subcutis. Monocytic infiltrates of medium-sized blasts made a diagnosis of large tumor cells (i.e. diffuse large B-cell lymphoma) or predominantly small cells (i.e. small lymphocytic lymphoma) unlikely in this case. The neoplastic cells were characterized by dispersed nuclear chromatin, somewhat irregular nuclear membrane and scant cytoplasm (Fig. 2). No epidermotropism, angiodestruction, or angiocentric pattern was found. Immunohistochemical studies showed that the tumor cells were positive for CD56, CD123, CD43, and terminal deoxynucleotidyl transferase (TdT). The tumor cells were negative for CD3, CD20, CD30, CD79a, and myeloperoxidase. *In situ*

hybridization did not detect Epstein-Barr virus encoded RNA (EBER). A bone marrow biopsy showed hypocellular marrow with an M/E ratio of 3:2. Aggregation of blasts was easily demonstrated in bone marrow sections. The blasts had a pleomorphic appearance from myeloblasts or lymphoblasts. Neoplastic cells were positive for CD56 and CD123 (Fig. 3). Flow cytometric analysis found predominantly CD56 positive blasts in the bone marrow. Laboratory investigations, including complete cell counts, liver enzymes, kidney function and electrolyte levels, were all within normal limits. A whole body computed tomography (CT) scan also found no abnormalities. The patient was diagnosed with blastic NK-cell lymphoma with bone marrow involvement and underwent L-asparaginase-based chemotherapy (L-asparaginase, 10,000 IU (6000 IU/m²) subcutaneous on days 1–7; cyclophosphamide, 600 mg intravenous infusion for 1 hour on day 1–2; etoposide (VP16), 100 mg intravenous infusion on days 1–4). The skin lesions cleared after the first course. However, elevated liver function test (alanine aminotransferase, 383 U/L; reference, 0–35 U/L) postponed subsequent treatment. After liver function returned to normal, a second course of chemotherapy was delivered 6 weeks after the first course with minor side effects of nausea and vomiting. The duration of follow-up was 2 months. This patient will receive allogeneic or autologous stem cell transplantation.

3. Discussion

The World Health Organization (WHO) classification recognizes the following NK-cell malignancies: aggressive NK-cell leukemia; extranodal NK/T-cell leukemia, nasal type; and blastic NK-cell lymphoma (9). The origin of the neoplastic cells in blastic NK-cell

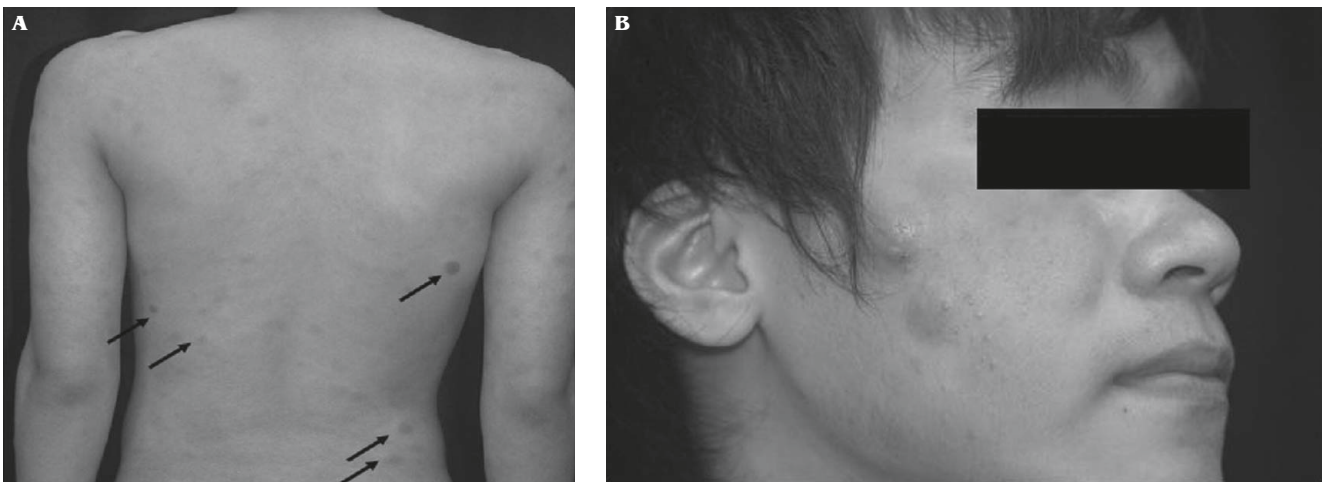


Fig. 1 — (A) Many bean-sized, erythematous, infiltrative plaques located on the back. (B) Confluent erythematous plaques and nodules located on the right cheek.

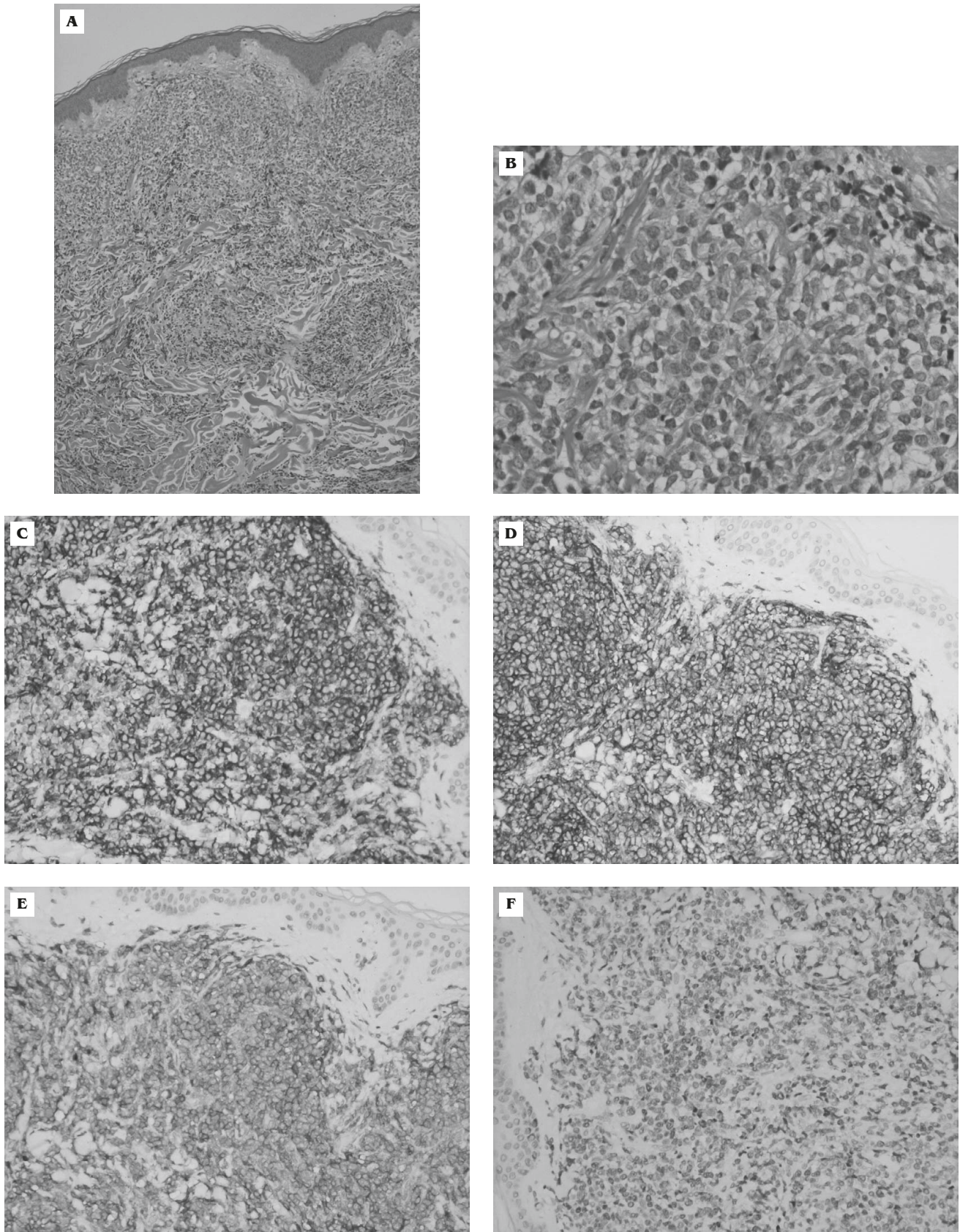


Fig. 2 — (A) Diffuse non-epidermotropic infiltration of medium-sized blast cells in the dermis (hematoxylin & eosin (H&E), 40 \times). (B) The tumor cells have dispersed nuclear chromatin, an irregular nuclear membrane, and scant cytoplasm (H&E, 200 \times). Tumor cells are positive for: (C) CD56 (100 \times); (D) CD43 (100 \times); (E) CD123 (100 \times); and (F) terminal deoxynucleotidyl transferase (100 \times).




Fig. 3 — (A) Medium-sized blasts infiltrating the bone marrow (hematoxylin & eosin, 100×). The neoplastic cells are positive for: (B) CD56 (200×); and (C) CD123 (200×).

lymphoma has not yet been ascertained. Based on the blastic cytologic appearance and CD56 expression, an NK-precursor origin was initially suggested (9). Simultaneous expression of stem cell markers and the NK-cell receptor complex CD94/NKG2 also favored origin from an NK-cell precursor (10). But recent studies found evidence suggesting early plasmacytoid type 2 dendritic cell (DC2) origins (11,12).

Clinically, blastic NK-cell lymphoma commonly presents in the skin with solitary or multiple nodules or tumors with or without concurrent extracutaneous localization (4). About half of patients have bone marrow involvement at presentation (2,3,13). The average age at presentation ranged from 53 to 74.3 years in several reported series (2,7,8).

Histologically, blastic NK-cell lymphoma is characterized by an infiltrate of medium-sized neoplastic cells with blastoid morphology. The epidermis is not involved as a rule, whereas involvement of the subcutaneous tissue is common. The neoplastic cells have finely dispersed chromatin, and absent or indistinct nucleoli resembling lymphoblasts or myeloblasts (2,3,13). A special immunophenotypic feature

of blastic NK-cell lymphoma is positivity for CD56 antigen. The tumor cells usually also express CD4 and CD43 (8). Expression of CD2, CD7, cytotoxic molecules, TdT, CD34 and CD68 varies. Other T cell markers and myelomonocytic markers are negative (14). Since lymphoblastic and myeloblastic neoplasms can also be positive for CD56, stains for CD3 and myeloperoxidase should always be performed in order to exclude these entities (3). The cells express CD123, which supports a relationship with plasmacytoid dendritic cells (15). Recent studies demonstrated that blastic NK-cell lymphoma expresses markers typical of plasmacytoid dendritic cells, in particular the IL-3R alpha chain (CD123) (15).

The differential diagnosis includes other CD56+ lymphomas with cutaneous involvement (2). These include extranodal NK/T-cell lymphoma, nasal type; CD56+ myeloid leukemia; and cutaneous Cd30+ lymphoproliferation with CD56 expression (2,3). Extranodal NK/T-cell lymphoma is nearly always an EBV+ lymphoma. The skin is the second most common site of involvement after the nasal cavity/nasopharynx (3,9,13). Prominent angiocentricity and

angiodestruction are often accompanied by extensive necrosis. The neoplastic cells of extranodal NK/T-cell lymphoma express CD56, cytoplasmic CD3, and cytotoxic proteins, but lack surface CD3 (2,3). In this case, EBV was not detected by *in situ* hybridization. Because the tumor cells were negative for EBV, the possibility of extranodal NK/T-cell lymphoma, nasal type, was excluded. NK-cell lymphoma and CD56+ myeloid leukemia have great similarity in clinical, histological and immunohistological presentations (2). However, our case had negative staining for the myeloid marker myeloperoxidase and this excluded the possibility of CD56+ myeloid leukemia.

There is no standard treatment for advanced blastic NK-cell lymphoma (3,13). Initial treatment consists of multiagent chemotherapy in the majority of patients, and most patients receive CHOP (cyclophosphamide, doxorubicin, vincristine, prednisone) or a CHOP-like regimen (2,8). Response to combination chemotherapy, such as CHOP, is minimal or transient and early progression is common (2,8). Radiation therapy is effective for localized disease only. A CHOP-like regimen and radiotherapy are inadequate therapies for this type of neoplasm. More aggressive therapies directed to allogeneic stem cell transplantation are probably superior. Young patients treated with aggressive regimens used in acute leukemia have a better prognosis than patients treated with CHOP-like regimens (16). Long-term remission of blastic NK/T-cell lymphoma was reported after autologous peripheral blood stem cell transplantation (17). Significant survival benefits were found in patients with blastic NK-cell lymphoma who underwent hematopoietic stem cell transplantation (18). Therefore, allogeneic or autologous stem cell transplantation is a promising treatment strategy and should be recommended to the patient. Rapid clearance of skin lesions represents responsiveness of blastic NK-cell lymphoma to L-asparaginase-based chemotherapy. The rationale is based on reports that L-asparaginase is effective in the treatment of NK/T-cell lymphoma (19–22). Childhood blastic NK-cell leukemia was also reportedly successfully treated with L-asparaginase (23). L-asparaginase could induce selective apoptosis of natural killer-cell tumors (24). Recently, an L-asparaginase-based regimen was reported to be a promising new salvage chemotherapeutic regimen in CHOP failures and improved treatment outcome in midline NK/T-cell lymphoma, nasal type (25).

The prognosis of blastic NK-cell lymphoma is poor, with a median survival of 14 months and 2- and 5-year overall survivals of 33% and 6%, respectively (2). Patients with only skin involvement tend to have longer survival than those with extracutaneous disease (2,8). Young age (≤ 40 years), TdT expression of $>50\%$ neoplastic cells, and cutaneous involvement

only were independent prognostic variables for a better prognosis (2,8).

In Taiwan, Lin et al reported a 35-year-old man diagnosed with blastic NK-cell lymphoma with skin and bone marrow involvement (26). He initially presented with erythematous and purpuric plaques on the face and trunk. Blastic-like lymphoid cells were found infiltrating the dermis and subcutis in a biopsy specimen. The tumor cells were immunoreactive to CD56 but not other T-cell, B-cell, or myeloid markers or EBV. The patient did not attain remission and skin lesions persisted despite four courses of CHOP. The clinical, histological and immunohistological characteristics of our present case are similar to that reported by Lin et al (26). However, our patient was younger and more responsive to the L-asparaginase-based chemotherapy.

In conclusion, we reported a rare case of blastic NK-cell lymphoma with bone marrow involvement. Accurate pathological diagnosis of this neoplasm is essential for prognosis and treatment. Although the patient responded to initial chemotherapy, hematopoietic stem cell transplantation may be needed to prolong his survival.

References

- Jacob MC, Chaperot C, Mossuz P, et al. CD4+ CD56+ lineage negative malignancies: a new entity developed from malignant early plasmacytoid dendritic cells. *Haematologica* 2003;88:941–55.
- Bekkenk MW, Jansen PM, Meijer CJ, Willemze R. CD56+ hematological neoplasms presenting in the skin: a retrospective analysis of 23 new cases and 130 cases from the literature. *Ann Oncol* 2004;15:1097–108.
- Willemze R, Jaffe ES, Burg G, et al. WHO-EORTC classification for cutaneous lymphoma. *Blood* 2005;105:3768–85.
- DiGiuseppe JA, Louie DC, Williams JE, et al. Blastic natural killer cell leukemia/lymphoma: a clinicopathologic study. *Am J Surg Pathol* 1997;21:1223–30.
- Petrella T, Comeau MR, Maynadie M, et al. "Agranular CD4+ CD56+ hematodermic neoplasm" (blastic NK-cell lymphoma) originates from a population of CD56+ precursor cells related to plasmacytoid monocytes. *Am J Surg Pathol* 2002;26:852–62.
- Petrella T, Bagot M, Willemze R, et al. Blastic NK-cell lymphoma (Angular CD4+ CD56+ hematodermic neoplasms): a review. *Am J Clin Pathol* 2005;123:662–75.
- Massone C, Chott A, Metze D, et al. Subcutaneous, blastic natural killer (NK), NK/T-cell, and other cytotoxic lymphoma of the skin. A morphologic, immunophenotypic, and molecular study of 50 patients. *Am J Surg Pathol* 2004;28:719–35.
- Suzuki R, Nakamura S, Suzumiya J. Blastic natural killer cell lymphoma/leukemia (CD56-positive blastic tumor). Prognostication and categorization according to anatomic sites of involvement. *Cancer* 2005;104:1022–31.
- Jaffe ES, Harris NL, Stein H, et al. *World Health Organization Classification of Tumors. Pathology and Genetics of*

- Tumours of Hematopoietic and Lymphoid Tissues*. Lyon, France: IARC Press, 2001.
10. Knudsen H, Grønbaek K, thor Straten P, et al. A case of lymphoblastoid natural killer (NK)-cell lymphoma: association with the NK-cell receptor complex CD94/NKG2 and TP53 intragenic deletion. *Br J Dermatol* 2002;146:148–53.
 11. Chaperot L, Bendriss N, Manches O, et al. Identification of a leukemic counterpart of the plasmacytoid dendritic cells. *Blood* 2001;97:3210–7.
 12. Feuillard J, Jacob MC, Valensi F, et al. Clinical and biologic features of CD4(+) CD56(+) malignancies. *Blood* 2002;99:1556–63.
 13. Slater DN. The new World Health Organization–European Organization for Research and Treatment of Cancer classification for cutaneous lymphomas: a practical marriage of two giants. *Br J Dermatol* 2005;153:874–80.
 14. Kazakov DV, Mentzel T, Burg G, Dummer R, Kempf W. Blastic natural killer-cell lymphoma of the skin associated with myelodysplastic syndrome or myelogenous leukemia: a coincidence or more? *Br J Dermatol* 2003;149:869–76.
 15. Herling M, Teitell MA, Shen RR, et al. TCL1 expression in plasmacytoid dendritic cells (DC2s) and the related CD4+ CD56+ blastic tumors of skin. *Blood* 2003;101:5007–9.
 16. Reimer P, Rudiger T, Kraemer D, et al. What is CD4+ CD56+ malignancy and how should it be treated? *Bone Marrow Transplant* 2003;32:637–46.
 17. Yamaguchi M, Maekawa M, Nakamura Y, Ueda M. Long-term remission of blastic natural killer-cell lymphoma after autologous peripheral blood stem-cell transplantation. *Am J Hematol* 2005;80:124–7.
 18. Suzuki R, Suzumiya J, Nakamura S, et al. Hematopoietic stem cell transplantation for natural killer-cell lineage neoplasms. *Bone Marrow Transplant* 2006;37:425–31.
 19. Nagafuji K, Fujisaki T, Arima F, Ohshima K. L-asparaginase induced durable remission of relapsed nasal NK/T-cell lymphoma after autologous peripheral blood stem cell transplantation. *Int J Hematol* 2001;74:447–50.
 20. Matsumoto Y, Nomura K, Kanda-Akano Y, et al. Successful treatment with Erwinia L-asparaginase for recurrent natural killer/T cell lymphoma. *Leuk Lymphoma* 2003;44:879–82.
 21. Yong W, Zheng W, Zhang Y, et al. L-asparaginase-based regimen in the treatment of refractory midline nasal/nasal-type T/NK-cell lymphoma. *Int J Hematol* 2003;78:163–7.
 22. Oshimi K. NK cell lymphoma. *Int J Hematol* 2002;76:118–21.
 23. Hyakuna N, Toguchi S, Higa T, et al. Childhood blastic NK cell leukemia successfully treated with L-asparaginase and allogeneic bone marrow transplantation. *Pediatr Blood Cancer* 2004;42:631–4.
 24. Ando M, Sugimoto K, Kitoh T, et al. Selective apoptosis of natural killer-cell tumor by L-asparaginase. *Br J Hematol* 2005;130:860–8.
 25. Yong W, Zheng W, Zhu J, et al. Midline NK/T-cell lymphoma nasal-type: treatment, outcome, the effect of L-asparaginase based regimen, and prognostic factors. *Hematol Oncol* 2006;24:28–32.
 26. Lin CM, Wang SH, Kuo TT, Chi CC, Ho HC, Hong HS. Blastic NK-cell leukemia/lymphoma. *Dermatol Sinica* 2003;21:408–12.