



## Case Report

## Vasopressin-Responsive ACTH-Independent Macronodular Adrenal Hyperplasia Causing Cushing's Syndrome

Yi-Yin Huang<sup>1</sup>, Hsin-Dean Chen<sup>2</sup>, Chen-Chung Fu<sup>2</sup>, Jer-Chuan Li<sup>2</sup>, Du-An Wu<sup>2\*</sup>

<sup>1</sup>Division of Endocrinology and Metabolism, Department of Internal Medicine, Buddhist Tzu Chi General Hospital, Taichung Branch, Taichung, Taiwan

<sup>2</sup>Division of Endocrinology and Metabolism, Department of Internal Medicine, Buddhist Tzu Chi General Hospital and Tzu Chi University, Hualien, Taiwan

### Article info

#### Article history:

Received: December 13, 2006

Revised: January 2, 2007

Accepted: March 13, 2007

#### Keywords:

Aberrant receptor

AIMAH

Cushing's syndrome

### Abstract

ACTH-independent macronodular adrenal hyperplasia (AIMAH) is a rare cause of endogenous Cushing's syndrome (CS). The diagnosis is suggested by bilateral adrenal nodular enlargement on conventional imaging and the demonstration of ACTH-independent hypercortisolism. Cortisol secretion in AIMAH can be regulated by the aberrant adrenal expression of receptors for gastric inhibitory polypeptide, vasopressin, catecholamines, luteinizing hormone/human chorionic gonadotropin and serotonin. We report on a 47-year-old man with CS due to AIMAH. The cortisol levels were increased after vasopressin stimulation, suggesting aberrant expression of vasopressin receptor in the adrenal glands. Total adrenalectomy is considered a standard therapy for AIMAH. (*Tzu Chi Med J* 2007;19(3):164–168)

\*Corresponding author. Division of Endocrinology and Metabolism, Department of Internal Medicine, Buddhist Tzu Chi General Hospital, 707, Section 3, Chung Yang Road, Hualien, Taiwan. E-mail address: [duanmonk@tzuchi.com.tw](mailto:duanmonk@tzuchi.com.tw)

## 1. Introduction

Endogenous Cushing's syndrome (CS) is a rare disease with an estimated incidence of 1 case per 500,000 persons (1). ACTH-independent macronodular adrenal hyperplasia (AIMAH) accounts for only 1% of CS cases (2). Hyperplasia is characterized by an increase in the size and weight of the adrenal glands due to a non-malignant increase in the number of adrenocortical cells. The regulation of cortisol secretion in patients with AIMAH can be mediated by the aberrant expression of membrane receptors for gastric inhibitory polypeptide (GIP), vasopressin, catecholamines, luteinizing hormone (LH)/human chorionic gonadotropin (hCG), and serotonin (3). We present a case of

AIMAH and demonstrate cortisol hypersecretion by vasopressin.

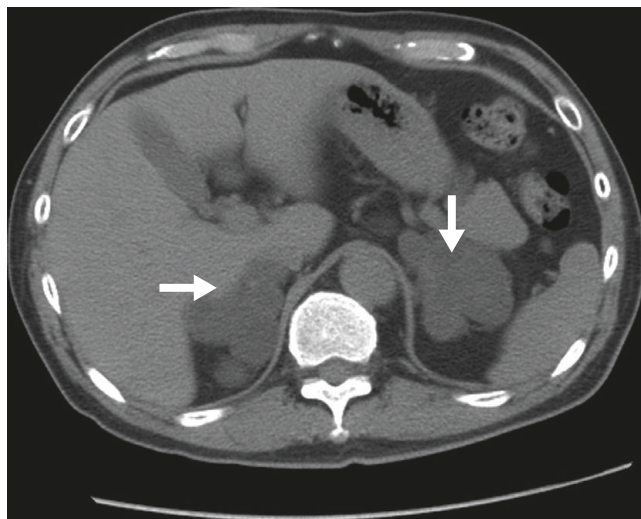
## 2. Case report

A 47-year-old man was referred to our hospital due to an incidental finding of huge bilateral adrenal masses on abdominal computed tomography scan after a traffic accident. He had hypertension for 3 years and his regular medication included atenolol and valsartan. His older sister had adrenal disease and had surgery 10 years previously. His height was 168 cm, weight was 68 kg and blood pressure was 151/98 mmHg. There were mild degrees of a moon

**Table 1 — Biochemistry data**

	Plasma cortisol ( $\mu\text{g/dL}$ )	Plasma ACTH ( $\text{pg/mL}$ )	UFC ( $\mu\text{g/d}$ )
Baseline	24.19	<10	550.5
LDDST	30.29	ND	ND
HDDST	21.92	ND	ND

UFC = urinary free cortisol, normal <100  $\mu\text{g/d}$ ; LDDST = low-dose dexamethasone suppression test, dexamethasone 0.5 mg per oral q6h for 2 days; HDDST = high-dose dexamethasone suppression test, dexamethasone 2 mg per oral q6h for 2 days; ND = no data.

**Fig. 1 — Computed tomography scan of the adrenals demonstrates bilateral adrenal macronodular masses (arrows).**

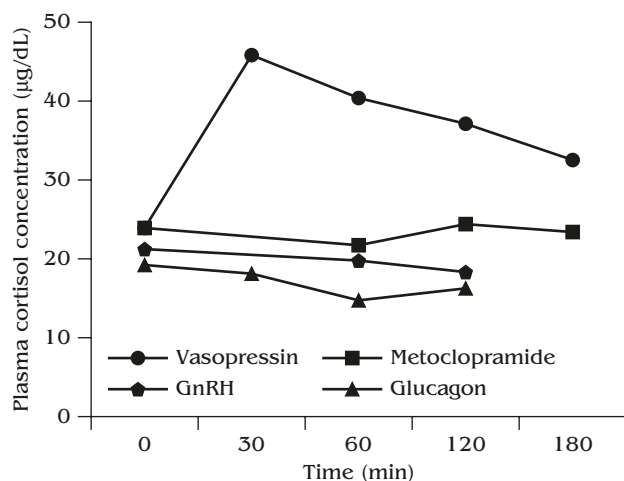
face, nuchal hump, and central obesity, but no violaceous striae, or ecchymoses. His serum potassium was 4.2 mmol/L, and sodium was 140 mmol/L. The cortisol and ACTH levels were measured by kits (ADVIA Centaur<sup>®</sup>, Bayer Diagnostics, Dublin, Ireland; Immulite<sup>®</sup>/Immulite<sup>®</sup> 1000 ACTH, Diagnostic Products Corp., Los Angeles, CA, USA). The morning baseline plasma cortisol level was 24.19  $\mu\text{g/dL}$  (reference range, 5–20  $\mu\text{g/dL}$ ), while the ACTH level was less than 10  $\text{pg/mL}$  (reference range, 10–45  $\text{pg/mL}$ ). The 24-hour urinary free cortisol (UFC) was markedly elevated to 550.8  $\mu\text{g/day}$  (reference range, 20–90  $\mu\text{g/day}$ ). Administration of both low and high doses of dexamethasone failed to suppress cortisol excretion (Table 1), establishing the diagnosis of autonomous hypercortisolism. Since abdominal computed tomography showed bilateral adrenal macronodular masses (Fig. 1), the diagnosis was consistent with CS due to ACTH-independent macronodular adrenal hyperplasia.

In order to investigate the pathophysiology of the hyperfunction of this macronodular hyperplasia, a number of stimulation tests were performed. Each test was done in the morning with the patient in a supine position after overnight fasting. After obtaining

**Table 2 — Basal and stimulated serum cortisol levels in the patient\***

Test	Cortisol ( $\mu\text{g/dL}$ )	
	Basal	After stimulus
Fasting supine-upright	24.19	25.17
Mixed meal	22.78	22.42
Vasopressin 1 mg IV	23.79	45.83
Metoclopramide 10 mg PO	24.01	24.26
GnRH 100 mg IV	21.16	19.77
Glucagon 1 mg IV	18.94	17.67

\*A change of less than 25% in plasma cortisol was defined as no response, a 25–49% change was a partial response, and a change of 50% or greater was a positive response. ACTH concentrations were less than 10  $\text{pg/mL}$  both before and after all the stimulation tests.

**Fig. 2 — Overproduction of cortisol by vasopressin stimulation. The administration of 1 mg vasopressin rapidly increased plasma cortisol concentration, but there was no response to metoclopramide, gonadotropin-releasing hormone (GnRH) or glucagon.**

baseline serum cortisol and ACTH, a stimulant was given (see below) on separate days and serum cortisol and ACTH levels were obtained every 30–60 minutes for 2–3 hours as specified by each test. There was no appreciable change in cortisol and ACTH levels after ingestion of a mixed meal, intravenous administration of 100  $\mu\text{g}$  gonadotropin-releasing hormone (GnRH) or 1 mg glucagon, or oral administration of 10 mg metoclopramide. However, after intravenous administration of 1 mg of arginine vasopressin, there was a prompt rise in serum cortisol while serum ACTH remained suppressed (Table 2 & Fig. 2).

### 3. Discussion

Cases of AIMAH are usually discovered either as an incidental radiological finding or during evaluation

of adrenal hypersecretion syndrome, as in our case. It is an extremely rare cause of CS, and only occurs in 1% of all cases of CS.

In AIMAH, the adrenal glands appear lobular. The architecture is often grossly distorted (4). The radiologic features of AIMAH are bilateral adrenal masses with nodules of soft tissue density, which are often larger than 5 cm in diameter, and usually distort and completely obscure the normal adrenal glands (5). Predominant enlargement of the unilateral adrenal gland is occasionally observed in patients with AIMAH (6,7).

This syndrome has been reported in all ages (8), but most patients present in the fifth and sixth decades of life (9,10). It appears to be equally distributed between males and females in contrast to the female predominance of pituitary/hypothalamic Cushing's disease (9). The majority of AIMAH cases occur sporadically but familial clustering with a suggestion of an autosomal dominant pattern has been reported (11). It is a benign process that has never been shown to have malignant potential (3). In cases of hypercortisolism, plasma and urine cortisol concentrations are increased but plasma ACTH is suppressed, as in our patient.

The mechanisms by which excessive cortisol is produced even in the face of suppressed ACTH were previously unknown, but it is now reasonably clear that it is likely driven by factors other than ACTH. These factors (hormones) escape cortisol-mediated negative feedback either by ectopic expression or hyperreaction to ectopically expressed membrane-bound receptors on the nodular cells and/or hyperplastic adrenal cortical cells. Hormones suspected of activating the aberrant receptors include GIP, vasopressin, catecholamines, LH and serotonergic 5-HT<sub>4</sub> receptor effectors (12).

GIP- or food-dependent CS has been found in some patients with AIMAH (13,14). The fact that cortisol production in these cases was stimulated by orally administered glucose, and lipid- or protein-enriched meals, but not by intravenously administered glucose led to the speculation that GIP or aberrant GIP receptor expression on the cell membrane is involved in the mechanism of cortisol hypersecretion. Plasma cortisol levels correlated well with plasma GIP concentrations during the various test meals. Our patient did not show a cortisol response to a mixed meal.

Vasopressin is mediated by stimulation of specific G protein-coupled receptors, classified into three subtypes, V<sub>1</sub>-vascular, V<sub>2</sub>-renal and V<sub>3</sub> (also named V<sub>1b</sub>)-pituitary vasopressin receptors (15–17). Many pituitary corticotroph adenomas have been shown to increase ACTH release after administration of lysine-vasopressin, and hence hypersecretion of cortisol (18). But in adrenal CS, plasma cortisol should not be stimulated with administration of vasopressin as long as ACTH remains suppressed from the negative

feedback mechanism. However, unexpected direct stimulation of cortisol secretion by exogenous arginine-vasopressin or lysine-vasopressin administration has been described in cases of adrenal CS (19), including unilateral adrenal adenomas, carcinomas and AIMAH. V<sub>1a</sub>-vasopressin receptor is expressed in the normal adrenal cortex and modulates modest direct effects of vasopressin on steroidogenesis (20). The exaggerated steroidogenic response to vasopressin, as in our patient, is best explained by increased activity of a "eutopic" receptor-effector system or aberrant receptor effect. Provocation tests *in vivo* indicated that arginine vasopressin promoted cortisol secretion through vasopressin V<sub>1a</sub>, V<sub>1b</sub> and V<sub>2</sub> receptors (21).

It is well known that in addition to modulating aldosterone secretion, catecholamines stimulate the hypothalamic-pituitary-adrenal axis via activation of  $\alpha$ 1-adrenoreceptors in the paraventricular nuclei leading to corticotropin-releasing hormone release and subsequent increased plasma levels of ACTH as well as cortisol (22). However, administration of  $\beta$ 1- or  $\beta$ 2-adrenergic agonists or antagonists has no effect on ACTH or cortisol secretion in the normal adrenal gland (23). Yet, ectopic expression of  $\beta$ -adrenergic receptors was reported *in vitro* in a tumor from a patient with CS (24). Furthermore, increased steroidogenesis was demonstrated by hypercatecholamines evoked by upright posture without ACTH mediation in patients with AIMAH and CS (25). In our patient, there was no evidence of catecholamine involvement in the pathogenesis of his AIMAH.

The LH receptor normally activates adenylyl cyclase and phospholipase C to stimulate steroidogenesis in the gonads (26). The receptor is mainly expressed in gonadal tissues, but it is also found in other tissues, including the uterus, fallopian tubes, placenta, brain, hypothalamus and prostate (27). The LH/hCG receptor was identified by immunohistochemistry in the zona reticularis of the human adrenal (28). Cortisol production is directly controlled by endogenous secretion of LH/hCG. The direct involvement of this aberrant LH/hCG receptor expression in the development of hyperplasia has been demonstrated (29). In our patient, administration of GnRH did not stimulate additional cortisol production.

In the normal adrenal gland, 5-HT<sub>4</sub> receptor agonists are potent stimulators of aldosterone secretion but only weakly affect cortisol secretion *in vitro*. *In vivo*, they normally do not stimulate cortisol production (30). A number of patients with adrenal CS were reported to be responsive to oral cisapride or metoclopramide (5-HT<sub>4</sub> receptor agonist) administration. The exaggerated cortisol responses in these patients could be secondary to the increased zona fasciculate expression or abnormal function of a "eutopic" 5-HT<sub>4</sub> receptor-effector system (4). When

given orally, metoclopramide did not alter the serum cortisol level in our patient.

Our hypothesis is that the ectopic or aberrant receptors in adrenal cells under stimulation by trophic factors other than ACTH (such as vasopressin) are not governed by the negative feedback effects of glucocorticoids and hence hypersecretion of cortisol occurs. Another possibility is that chronic stimulation by one of these trophic factors besides ACTH leads to hyperplasia, nodular formation and eventually autonomous hypersecretion from the adrenal cortex and the subsequent development of CS.

The treatment of choice for AIMAH is total bilateral adrenalectomy, either by the open flank or laparoscopic approach. It is the most definitive treatment, although lifetime replacement of glucocorticoids is necessary. Unilateral adrenalectomy may result in some clinical and laboratory improvement, particularly in insulin resistance and glycemic control, but persistent hypercortisolism may increase morbidity due to higher risks of atherosclerosis, hypertension, diabetes, hyperlipidemia, and obesity in affected patients (31,32).

Medical treatment of AIMAH based on the aberrant adrenal receptors theory includes administration of octreotide for GIP-dependent CS (33), propranolol for  $\beta$ -adrenergic receptors (34), and a long-acting GnRH agonist for LH-dependent CS (35). Treatment also includes a partial response to OPC-21268, a V1a-receptor antagonist for vasopressin-responsive CS (36). Ketoconazole, metyrapone and mitotane likewise have been shown to be effective in inhibiting steroidogenesis in some cases of AIMAH with CS (37–39).

We reported a case of CS due to ACTH-independent macronodular hyperplasia, an extremely rare cause of CS. After challenges with a mixed meal, metoclopramide, GnRH, glucagon and vasopressin, cortisol production increased only with vasopressin administration. We speculate that the pathophysiologic mechanism of CS in this case was due to either an ectopic vasopressin effect or hyperactivity of ectopic receptors on the tumor cells.

## References

- Ross NS. Epidemiology of Cushing's syndrome and subclinical disease. *Endocrinol Metab Clin North Am* 1994;23:539–46.
- Orth DN. Cushing's syndrome. *N Engl J Med* 1995;332:791–805.
- Stavroula C, Isabelle B, Andre L. Clinical and subclinical ACTH-independent macronodular adrenal hyperplasia and aberrant hormone receptors. *Horm Res* 2005;64:119–31.
- Lewis SBJ. *Cushing's Syndrome*. Boston: Kluwer Academic Publishers, 2002:217–22.
- Doppman JL, Chrousos GP, Papanicolaou DA, Stratakis CA, Alexander HR, Nieman LK. Adrenocorticotropic-independent macronodular adrenal hyperplasia: an uncommon cause of primary adrenal hypercortisolism. *Radiology* 2000;216:797–802.
- N'Diaye N, Hamet P, Tremblay J, et al. Asynchronous development of bilateral nodular adrenal hyperplasia in gastric inhibitory polypeptide-dependent Cushing's syndrome. *J Clin Endocrinol Metab* 1999;84:2616–22.
- Agboola-Abu CF, Garba MR, Elesha SO, Obiora AA, KuKu SF. Unilateral macronodular adrenal hyperplasia as an unusual cause of Cushing's syndrome—a case study. *West Afr J Med* 1999;18:124–9.
- Findlay JC, Sheeler LR, Engeland WC, Aron DC. Familial adrenocorticotropic-independent Cushing's syndrome with bilateral macronodular adrenal hyperplasia. *J Clin Endocrinol Metab* 1993;76:189–91.
- Malchoff CD, MacGillivray D, Malchoff DM. Adrenocorticotropic hormone-independent adrenal hyperplasia. *Endocrinology* 1996;6:79–85.
- Rolf CG. *The ACTH Axis: Pathogenesis, Diagnosis and Treatment*. Massachusetts: Kluwer Academic Publishers, 2003:201.
- Minami S, Sugihara H, Sato J, et al. ACTH independent Cushing's syndrome occurring in siblings. *Clin Endocrinol* 1996;44:483–8.
- Vincent C, Yves R, Estelle L, et al. Abnormal sensitivities of cortisol-producing adrenocortical adenomas to serotonin: *in vivo* and *in vitro* studies. *J Clin Endocrinol Metab* 2005;90:2843–50.
- Hamet P, Larochelle P, Franks DJ, Cartier P, Bolte E. Cushing's syndrome with food-dependent periodic hormonogenesis. *Clin Invest Med* 1987;10:530–3.
- Lacroix A, Bolte E, Tremblay J, et al. Gastric inhibitory polypeptide-dependent cortisol hypersecretion—a new cause of Cushing's syndrome. *N Engl J Med* 1992;327:974–80.
- Thibonnier M, Berti-Mattera LN, Dulin N, Conarty DM, Mattera R. Signal transduction pathways of the human V1-vascular, V2-renal, V3-pituitary vasopressin and oxytocin receptors. *Prog Brain Res* 1998;119:147–61.
- Barberis C, Mouillac B, Durroux T. Structural bases of vasopressin/oxytocin receptor function. *J Endocrinol* 1998;156:223–9.
- Rodrigo J, Pena A, Murat B, et al. Mapping the binding site of arginine vasopressin to V1a and V1b vasopressin receptors. *Mol Endocrinol* 2007;21:512–25.
- Raux MC, Binous M, Luton JP, Gourmelen M, Girard F. Studies of ACTH secretion control in 116 cases of Cushing's syndrome. *J Clin Endocrinol Metab* 1975;40:186–97.
- Arnaldi G, de Keyser Y, Gasc JM, Clauser E, Bertaqna X. Vasopressin receptors modulate the pharmacological phenotypes of Cushing's syndrome. *Endocr Res* 1998;24:807–16.
- Gallo-Payet N, Guillon G. Regulation of adrenocortical function by vasopressin. *Horm Metab Res* 1998;30:360–7.
- Lee S, Hwang R, Lee J, et al. Ectopic expression of vasopressin V1b and V2 receptors in the adrenal glands of familial ACTH-independent macronodular adrenal hyperplasia. *Clin Endocrinol* 2005;63:625–30.
- Grossman A. *Corticotropin-Releasing Hormone: Basic Physiology and Clinical Applications*. Philadelphia: WB Saunders Company, 1999:341–54.
- Al-Damluji S, Perry L, Tomlin S, et al. Alpha-adrenergic stimulation of corticotrophin secretion by a specific central mechanism in man. *Neuroendocrinology* 1987;45:68–76.

24. Lacroix A, N'Diaye N, Tremblay J, Hamet P. Ectopic and abnormal hormone receptors in adrenal Cushing's syndrome. *Endocr Rev* 2001;22:75-110.
25. Lacroix A, Tremblay J, Rousseau G, et al. Propranolol therapy for ectopic beta-adrenergic receptors in adrenal Cushing's syndrome. *N Engl J Med* 1997;337:1429-34.
26. Segaloff DL, Ascoli M. The lutropin/choriogonadotropin receptor... 4 years later. *Endocr Rev* 1993;14:324-47.
27. Rao CV. The beginning of a new era in reproductive biology and medicine: expression of low levels of functional luteinizing hormone/human chorionic gonadotropin receptors in nongonadal tissues. *J Physiol Pharmacol* 1996;47:41-53.
28. Pabon JE, Li X, Lei ZM, Sanfilippo JS, Yussman MA, Rao CV. Novel presence of luteinizing hormone/chorionic gonadotropin receptors in human adrenal glands. *J Clin Endocrinol Metab* 1996;81:2397-400.
29. Mazzuco TL, Chabre O, Feige JJ, Thomas M. Aberrant expression of human luteinizing hormone receptor by adrenocortical cells is sufficient to provoke both hyperplasia and Cushing's syndrome features. *J Clin Endocrinol Metab* 2006;91:196-205.
30. Cartier D, Lihmann I, Parmentier F, et al. Overexpression of serotonin<sub>4</sub> receptors in cisapride-responsive adrenocorticotropin-independent bilateral macronodular adrenal hyperplasia causing Cushing's syndrome. *J Clin Endocrinol Metab* 2003;88:248-54.
31. Lamas C, Alfaro JJ, Lucas T, Lecumberri B, Barcelo B, Estrada J. Is unilateral adrenalectomy an alternative treatment for ACTH-independent macronodular adrenal hyperplasia? Long-term follow-up of four cases. *Eur J Endocrinol* 2002;146:237-40.
32. Oqura M, Kusaka I, Naqasaka S, et al. Unilateral adrenalectomy improves insulin resistance and diabetes mellitus in a patient with ACTH-independent macronodular adrenal hyperplasia. *Endocr J* 2003;50:715-21.
33. Croughs RJ, Zelissen PM, van Vroonhoven TJ, et al. GIP-dependent adrenal Cushing's syndrome with incomplete suppression of ACTH. *Clin Endocrinol (Oxf)* 2000;52:235-40.
34. Lacroix A, Tremblay J, Rousseau G, Bouvier M, Hamet P. Propranolol therapy for ectopic beta-adrenergic receptors in adrenal Cushing's syndrome. *N Engl J Med* 1997;337:1429-34.
35. Boudeau I, D'Amour P, Hamet P, Boutin JM, Lacroix A. Aberrant membrane hormone receptors in incidentally discovered bilateral macronodular adrenal hyperplasia with subclinical Cushing's syndrome. *J Clin Endocrinol Metab* 2001;86:5534-40.
36. Daidoh H, Morita H, Hanafusa J, et al. *In vivo* and *in vitro* effects of AVP and V1a receptor antagonist on Cushing's syndrome due to ACTH-independent bilateral macronodular adrenocortical hyperplasia. *Clin Endocrinol (Oxf)* 1998;49:403-9.
37. Hocher B, Bähr V, Dorfmueller S, Oelkers W. Hypercortisolism with non-pigmented micronodular adrenal hyperplasia: transition from pituitary-dependent to adrenal-dependent Cushing's syndrome. *Acta Endocrinol (Copenh)* 1993;128:120-5.
38. Verhelst JA, Trainer PJ, Howlett TA, et al. Short and long-term responses to metyrapone in the medical management of 91 patients with Cushing's syndrome. *Clin Endocrinol* 1991;35:169-78.
39. Nagai M, Narita I, Omori K, Komura S, Arakawa M. Adrenocorticotrophic hormone independent bilateral adrenocortical macronodular hyperplasia treated with mitotane. *Intern Med* 1999;38:969-73.